

The American College of Radiology, with more than 30,000 members, is the principal organization of radiologists, radiation oncologists, and clinical medical physicists in the United States. The College is a nonprofit professional society whose primary purposes are to advance the science of radiology, improve radiologic services to the patient, study the socioeconomic aspects of the practice of radiology, and encourage continuing education for radiologists, radiation oncologists, medical physicists, and persons practicing in allied professional fields.

The American College of Radiology will periodically define new practice parameters and technical standards for radiologic practice to help advance the science of radiology and to improve the quality of service to patients throughout the United States. Existing practice parameters and technical standards will be reviewed for revision or renewal, as appropriate, on their fifth anniversary or sooner, if indicated.

Each practice parameter and technical standard, representing a policy statement by the College, has undergone a thorough consensus process in which it has been subjected to extensive review and approval. The practice parameters and technical standards recognize that the safe and effective use of diagnostic and therapeutic radiology requires specific training, skills, and techniques, as described in each document. Reproduction or modification of the published practice parameter and technical standard by those entities not providing these services is not authorized.

Revised 2013 (Resolution 17)*

ACR–ACOG–AIUM–SRU PRACTICE PARAMETER FOR THE PERFORMANCE OF OBSTETRICAL ULTRASOUND

PREAMBLE

This document is an educational tool designed to assist practitioners in providing appropriate radiologic care for patients. Practice Parameters and Technical Standards are not inflexible rules or requirements of practice and are not intended, nor should they be used, to establish a legal standard of care¹. For these reasons and those set forth below, the American College of Radiology and our collaborating medical specialty societies caution against the use of these documents in litigation in which the clinical decisions of a practitioner are called into question.

The ultimate judgment regarding the propriety of any specific procedure or course of action must be made by the physician or medical physicist in light of all the circumstances presented. Thus, an approach that differs from the practice parameters, standing alone, does not necessarily imply that the approach was below the standard of care. To the contrary, a conscientious practitioner may responsibly adopt a course of action different from that set forth in the practice parameters when, in the reasonable judgment of the practitioner, such course of action is indicated by the condition of the patient, limitations of available resources, or advances in knowledge or technology subsequent to publication of the practice parameters. However, a practitioner who employs an approach substantially different from these practice parameters is advised to document in the patient record information sufficient to explain the approach taken.

The practice of medicine involves not only the science, but also the art of dealing with the prevention, diagnosis, alleviation, and treatment of disease. The variety and complexity of human conditions make it impossible to always reach the most appropriate diagnosis or to predict with certainty a particular response to treatment. Therefore, it should be recognized that adherence to these practice parameters will not assure an accurate diagnosis or a successful outcome. All that should be expected is that the practitioner will follow a reasonable course of action based on current knowledge, available resources, and the needs of the patient to deliver effective

¹ *Iowa Medical Society and Iowa Society of Anesthesiologists v. Iowa Board of Nursing*, ___ N.W.2d ___ (Iowa 2013) Iowa Supreme Court refuses to find that the *ACR Technical Standard for Management of the Use of Radiation in Fluoroscopic Procedures* (Revised 2008) sets a national standard for who may perform fluoroscopic procedures in light of the standard's stated purpose that ACR standards are educational tools and not intended to establish a legal standard of care. See also, *Stanley v. McCarver*, 63 P.3d 1076 (Ariz. App. 2003) where in a concurring opinion the Court stated that "published standards or guidelines of specialty medical organizations are useful in determining the duty owed or the standard of care applicable in a given situation" even though ACR standards themselves do not establish the standard of care.

and safe medical care. The sole purpose of these practice parameters is to assist practitioners in achieving this objective.

I. INTRODUCTION

The clinical aspects contained in specific sections of this practice parameter (Introduction, Classification of Fetal Sonographic Examinations, Specifications of the Examination, Equipment Specifications, and Fetal Safety) were revised collaboratively by the American College of Radiology (ACR), the American Institute of Ultrasound in Medicine (AIUM), the American College of Obstetricians and Gynecologists (ACOG), and the Society of Radiologists in Ultrasound (SRU). Recommendations for physician qualifications, written request for the examination, procedure documentation, and quality control vary among the organizations and are addressed by each separately.

This practice parameter has been developed for use by practitioners performing obstetrical sonographic studies. Fetal ultrasound² should be performed only when there is a valid medical reason, and the lowest possible ultrasonic exposure settings should be used to gain the necessary diagnostic information [1,2]. A limited examination may be performed in clinical emergencies or for a limited purpose such as evaluation of fetal or embryonic cardiac activity, fetal position, or amniotic fluid volume. A limited follow-up examination may be appropriate for re-evaluation of fetal size or interval growth or to re-evaluate abnormalities previously noted if a complete prior examination is on record.

While this practice parameter describes the key elements of standard sonographic examinations in the first trimester and second and third trimesters, a more detailed anatomic examination of the fetus may be necessary in some cases, such as when an abnormality is found or suspected on the standard examination or in pregnancies at high risk for fetal anomalies. In some cases, other specialized examinations may be necessary as well.

While it is not possible to detect all structural congenital anomalies with diagnostic ultrasound, adherence to the following practice parameters will maximize the possibility of detecting many fetal abnormalities.

II. CLASSIFICATION OF FETAL SONOGRAPHIC EXAMINATIONS

A. First Trimester Ultrasound Examination

A standard obstetrical sonogram in the first trimester includes evaluation of the presence, size, location, and number of gestational sac(s). The gestational sac is examined for the presence of yolk sac and embryo/fetus. When an embryo/fetus is detected, it should be measured and cardiac activity recorded by 2D video clip or M-mode. Use of spectral Doppler is discouraged. The uterus, cervix, adnexa, and cul de sac region should be examined.

B. Standard Second or Third Trimester Examination

A standard obstetrical sonogram in the second or third trimester includes an evaluation of fetal presentation, amniotic fluid volume, cardiac activity, placental position, fetal biometry, and fetal number, plus an anatomic survey. The maternal cervix and adnexa should be examined as clinically appropriate when technically feasible.

C. Limited Examination

A limited examination is performed when a specific question requires investigation. For example, in most routine nonemergency cases a limited examination could be performed to confirm fetal heart activity in a bleeding patient, or to verify fetal presentation in a laboring patient. In most cases limited sonographic examinations are appropriate only when a prior complete examination is on record.

²The consensus of the committee was that the use of the terms “ultrasound” or “sonography” is at the discretion of each organization.

D. Specialized Examinations

A detailed anatomic examination is performed when an anomaly is suspected on the basis of history, biochemical abnormalities, or the results of either the limited or standard scan. Other specialized examinations might include fetal Doppler ultrasound, biophysical profile, fetal echocardiogram, or additional biometric measurements.

III. QUALIFICATIONS AND RESPONSIBILITIES OF PERSONNEL

Each organization addresses this requirement individually. ACR language is as follows:

See the [ACR–SPR–SRU Practice Parameter for Performing and Interpreting Diagnostic Ultrasound Examinations](#).

IV. WRITTEN REQUEST FOR THE EXAMINATION

Each organization addresses this requirement individually. ACR language is as follows:

The written or electronic request for an obstetrical ultrasound examination should provide sufficient information to demonstrate the medical necessity of the examination and allow for its proper performance and interpretation.

Documentation that satisfies medical necessity includes 1) signs and symptoms and/or 2) relevant history (including known diagnoses). Additional information regarding the specific reason for the examination or a provisional diagnosis would be helpful and may at times be needed to allow for the proper performance and interpretation of the examination.

The request for the examination must be originated by a physician or other appropriately licensed health care provider. The accompanying clinical information should be provided by a physician or other appropriately licensed health care provider familiar with the patient’s clinical problem or question and consistent with the state’s scope of practice requirements. (ACR Resolution 35, adopted in 2006)

V. SPECIFICATIONS OF THE EXAMINATION

A. First Trimester Ultrasound Examination

1. Indications

Indications for first trimester³ sonography include, but are not limited to:

- a. Confirmation of the presence of an intrauterine pregnancy [3-5].
- b. Evaluation of a suspected ectopic pregnancy [6,7].
- c. Defining the cause of vaginal bleeding.
- d. Evaluation of pelvic pain.
- e. Estimation of gestational (menstrual⁴) age.
- f. Diagnosis or evaluation of multiple gestations.
- g. Confirmation of cardiac activity.
- h. Imaging as an adjunct to chorionic villus sampling, embryo transfer, and localization and removal of an intrauterine device (IUD).
- i. Assessing for certain fetal anomalies, such as anencephaly, in high risk patients.
- j. Evaluation of maternal pelvic masses and/or uterine abnormalities.

³For the purpose of this document, first trimester represents 1w-13w + 6d.

⁴For the purpose of this document, the terms “gestational” and “menstrual” age are considered equivalent.

- k. Measuring the nuchal translucency (NT) when part of a screening program for fetal aneuploidy.
- l. Evaluation of suspected hydatidiform mole.

Comment

Limited examination may be performed to evaluate interval growth, estimate amniotic fluid volume, evaluate the cervix, and assess the presence of cardiac activity.

2. Imaging parameters

Comment

Scanning in the first trimester may be performed either transabdominally or transvaginally. If a transabdominal examination is not definitive, a transvaginal scan or transperineal scan should be performed whenever possible [8].

- a. The uterus, (including the cervix), and adnexa should be evaluated for the presence of a gestational sac. If a gestational sac is seen, its location should be documented. The gestational sac should be evaluated for the presence or absence of a yolk sac or embryo, and the crown-rump length should be recorded, when possible [9].

Comment

A definitive diagnosis of intrauterine pregnancy can be made when an intrauterine gestational sac containing a yolk sac or embryo/fetus with cardiac activity is visualized. A small, eccentric intrauterine fluid collection with an echogenic rim can be seen before the yolk sac and embryo are detectable in a very early intrauterine pregnancy. In the absence of sonographic signs of ectopic pregnancy, the fluid collection is highly likely to represent an intrauterine gestational sac. In this circumstance, the intradecidual sign may be helpful [10]. Follow-up sonography and/or serial determination of maternal serum HCG (human chorionic gonadotropin) levels are appropriate in pregnancies of undetermined location to avoid inappropriate intervention in a potentially viable early pregnancy.

The crown-rump length is a more accurate indicator of gestational (menstrual) age than is mean gestational sac diameter. However, the mean gestational sac diameter may be recorded when an embryo is not identified.

Caution should be used in making the presumptive diagnosis of a gestational sac in the absence of a definite embryo or yolk sac. Without these findings an intrauterine fluid collection could represent a pseudo-gestational sac associated with an ectopic pregnancy

- b. Presence or absence of cardiac activity should be documented with 2D video clip or M-mode.

Comment

With transvaginal scans, while cardiac motion is usually observed when the embryo is 2 mm or greater in length, if an embryo less than 7 mm in length is seen without cardiac activity, a subsequent scan in one week is recommended to ensure that the pregnancy is nonviable [4,5,11-13].

- c. Fetal number should be documented.

Comment

Amnionity and chorionicity should be documented for all multiple gestations when possible.

- d. Embryonic/fetal anatomy appropriate for the first trimester should be assessed.

- e. The nuchal region should be imaged, and abnormalities such as cystic hygroma should be documented.

Comment

For those patients desiring to assess their individual risk of fetal aneuploidy, a very specific measurement of the NT during a specific age interval is necessary (as determined by the laboratory used). See the guidelines for this measurement below.

NT measurements should be used (in conjunction with serum biochemistry) to determine the risk for having a fetus with aneuploidy or other anatomical abnormalities such as heart defects.

In this setting, it is important that the practitioner measure the NT according to established guidelines for measurement. A quality assessment program is recommended to ensure that false-positive and false-negative results are kept to a minimum [14,15]

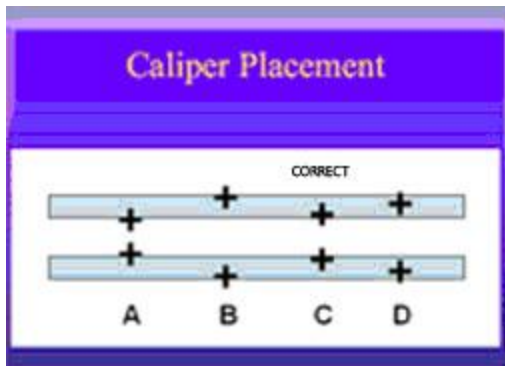
Guidelines for NT measurement:

- i. The margins of the NT edges must be clear enough for proper placement of the calipers.
- ii. The fetus must be in the midsagittal plane.
- iii. The image must be magnified so that it is filled by the fetal head, neck, and upper thorax.
- iv. The fetal neck must be in a neutral position – not flexed and not hyperextended.
- v. The amnion must be seen as separate from the NT line.
- vi. The (+) calipers on the ultrasound must be used to perform the NT measurement.
- vii. Electronic calipers must be placed on the inner borders of the nuchal line with none of the horizontal crossbar itself protruding into the space.
- viii. The calipers must be placed perpendicular to the long axis of the fetus.

The measurement must be obtained at the widest space of the NT.

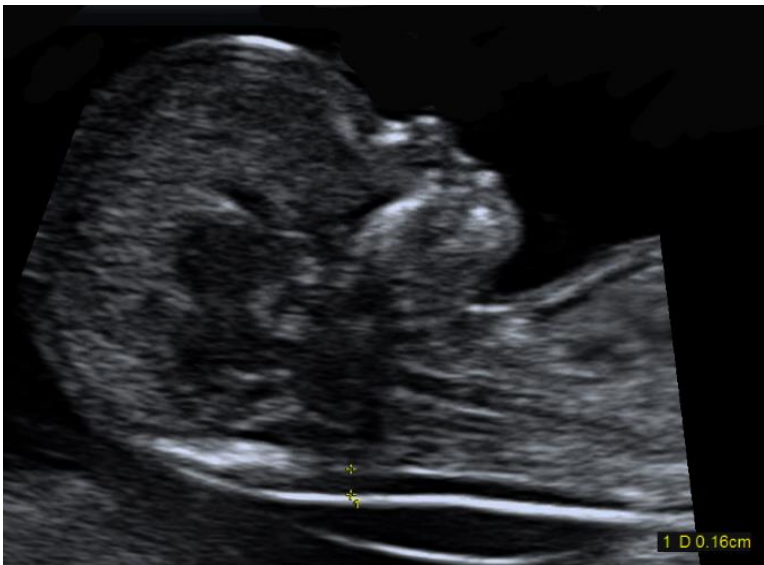

Diagram for the nuchal translucency measurement.



- f. The uterus including the cervix, adnexal structures, and cul-de-sac should be evaluated. Abnormalities should be imaged and documented.

Comment

The presence, location, appearance, and size of adnexal masses should be documented. The presence and number of leiomyomata should be documented. The measurements of the largest or any potentially clinically significant leiomyomata should be documented. The cul-de-sac should be evaluated for the presence or absence of fluid. Uterine anomalies should be documented.

B. Second and Third Trimester Ultrasound Examination [16-18]

1. Indications

Indications for second and third trimester sonography include, but are not limited to:

- a. Screening for fetal anomalies [19-22].
- b. Evaluation of fetal anatomy.
- c. Estimation of gestational (menstrual) age.
- d. Evaluation of fetal growth.
- e. Evaluation of vaginal bleeding.
- f. Evaluation of abdominal or pelvic pain.
- g. Evaluation of cervical insufficiency.
- h. Determination of fetal presentation.
- i. Evaluation of suspected multiple gestation.
- j. Adjunct to amniocentesis or other procedure.
- k. Evaluation of significant discrepancy between uterine size and clinical dates.
- l. Evaluation of pelvic mass.
- m. Evaluation of suspected hydatidiform mole.
- n. Adjunct to cervical cerclage placement.
- o. Suspected ectopic pregnancy.
- p. Suspected fetal death.
- q. Suspected uterine abnormality.
- r. Evaluation of fetal well-being.
- s. Suspected amniotic fluid abnormalities.
- t. Suspected placental abruption.
- u. Adjunct to external cephalic version.
- v. Evaluation of premature rupture of membranes and/or premature labor.
- w. Evaluation of abnormal biochemical markers.
- x. Follow-up evaluation of a fetal anomaly.
- y. Follow-up evaluation of placental location for suspected placenta previa.
- z. History of previous congenital anomaly.

- aa. Evaluation of fetal condition in late registrants for prenatal care.
- bb. Assessing for findings that may increase the risk for aneuploidy.

Comment

In certain clinical circumstances, a more detailed examination of fetal anatomy may be indicated.

2. Imaging parameters for a standard fetal examination [23]

- a. Fetal cardiac activity, fetal number, and presentation should be documented.

Comment

Abnormal heart rate and/or rhythm should be documented.

Multiple gestations require the documentation of additional information: chorionicity, amnionicity, comparison of fetal sizes, estimation of amniotic fluid volume (increased, decreased, or normal) in each gestational sac, and fetal genitalia (when visualized).

- b. A qualitative or semiquantitative estimate of amniotic fluid volume should be documented.

Comment

Although it is acceptable for experienced examiners to qualitatively estimate amniotic fluid volume, semiquantitative methods have also been described for this purpose (e.g., amniotic fluid index, single deepest pocket, two-diameter pocket) [24].

- c. The placental location, appearance, and relationship to the internal cervical os should be documented. The umbilical cord should be imaged, and the number of vessels in the cord documented. The placental cord insertion site [25] should be documented when technically possible [26-28].

Comment

It is recognized that apparent placental position early in pregnancy may not correlate well with its location at the time of delivery.

Transabdominal, transperineal, or transvaginal views may be helpful in visualizing the internal cervical os and its relationship to the placenta.

Transvaginal or transperineal ultrasound may be considered if the cervix appears shortened or cannot be adequately visualized during the transabdominal sonogram [29,30].

A velamentous (also called membranous) placental cord insertion that crosses the internal os of the cervix is vasa previa, a condition that has a high risk of fetal mortality if not diagnosed prior to labor [31-33].

- d. Gestational (menstrual) age assessment [12,13].

First-trimester crown-rump measurement is the most accurate means for sonographic dating of pregnancy. Beyond this period, a variety of sonographic parameters such as biparietal diameter, abdominal circumference, and femoral diaphysis length can be used to estimate gestational (menstrual) age. The variability of gestational (menstrual) age estimation, however, increases with advancing pregnancy. Significant discrepancies between gestational (menstrual) age and fetal measurements may suggest the possibility of fetal growth abnormality, intrauterine growth restriction, or macrosomia [34].

Comment

The pregnancy should not be redated after an accurate earlier scan has been performed and is available for comparison.

- i. Biparietal diameter is measured at the level of the thalami and cavum septi pellucidi or columns of the fornix. The cerebellar hemispheres should not be visible in this scanning plane. The measurement is taken from the outer edge of the proximal skull to the inner edge of the distal skull.

Comment

The head shape may be flattened (dolichocephaly) or rounded (brachycephaly) as a normal variant. Under these circumstances, certain variants of normal fetal head development may make measurement of the head circumference more reliable than biparietal diameter for estimating gestational (menstrual) age.

- ii. Head circumference is measured at the same level as the biparietal diameter, around the outer perimeter of the calvarium. This measurement is not affected by head shape.
- iii. Femoral diaphysis length can be reliably used after 14 weeks gestational (menstrual) age. The long axis of the femoral shaft is most accurately measured with the beam of insonation being perpendicular to the shaft, excluding the distal femoral epiphysis.
- iv. Abdominal circumference or average abdominal diameter should be determined at the skin line on a true transverse view at the level of the junction of the umbilical vein, portal sinus, and fetal stomach when visible.

Comment

Abdominal circumference or average abdominal diameter measurement is used with other biometric parameters to estimate fetal weight and may allow detection of intrauterine growth restriction or macrosomia.

- e. Fetal weight estimation

Fetal weight can be estimated by obtaining measurements such as the biparietal diameter, head circumference, abdominal circumference or average abdominal diameter, and femoral diaphysis length. Results from various prediction models can be compared to fetal weight percentiles from published nomograms [35,36].

Comment

If previous studies have been performed, appropriateness of growth should also be documented. Scans for growth evaluation can typically be performed at least 2 to 4 weeks apart. A shorter scan interval may result in confusion as to whether measurement changes are truly due to growth as opposed to variations in the technique itself [37,38].

Currently, even the best fetal weight prediction methods can yield errors as high as ± 15 percent. This variability can be influenced by factors such as the nature of the patient population, the number and types of anatomic parameters being measured, technical factors that affect the resolution of ultrasound images, and the weight range being studied.

f. Maternal anatomy

Evaluation of the uterus, adnexal structures, and cervix should be performed when appropriate. If the cervix cannot be visualized, a transperineal or transvaginal scan may be considered when evaluation of the cervix is needed [29,30].

Comment

This will allow recognition of incidental findings of potential clinical significance. The presence, location, and size of adnexal masses and the presence of at least the largest and potentially clinically significant leiomyomata should be documented. It is not always possible to image the normal maternal ovaries during the second and third trimesters.

g. Fetal anatomic survey

Fetal anatomy, as described in this document, may be adequately assessed by ultrasound after approximately 18 weeks gestational (menstrual) age. It may be possible to document normal structures before this time, although some structures can be difficult to visualize due to fetal size, position, movement, abdominal scars, and increased maternal abdominal wall thickness [39]. A second or third trimester scan may pose technical limitations for an anatomic evaluation due to imaging artifacts from acoustic shadowing. When this occurs, the report of the sonographic examination should document the nature of this technical limitation. A follow-up examination may be helpful.

The following areas of assessment represent the minimal elements of a standard examination of fetal anatomy. A more detailed fetal anatomic examination may be necessary if an abnormality or suspected abnormality is found on the standard examination.

i. Head, face, and neck

- Lateral cerebral ventricles
- Choroid plexus
- Midline falx
- Cavum septi pellucidi
- Cerebellum
- Cistern magna
- Upper lip

Comment

A measurement of the nuchal fold may be helpful during a specific age interval to assess the risk of aneuploidy [40].

ii. Chest

- Heart [41-43]
 - Four-chamber view
 - Left ventricular outflow tract
 - Right ventricular outflow tract

iii. Abdomen

- Stomach (presence, size, and situs)
- Kidneys
- Urinary bladder
- Umbilical cord insertion site into the fetal abdomen

Umbilical cord vessel number

- iv. Spine
 - Cervical, thoracic, lumbar, and sacral spine
- v. Extremities
 - Legs and arms
- vi. Gender
 - In multiple gestations and when medically indicated.

VI. DOCUMENTATION

Each organization addresses this requirement individually. ACR language is as follows:

Adequate documentation of the study is essential for high-quality patient care. There should be a permanent record of the ultrasound examination and its interpretation. Comparison with prior relevant imaging studies may prove helpful. Images of all appropriate areas, both normal and abnormal, should be recorded. Variations from normal size should generally be accompanied by measurements. Images should be labeled with the patient identification, facility identification, examination date, and image orientation. An official interpretation (final report) of the ultrasound examination should be included in the patient's medical record. Retention of the ultrasound examination images should be consistent both with clinical need and with relevant legal and local health care facility requirements [44].

Reporting should be in accordance with the [ACR Practice Parameter for Communication of Diagnostic Imaging Findings](#).

VII. EQUIPMENT SPECIFICATIONS

These studies should be conducted with real-time scanners, using a transabdominal and/or transvaginal approach. A transducer of appropriate frequency should be used. Real time sonography is necessary to confirm the presence of fetal life through observation of cardiac activity and active movement.

The choice of transducer frequency is a trade-off between beam penetration and resolution. With modern equipment, 3 to 5 MHz abdominal transducers allow sufficient penetration in most patients while providing adequate resolution. A lower-frequency transducer may be needed to provide adequate penetration for abdominal imaging in an obese patient. During early pregnancy, a 5 MHz abdominal transducer or a 5 to 10 MHz or greater vaginal transducer may provide superior resolution while still allowing adequate penetration.

VIII. FETAL SAFETY

Diagnostic ultrasound studies of the fetus are generally considered to be safe during pregnancy [45]. This diagnostic procedure should be performed only when there is a valid medical indication, and the lowest possible ultrasonic exposure setting should be used to gain the necessary diagnostic information under the "as low as reasonably achievable" (ALARA) principle [46-48].

A thermal index for soft tissue (Tis) should be used at <10 weeks gestation and a Thermal Index for bone (Tib) should be used at ≥10 week's gestation when bone ossification is evident. In keeping with ALARA principles, M-mode should be used instead of spectral Doppler to document embryonic/fetal heart rate.

The promotion, selling, or leasing of ultrasound equipment for making "keepsake fetal videos" is considered by the U.S. Food and Drug Administration to be an unapproved use of a medical device [49]. Use of a diagnostic

ultrasound system for these purposes, without a physician's order, may be in violation of state laws or regulations [49].

IX. QUALITY CONTROL AND IMPROVEMENT, SAFETY, INFECTION CONTROL, AND PATIENT EDUCATION

Each organization addresses this requirement individually. ACR language is as follows:

All probes should be cleaned after use. Vaginal probes should be covered by a protective sheath prior to insertion. Following the examination, the sheath should be disposed of and the probe cleaned in an antimicrobial solution. The type of solution and amount of time for cleaning depend on manufacturer and infectious disease recommendations.

Policies and procedures related to quality, patient education, infection control, and safety should be developed and implemented in accordance with the ACR Policy on Quality Control and Improvement, Safety, Infection Control, and Patient Education appearing under the heading *Position Statement on QC & Improvement, Safety, Infection Control, and Patient Education* on the ACR website (<http://www.acr.org/guidelines>).

Equipment performance monitoring should be in accordance with the [ACR Technical Standard for Diagnostic Medical Physics Performance Monitoring of Real Time Ultrasound Equipment](#).

ACKNOWLEDGEMENTS

This practice parameter was revised according to the process described under the heading *The Process for Developing ACR Practice Parameters and Technical Standards* on the ACR website (<http://www.acr.org/guidelines>) by the Guidelines and Standards Committee of the ACR Commission on Ultrasound in collaboration with the AIUM, the ACOG, and the SRU.

Collaborative Subcommittee - members represent their societies in the initial and final revision of this practice parameter

ACR

Marcela Bohm-Velez, MD, FACR, Chair
Dolores H. Pretorius, MD, FACR
Sheila Sheth, MD, FACR

ACOG

Jeffrey Kuller, MD
Anthony Odibo, MD
Alfred Robichaux, MD

AIUM

Jude Crino, MD
Harris J. Finberg, MD
Faith Frieden, MD

SRU

Teresita L. Angtuaco, MD, FACR
Ulrike M. Hamper, MD, MBA, FACR
Barbara S. Hertzberg, MD, FACR

Committee on Practice Parameters - Ultrasound

(ACR Committee responsible for sponsoring the draft through the process)

Beverly E. Hashimoto, MD, FACR, Chair
Sandra O. DeJesus Allison, MD
Marcela Bohm-Velez, MD, FACR
Helena Gabriel, MD
Ruth B. Goldstein, MD
Leann E. Linam, MD
Maitray D. Patel, MD
Henrietta Kotlus Rosenberg, MD, FACR, FAAP
Sheila Sheth, MD, FACR

Robert M. Sinow, MD
Maryellen R.M. Sun, MD
Sharlene A. Teefey, MD, FACR
Jason M. Wagner, MD

Deborah Levine, MD, FACR, Chair, Ultrasound Commission
Debra L. Monticciolo, MD, FACR, Chair, Quality and Safety Commission
Julie K. Timins, MD, FACR, Chair, Committee on Guidelines

Comments Reconciliation Committee

Jacqueline A. Bello, MD, FACR, Chair
Wendy D. Ellis, MD, Co-Chair
Teresita L. Angtuaco, MD, FACR
Kimberly E. Applegate, MD, MS, FACR
Marcela Bohm-Velez, MD, FACR
Jude Crino, MD
Harris J. Finberg, MD
Howard B. Fleishon, MD, MMM, FACR
Faith Frieden, MD
Ulrike M. Hamper, MD, MBA, FACR
Beverly E. Hashimoto, MD, FACR
Barbara S. Hertzberg, MD, FACR
Jeffrey Kuller, MD
Deborah Levine, MD, FACR
Debra L. Monticciolo, MD, FACR
Anthony Odibo, MD
Dolores H. Pretorius, MD, FACR
Alfred Robichaux, MD
Leslie M. Scoutt, MD, FACR
Sheila Sheth, MD, FACR
Julie K. Timins, MD, FACR

REFERENCES

1. Barnett SB, Ter Haar GR, Ziskin MC, Rott HD, Duck FA, Maeda K. International recommendations and guidelines for the safe use of diagnostic ultrasound in medicine. *Ultrasound Med Biol* 2000;26:355-366.
2. Bly S, Van den Hof MC. Obstetric ultrasound biological effects and safety. *J Obstet Gynaecol Can* 2005;27:572-580.
3. Barnhart K, van Mello NM, Bourne T, et al. Pregnancy of unknown location: a consensus statement of nomenclature, definitions, and outcome. *Fertil Steril* 2011;95:857-866.
4. Jevé Y, Rana R, Bhide A, Thangaratinam S. Accuracy of first-trimester ultrasound in the diagnosis of early embryonic demise: a systematic review. *Ultrasound Obstet Gynecol* 2011;38:489-496.
5. Thilaganathan B. The evidence base for miscarriage diagnosis: better late than never. *Ultrasound Obstet Gynecol* 2011;38:487-488.
6. Chambers SE, Muir BB, Haddad NG. Ultrasound evaluation of ectopic pregnancy including correlation with human chorionic gonadotrophin levels. *Br J Radiol* 1990;63:246-250.
7. Hill LM, Kislak S, Martin JG. Transvaginal sonographic detection of the pseudogestational sac associated with ectopic pregnancy. *Obstet Gynecol* 1990;75:986-988.
8. Kirk E, Daemen A, Papageorghiou AT, et al. Why are some ectopic pregnancies characterized as pregnancies of unknown location at the initial transvaginal ultrasound examination? *Acta Obstet Gynecol Scand* 2008;87:1150-1154.
9. Laing FC, Frates MC. Ultrasound evaluation during the first trimester of pregnancy. In: *Ultrasonography in obstetrics and gynecology*. 4th ed. Philadelphia, PA: WB Saunders; 2000:105-145.

10. Chiang G, Levine D, Swire M, McNamara A, Mehta T. The intradecidual sign: is it reliable for diagnosis of early intrauterine pregnancy? *AJR* 2004;183:725-731.
11. Abdallah Y, Daemen A, Kirk E, et al. Limitations of current definitions of miscarriage using mean gestational sac diameter and crown-rump length measurements: a multicenter observational study. *Ultrasound Obstet Gynecol* 2011;38:497-502.
12. Goldstein SR, Wolfson R. Endovaginal ultrasonographic measurement of early embryonic size as a means of assessing gestational age. *J Ultrasound Med* 1994;13:27-31.
13. Robinson HP. Sonar measurement of fetal crown-rump length as means of assessing maturity in first trimester of pregnancy. *Br Med J* 1973;4:28-31.
14. Snijders RJ, Noble P, Sebire N, Souka A, Nicolaides KH. UK multicentre project on assessment of risk of trisomy 21 by maternal age and fetal nuchal-translucency thickness at 10-14 weeks of gestation. Fetal Medicine Foundation First Trimester Screening Group. *Lancet* 1998;352:343-346.
15. Wapner R, Thom E, Simpson JL, et al. First-trimester screening for trisomies 21 and 18. *N Engl J Med* 2003;349:1405-1413.
16. Callen PW. The obstetric ultrasound examination. In: Callen PW, ed. *Ultrasonography in Obstetrics and Gynecology*. 4th ed. Philadelphia, PA: WB Saunders; 2000:1-17.
17. Garmel SH, D'Alton ME. Diagnostic ultrasound in pregnancy: an overview. *Semin Perinatol* 1994;18:117-132.
18. Seeds JW. The routine or screening obstetrical ultrasound examination. *Clin Obstet Gynecol* 1996;39:814-830.
19. ACOG Practice Bulletin No. 27: Clinical Management Guidelines for Obstetrician-Gynecologists. Prenatal diagnosis of fetal chromosomal abnormalities. *Obstet Gynecol* 2001; 97:suppl 1-12.
20. Bulas DI, Fonda JS. Prenatal evaluation of fetal anomalies. *Pediatr Clin North Am* 1997;44:537-553.
21. Malone FD, Canick JA, Ball RH, et al. First-trimester or second-trimester screening, or both, for Down's syndrome. *N Engl J Med* 2005;353:2001-2011.
22. Smith-Bindman R, Hosmer W, Feldstein VA, Deeks JJ, Goldberg JD. Second-trimester ultrasound to detect fetuses with Down syndrome: a meta-analysis. *JAMA* 2001;285:1044-1055.
23. Salomon LJ, Alfirevic Z, Berghella V, et al. Practice guidelines for performance of the routine mid-trimester fetal ultrasound scan. *Ultrasound Obstet Gynecol* 2011;37:116-126.
24. Magann EF, Sanderson M, Martin JN, Chauhan S. The amniotic fluid index, single deepest pocket, and two-diameter pocket in normal human pregnancy. *Am J Obstet Gynecol* 2000;182:1581-1588.
25. Canadian Task Force on Preventive Health Care. New grades for recommendations from the Canadian Task Force on Preventive Health Care. *CMAJ* 2003;169:207-208.
26. Harris RD, Cho C, Wells WA. Sonography of the placenta with emphasis on pathological correlation. *Semin Ultrasound CT MR* 1996;17:66-89.
27. Pretorius DH, Chau C, Poeltler DM, Mendoza A, Catanzarite VA, Hollenbach KA. Placental cord insertion visualization with prenatal ultrasonography. *J Ultrasound Med* 1996;15:585-593.
28. Sepulveda W, Rojas I, Robert JA, Schnapp C, Alcalde JL. Prenatal detection of velamentous insertion of the umbilical cord: a prospective color Doppler ultrasound study. *Ultrasound Obstet Gynecol* 2003;21:564-569.
29. Mahony BS. Ultrasound of the cervix during pregnancy. *Abdom Imaging* 1997;22:569-578.
30. Maymon R, Shulman A, Ariely S, Halperin R, Caspi E, Weinraub Z. Sonographic assessment of cervical changes during pregnancy and delivery: current concepts. *Eur J Obstet Gynecol Reprod Biol* 1996;67:149-155.
31. Lee W, Lee VL, Kirk JS, Sloan CT, Smith RS, Comstock CH. Vasa previa: prenatal diagnosis, natural evolution, and clinical outcome. *Obstet Gynecol* 2000;95:572-576.
32. Gagnon R, Morin L, Bly S, et al. Guidelines for the management of vasa previa. *J Obstet Gynaecol Can* 2009;31:748-760.
33. Oyelese Y. Placenta previa and vasa previa: time to leave the Dark Ages. *Ultrasound Obstet Gynecol* 2001;18:96-99.
34. Altman DG, Chitty LS. New charts for ultrasound dating of pregnancy. *Ultrasound Obstet Gynecol* 1997;10:174-191.

35. Hadlock FP, Harrist RB, Carpenter RJ, Deter RL, Park SK. Sonographic estimation of fetal weight. The value of femur length in addition to head and abdomen measurements. *Radiology* 1984;150:535-540.
36. Hadlock FP, Harrist RB, Sharman RS, Deter RL, Park SK. Estimation of fetal weight with the use of head, body, and femur measurements--a prospective study. *Am J Obstet Gynecol* 1985;151:333-337.
37. Deter RL, Harrist RB. Growth standards for anatomic measurements and growth rates derived from longitudinal studies of normal fetal growth. *J Clin Ultrasound* 1992;20:381-388.
38. Owen P, Donnet ML, Ogston SA, Christie AD, Howie PW, Patel NB. Standards for ultrasound fetal growth velocity. *Br J Obstet Gynaecol* 1996;103:60-69.
39. Phatak M, Ramsay J. Impact of maternal obesity on procedure of mid-trimester anomaly scan. *J Obstet Gynaecol* 2010;30:447-450.
40. Benacerraf B. The significance of the nuchal fold in the second trimester fetus. *Prenat Diagn* 2002;22:798-801.
41. International Society of Ultrasound in Obstetrics and Gynecology. Cardiac screening examination of the fetus: guidelines for performing the 'basic' and 'extended basic' cardiac scan. *Ultrasound Obstet Gynecol* 2006;27:107-113.
42. Kirk JS, Comstock CH, Lee W, Smith RS, Riggs TW, Weinhouse E. Sonographic screening to detect fetal cardiac anomalies: a 5-year experience with 111 abnormal cases. *Obstet Gynecol* 1997;89:227-232.
43. Lee W. Performance of the basic fetal cardiac ultrasound examination. *J Ultrasound Med* 1998;17:601-607.
44. Chervenak FA, Chervenak JL. Medical legal issues in obstetric ultrasound. *Clin Perinatol* 2007;34:299-308, vi.
45. Doubilet PM, Benson CB. First, do no harm... To early pregnancies. *J Ultrasound Med* 2010;29:685-689.
46. Marinac-Dabic D, Krulewitch CJ, Moore RM, Jr. The safety of prenatal ultrasound exposure in human studies. *Epidemiology* 2002; 13 Suppl 3:S19-22.
47. Miller MW, Brayman AA, Abramowicz JS. Obstetric ultrasonography: a biophysical consideration of patient safety--the "rules" have changed. *Am J Obstet Gynecol* 1998;179:241-254.
48. Sheiner E, Freeman J, Abramowicz JS. Acoustic output as measured by mechanical and thermal indices during routine obstetric ultrasound examinations. *J Ultrasound Med* 2005;24:1665-1670.
49. Food and Drug Administration. Fetal Keepsake Video. May 2011; <http://www.fda.gov/MedicalDevices/Safety/AlertsandNotices/PatientAlerts/ucm064756.htm>. Accessed June 11, 2012.

*Practice parameters and technical standards are published annually with an effective date of October 1 in the year in which amended, revised or approved by the ACR Council. For practice parameters and technical standards published before 1999, the effective date was January 1 following the year in which the practice parameter or technical standard was amended, revised, or approved by the ACR Council.

Development Chronology for this Practice Parameter

- 1990 (Resolution 5)
- Revised 1995 (Resolution 35)
- Revised 1999 (Resolution 37)
- Revised 2003 (Resolution 19)
- Amended 2006 (Resolution 35)
- Revised 2007 (Resolution 25)
- Revised 2013 (Resolution 17)
- Amended 2014 (Resolution 39)