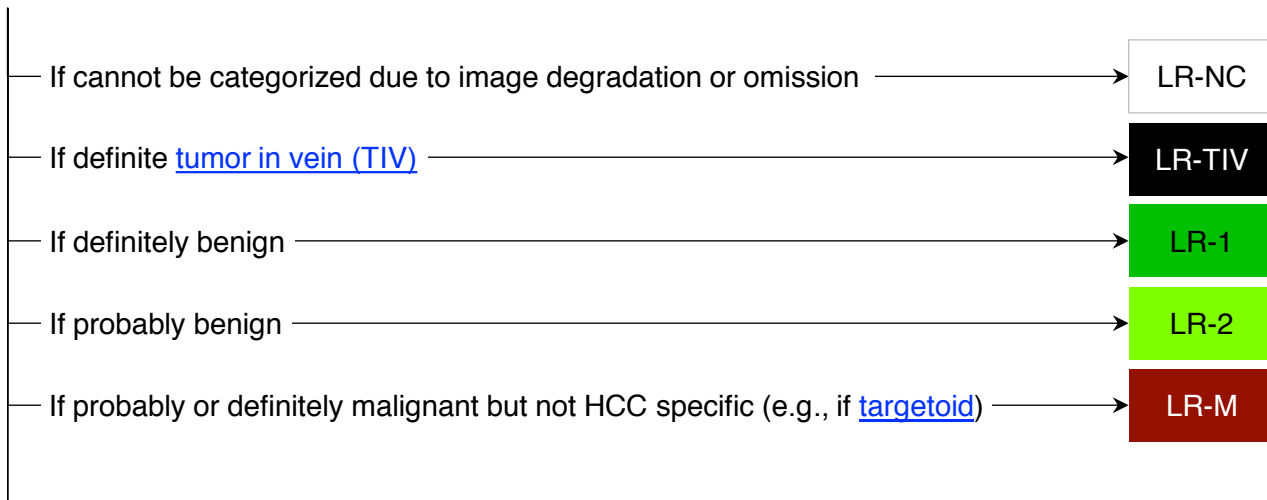





CT/MRI LI-RADS® v2017 CORE

Untreated observation without pathologic proof in [patient at high risk for HCC](#)

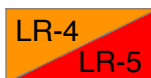

Otherwise, use CT/MRI diagnostic table below



CT/MRI Diagnostic Table

Arterial phase hyperenhancement (APHE)		No APHE		APHE (not rim)		
Observation size (mm)		< 20	≥ 20	< 10	10-19	≥ 20
Count major features: • “Washout” (not peripheral) • Enhancing “capsule” • Threshold growth	None	LR-3	LR-3	LR-3	LR-3	LR-4
	One	LR-3	LR-4	LR-4	LR-4 / LR-5	LR-5
	≥ Two	LR-4	LR-4	LR-4	LR-5	LR-5



Observations in this cell are categorized LR-4, except:

- LR-5g, if ≥ 50% diameter increase in < 6 months (equivalent to OPTN 5A-g)
- LR-5us, if “washout” and visibility at screening ultrasound (per AASLD HCC criteria)

If unsure about the presence of any major feature: characterize that feature as absent

Table of Contents

		Pages
Overview	What is LI-RADS®	<u>2</u>
	LI-RADS® v2017 Algorithms	<u>3</u>
What's New		<u>4</u>
Getting Started		<u>5</u>
Categories		<u>6</u>
Diagnosis	Step 1. Apply LI-RADS Diagnostic Algorithm	<u>7</u>
	Step 2. Consider Applying Ancillary Features	<u>8</u>
	Step 3. Apply Tiebreaking Rules if Needed	<u>9</u>
	Step 4. Final Check	<u>9</u>
Treatment Response	Step 1. Apply LI-RADS Treatment Response Algorithm	<u>10</u>
	Step 2. Measure Viable Tumor Size if Applicable	<u>11</u>
	Step 3. Apply Tiebreaking Rule if Needed	<u>11</u>
	Step 4. Final Check	<u>11</u>
Technique	LI-RADS Technical Recommendations	<u>12</u>
Management	Suggested Imaging Workup Options and Time Intervals	<u>13</u>
	OPTN and LI-RADS	<u>14</u>
Reporting	Considerations Before Issuing a LI-RADS Report	<u>15</u>
	Reporting: Requirements and Content	<u>16</u>
Definitions	Imaging Phases	<u>17</u>
	Major Imaging Features	<u>18</u>
	Tumor in Vein	<u>19</u>
	LR-M Criteria	<u>20</u>
	Ancillary Imaging Features Favoring Malignancy	<u>21</u>
	Ancillary Imaging Features Favoring Benignity	<u>22</u>
	LI-RADS Treatment Response Features	<u>23</u>
	Examples of LR-1 and LR-2 Entities	<u>24</u>
FAQs	Observation with Infiltrative Appearance	<u>25</u>
	Getting Started	<u>26</u>
	Diagnosis	<u>27</u>
	Treatment Response	<u>28</u>
	Technique	<u>29</u>
	Management	<u>30</u>
Abbreviations	Reporting	<u>31</u>
	Imaging Features	<u>32</u>
Abbreviations		<u>33</u>
CT/MRI Manual (With References) (pending)		



What is LI-RADS®?

The Liver Imaging Reporting And Data System (LI-RADS) is:

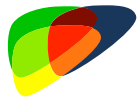- A comprehensive system for standardizing the acquisition, interpretation, reporting, and data collection of liver imaging
- A dynamic document, to be expanded and refined as knowledge accrues and in response to user feedback
- Designed to improve communication, patient care, education, and research
- Supported and endorsed by the American College of Radiology (ACR)
- Developed by a multidisciplinary, international consortium of diagnostic and interventional radiologists, hepatobiliary surgeons, hepatologists, and hepatopathologists
 - Includes academic and community physicians as well as members in training

LI-RADS may be used by:

- Community and academic radiologists
- Radiologists in training
- Other health care professionals providing care to patients with liver disease
- Researchers

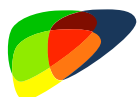

LI-RADS® v2017 Algorithms



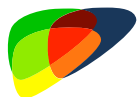Ultrasound LI-RADS® v2017

For **screening and surveillance** for HCC
Using **unenhanced ultrasound**
In **cirrhotic and other high-risk** patients
See US LI-RADS Core (pending).



CEUS LI-RADS® v2017

For **diagnosis** of HCC
Using **contrast-enhanced ultrasound (CEUS)**
In **cirrhotic and other high-risk** patients
See CEUS LI-RADS Core (pending).



CT/MRI LI-RADS® v2017

For **diagnosis and staging**
of HCC
See [page 7](#).

For **assessing treatment
response**
See [page 10](#).

Using **CT, MRI with extracellular
agents (ECA)**, or **MRI with
hepatobiliary agents (HBA)**

In **cirrhotic and other high-risk
patients**, including liver transplant
candidates with HCC

Notes:

- Multiphase CT or MRI is sometimes used for HCC surveillance, depending on regional practice guidelines, institutional preferences, and other factors. LI-RADS neither recommends for nor against use of CT or MRI for this purpose, but LI-RADS may be applied to interpret and report those exams if performed.
- Although CEUS can be used to assess treatment response, LI-RADS v2017 does not address the use of CEUS for this purpose. It will be addressed in the next LI-RADS version.



What's New in LI-RADS® v2017?

New algorithms:

- US Screening and Surveillance. See US LI-RADS Core (pending).
- CEUS Diagnosis. See CEUS LI-RADS Core (pending).
- CT/MRI Treatment Response Assessment. See [page 10](#).

New or revised categories for CT/MRI LI-RADS:

- LR-NC (new). See [page 6](#).
- LR-TIV (previously LR-5V). See [page 6](#).

Threshold growth definition modified. See [page 18](#).

New explicit criteria for LR-M. See [page 20](#).

Updated algorithmic display for CT/MRI LI-RADS. See [page 7](#).

New list-view displays to supplement algorithmic displays. See Manual (pending).

Ancillary features are now optional and their use is clarified. See [page 8](#).

New ancillary feature favoring malignancy: ultrasound visibility. See [page 21](#).

Name change for ancillary feature: distinctive rim → nonenhancing capsule. See [page 21](#).

Improved schematic diagrams, new time-intensity curves. See Manual (pending).

New FAQs. See [pages 26 \(Getting Started\)](#), [27 \(Diagnosis\)](#), [28 \(Treatment Response\)](#), [29 \(Technique\)](#), [30 \(Management\)](#), [31 \(Reporting\)](#), [32 \(Imaging Features\)](#).

Clarifies:

- Distinction between non-rim arterial phase hyperenhancement (major feature of HCC) vs. rim arterial phase hyperenhancement (feature of LR-M). See [page 18](#).
- Distinction between nonperipheral “washout” (major feature of HCC) vs. peripheral “washout” (feature of LR-M). See [page 18](#).
- Distinction between enhancing “capsule” (major feature of HCC) vs. nonenhancing “capsule” (ancillary feature favoring HCC). See [page 18](#).
- That ancillary features favoring malignancy include some favoring malignancy in general and others favoring HCC in particular. See [page 21](#).
- That CT/MRI LI-RADS can be used in liver transplant candidates with HCC. See [page 5](#).
- Categorization of tumor in vein and malignancy with infiltrative appearance. See [pages 19 & 25](#).

Why is This Update Needed?

As new evidence emerges and based on feedback from users, LI-RADS evolves to better meet clinical, educational, and research needs. LI-RADS v2017 is the next step in this evolution.



CT/MRI LI-RADS® v2017

Apply in patients at high risk for HCC, namely those with:



- Cirrhosis **OR**
- Chronic hepatitis B viral infection **OR**
- Current or prior HCC

Including adult liver transplant candidates and recipients posttransplant

Do not apply in patients:



- Without the above risk factors
- < 18 years old
- With cirrhosis due to congenital hepatic fibrosis
- With cirrhosis due to a vascular disorder such as hereditary hemorrhagic telangiectasia, Budd-Chiari syndrome, chronic portal vein occlusion, cardiac congestion, or diffuse nodular regenerative hyperplasia

Apply for multiphase exams performed with:



- CT or MRI with extracellular contrast agents (ECA) **OR**
- MRI with hepatobiliary contrast agents (HBA)

Do not assign LI-RADS categories for observations:



- That are path-proven malignancies **OR**
- That are path-proven benign lesions of non-hepatocellular origin such as hemangiomas

See [page 31](#) for guidance on reporting path-proven lesions.

CT/MRI LI-RADS® v2017 Categories

Diagnostic Categories

LR-NC	Not categorizable (due to image omission or degradation)	
LR-1	Definitely benign	
LR-2	Probably benign	
LR-3	Intermediate probability of malignancy	
Probably or definitely malignant, not necessarily HCC	LR-4	Probably HCC
	LR-5	Definitely HCC
LR-TIV	Tumor in vein	

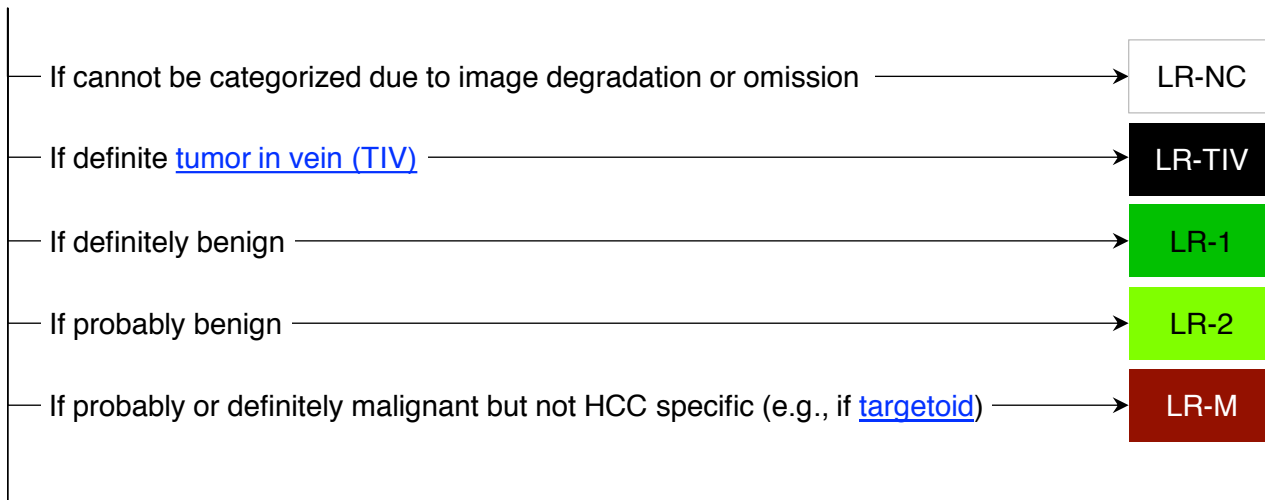
Treatment Response Categories

LR-TR Nonevaluable	Treated, Response not evaluable (due to image omission or degradation)
LR-TR Nonviable	Treated, Probably or definitely not viable
LR-TR Equivocal	Treated, Equivocally viable
LR-TR Viable	Treated, Probably or definitely viable




Step 1. Apply CT/MRI LI-RADS® Diagnostic Algorithm

Untreated observation without pathologic proof in [patient at high risk for HCC](#)

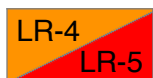

Otherwise, use CT/MRI diagnostic table below



CT/MRI Diagnostic Table

Arterial phase hyperenhancement (APHE)		No APHE		APHE (not rim)		
Observation size (mm)		< 20	≥ 20	< 10	10-19	≥ 20
Count major features: • “Washout” (not peripheral) • Enhancing “capsule” • Threshold growth	None	LR-3	LR-3	LR-3	LR-3	LR-4
	One	LR-3	LR-4	LR-4	LR-4 / LR-5	LR-5
	≥ Two	LR-4	LR-4	LR-4	LR-5	LR-5



Observations in this cell are categorized LR-4, except:

- LR-5g, if ≥ 50% diameter increase in < 6 months (equivalent to OPTN 5A-g)
- LR-5us, if “washout” and visibility at screening ultrasound (per AASLD HCC criteria)

If unsure about the presence of any major feature: characterize that feature as absent

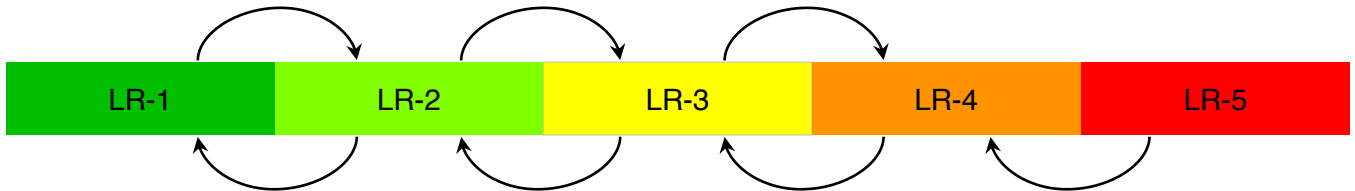


Step 2. Optional: Apply Ancillary Features (AFs)

Ancillary features may be used **at radiologist discretion** for:
Improved detection, increased confidence, or category adjustment

For **category adjustment** (upgrade or downgrade), apply ancillary features as follows:

One or more ancillary features favoring malignancy: upgrade by 1 category up to LR-4
(Absence of these ancillary features should not be used to downgrade)



One or more ancillary features favoring benignity: downgrade by 1 category
(Absence of these ancillary features should not be used to upgrade)

If there are conflicting AFs (i.e., one or more favoring malignancy and one or more favoring benignity):
Do not adjust category

Ancillary features cannot be used to upgrade to LR-5

Ancillary features favoring malignancy

Ancillary features favoring benignity

Favoring malignancy in general, not HCC in particular

- US visibility as discrete nodule
- Subthreshold growth
- Restricted diffusion
- Mild-moderate T2 hyperintensity
- Corona enhancement
- Fat sparing in solid mass
- Iron sparing in solid mass
- Transitional phase hypointensity
- Hepatobiliary phase hypointensity

- Size stability > 2 yrs
- Size reduction
- Parallels blood pool
- Undistorted vessels
- Iron in mass, more than liver
- Marked T2 hyperintensity
- Hepatobiliary phase isointensity

Favoring HCC in particular

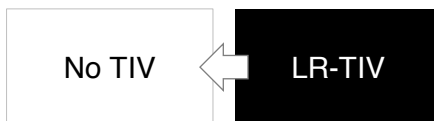
- Nonenhancing “capsule”
- Nodule-in-nodule
- Mosaic architecture
- Blood products in mass
- Fat in mass, more than adjacent liver

If unsure about presence of any ancillary feature: characterize that feature as absent

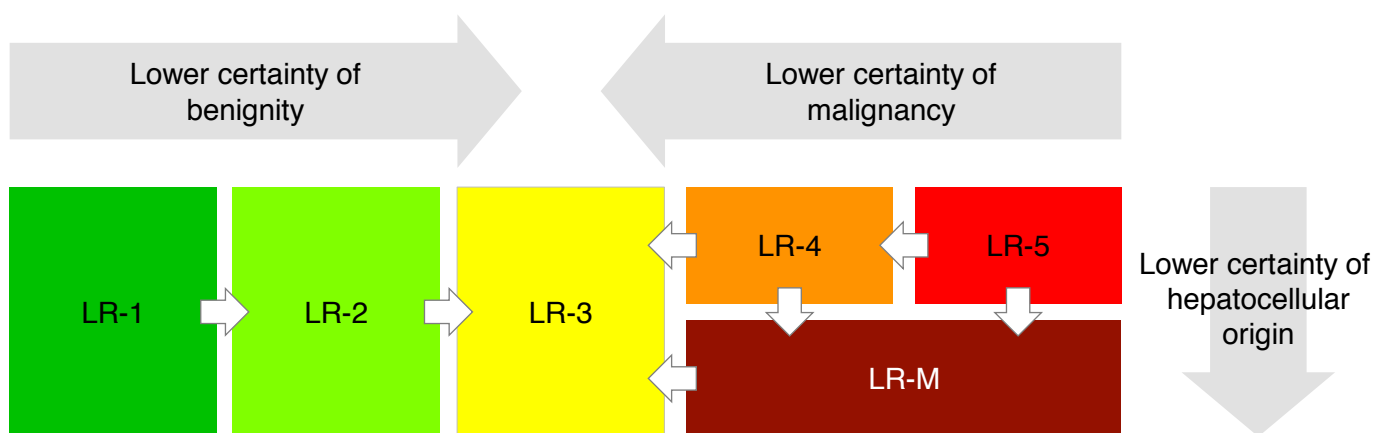


Step 3. Apply Tiebreaking Rules if Needed

If unsure about presence of TIV, do not categorize as LR-TIV



If unsure between two categories, choose the one reflecting lower certainty



Step 4. Final Check

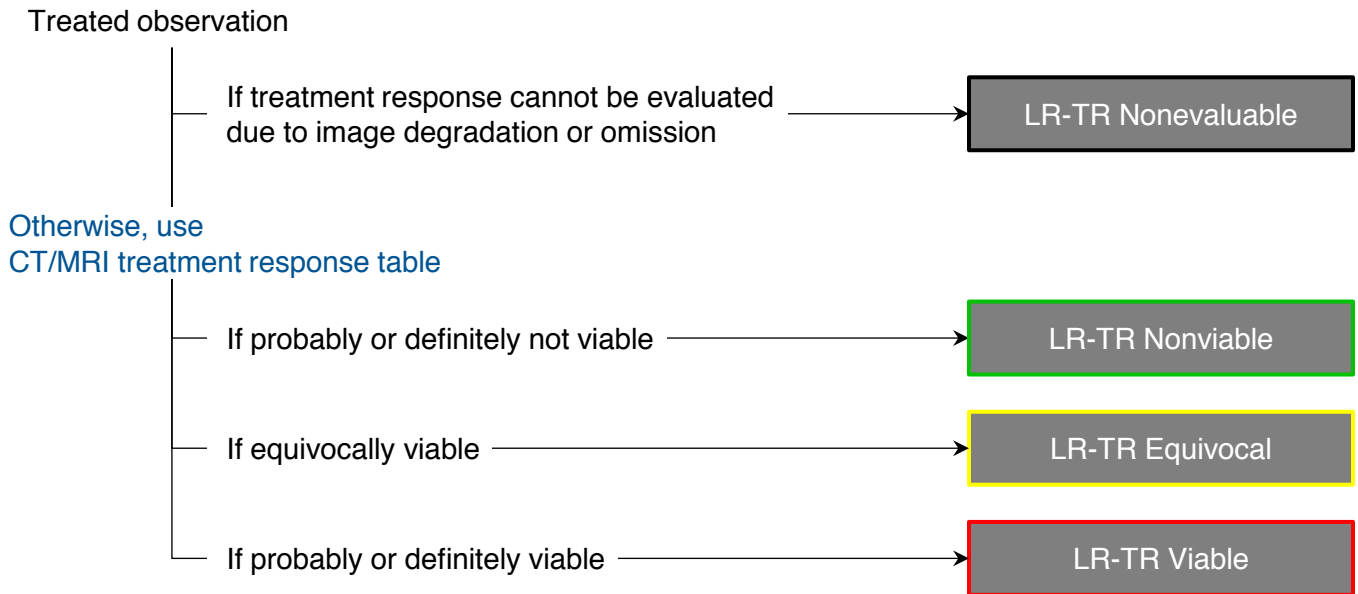
After Steps 1, 2, and 3 –

Ask yourself if the assigned category seems reasonable and appropriate

If YES: You are done, move on the next observation (if any).

If NO: Assigned LI-RADS category may be inappropriate, so reevaluate.

Step 1. Apply LI-RADS® CT/MRI Treatment Response Algorithm

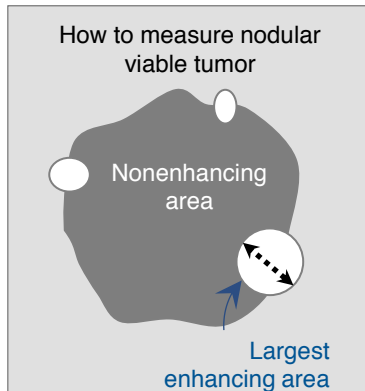
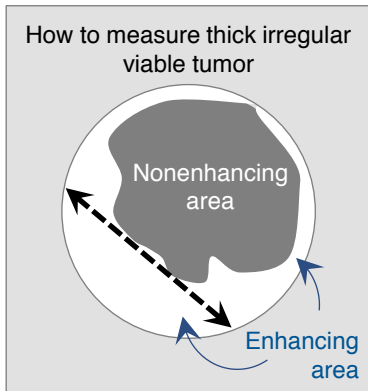


CT/MRI Treatment Response Table

Response Category	Criteria
LR-TR Nonviable	<ul style="list-style-type: none"> No lesional enhancement OR Treatment-specific expected enhancement pattern
LR-TR Equivocal	Enhancement atypical for treatment-specific expected enhancement pattern and not meeting criteria for probably or definitely viable
LR-TR Viable	Nodular, masslike, or thick irregular tissue in or along the treated lesion with any of the following: <ul style="list-style-type: none"> Arterial phase hyperenhancement OR Washout appearance OR Enhancement similar to pretreatment



Step 2. Measure Viable Tumor Size

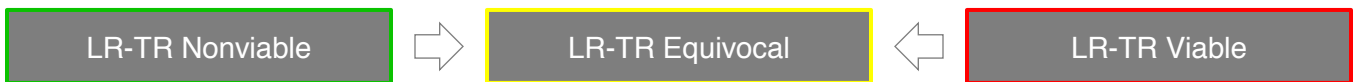


Size of equivocally, probably, or definitely viable tumor

Longest dimension through enhancing area of treated lesion, not traversing nonenhancing area

Step 3. Apply Tiebreaking Rule if Needed

If unsure between two categories, choose the one reflecting lower certainty as illustrated below



Step 4. Final Check

After Steps 1, 2, and 3 -

Ask yourself if the assigned response category seems reasonable and appropriate

If YES: You are done, move on the next observation (if any).

If NO: Assigned LI-RADS category may be inappropriate, so reevaluate.



CT/MRI LI-RADS® v2017 Technical Recommendations

CT

Recommended equipment	<ul style="list-style-type: none"> Multidetector CT with ≥ 8 detector rows
Required images	<ul style="list-style-type: none"> Arterial phase (late arterial phase strongly preferred) Portal venous phase Delayed phase
Suggested images	<ul style="list-style-type: none"> Precontrast, if patient has had locoregional treatment Multiplanar reformations

MRI with extracellular contrast agents or gadobenate dimeglumine

Recommended equipment	<ul style="list-style-type: none"> 1.5T or 3T Torso phased-array coil
Required images	<ul style="list-style-type: none"> Unenhanced T1-weighted OP and IP imaging T2-weighted imaging (fat suppression per institutional preference) Multiphase T1-weighted imaging <ul style="list-style-type: none"> Precontrast imaging Arterial phase (late arterial phase strongly preferred) Portal venous phase Delayed phase
Suggested or optional images	<ul style="list-style-type: none"> Diffusion-weighted imaging Subtraction imaging Multiplanar acquisition 1- to 3-hr hepatobiliary phase with gadobenate dimeglumine

MRI with gadoxetate disodium

Recommended equipment	<ul style="list-style-type: none"> 1.5T or 3T Torso phased-array coil
Required images	<ul style="list-style-type: none"> Unenhanced T1-weighted OP and IP imaging T2-weighted imaging (fat suppression per institutional preference) Multiphase T1-weighted imaging <ul style="list-style-type: none"> Precontrast imaging Arterial phase (late arterial phase strongly preferred) Portal venous phase Transitional phase (2 to 5 minutes after injection) Hepatobiliary phase
Suggested or optional images	<ul style="list-style-type: none"> Diffusion-weighted imaging Subtraction imaging Multiplanar acquisitions



CT/MRI LI-RADS®-Based Management: Suggested Imaging Workup Options & Time Intervals

Below are suggestions. Radiologists are encouraged to use their judgment and tailor the recommendations to each patient.

Imaging Workup Options for Untreated Observations

LI-RADS category for untreated observations	Return to routine surveillance	Alternative diagnostic imaging	Repeat diagnostic imaging
No observation	** 6 mo	* ≤ 6 mo	—
LR-NC	—	* ≤ 3 mo	** ≤ 3 mo
LR-1	** 6 mo	—	—
LR-2	** 6 mo	—	* ≤ 6 mo
LR-3	—	* 3-6 mo	** 3-6 mo
LR-4	MDD may be needed for consensus management. If neither biopsy nor treatment is planned: repeat or alternative diagnostic imaging in ≤ 3 mo.		
LR-5	Diagnosis of HCC. MDD for consensus management.		
LR-M	MDD for consensus management. May include alternative or repeat imaging, biopsy, or treatment.		
LR-TIV	MDD for consensus management. May include biopsy or biomarker correlation to determine etiology of TIV: HCC, ICC, other.		

Imaging Workup Options for Treated Observations

LI-RADS treatment response category	Continue monitoring, with same modality	Continue monitoring, with alternative imaging
LR-TR Nonevaluable	** ≤ 3 mo	* ≤ 3 mo
LR-TR Nonviable	** ≤ 3 mo	* ≤ 3 mo
LR-TR Equivocal	** ≤ 3 mo	* ≤ 3 mo
LR-TR Viable	MDD for consensus management. Often includes retreatment.	

** Preferred option in most cases. * Reasonable alternative option. — Not recommended.

Multidisciplinary discussion (MDD) can be a formal meeting or an informal communication between the radiologist and other specialist. It may be pursued in parallel with any imaging workup option above, based on clinical context or at the radiologist's discretion.



OPTN and LI-RADS®

- The OPTN system assigns HCC exception points for liver transplant candidates with HCC.
- CT/MRI LI-RADS can be applied to liver transplant candidates meeting LI-RADS eligibility criteria (See [page 5](#)).
- Basic information regarding LI-RADS and OPTN are provided below:

Imaging technique OPTN technical requirements are nearly identical to LI-RADS, except LI-RADS provides guidance for use of gadoxetate disodium.

Reporting Observations contributing to OPTN staging (i.e., LR-5, LR-5g, path-proven HCC) should be reported with the following information:

- Size or size of the viable tumor if treated
- Major features used for categorizing

Although they do not meet OPTN 5A or 5B criteria:

- LR-M and LR-TIV should be reported, as they may affect pretransplant workup and/or transplant eligibility
- LR-4 and LR-5us observations should be reported, as there is high likelihood they represent HCC, and their presence may suggest multifocal HCC

Caveats OPTN and LI-RADS definitions for threshold growth differ:

OPTN	LI-RADS
<ul style="list-style-type: none"> • $\geq 50\%$ size increase in ≤ 6 mo 	<p>Size increase of a mass by a minimum of 5 mm AND as follows:</p> <ul style="list-style-type: none"> • $\geq 50\%$ size increase in ≤ 6 mo OR • $\geq 100\%$ size increase in > 6 mo OR • Previously unseen on CT or MRI, now ≥ 10 mm, in ≤ 24 mo

Implication: Some LR-5 observations do not count as OPTN 5. In particular, for observations that depend on threshold growth for LR-5 categorization, only those with $\geq 50\%$ size increase in ≤ 6 months count as OPTN 5.

OPTN and LI-RADS populations differ:

OPTN	LI-RADS
Applies to <u>all</u> transplant candidates	Applies <u>only</u> to transplant candidates meeting eligibility criteria: (See page 5)

Implication: OPTN may be applied in some transplant candidates for whom LI-RADS is not recommended due to incomplete validation of imaging for noninvasive diagnosis of HCC. This includes pediatric patients and vascular causes of cirrhosis.



CT/MRI LI-RADS® v2017 Reporting: Considerations Before Issuing a LI-RADS® Report

Use your judgment and common sense

If a patient has multiple observations:

- Decide whether to report observations individually, in aggregate, or as a combination of both, with the goal of communicating your findings and impression most clearly.

Tailor your recommendations to your patient.

- [Page 13](#) provides general guidance for imaging workup options, but note that optimal management may vary depending on the observation or patient.

Is any observation path-proven to your knowledge?

If an observation has been biopsied and there is no uncertainty about the path diagnosis (i.e., the path diagnosis is a malignant entity such as HCC or the path diagnosis is a non-hepatocellular benign entity such as hemangioma), report the path diagnosis rather than the LI-RADS category.

If an observation has been biopsied but there is either uncertainty about the path diagnosis or the path diagnosis is a potential HCC precursor (i.e. regenerative or dysplastic nodule), report the LI-RADS category and the path diagnosis together. Rationale: reporting both may alert referrer to possible false-negative biopsy results and/or need for close follow-up to detect progression.

See [page 31](#) for further guidance.

Is there tumor in vein?

If yes, report the likely etiology. Most LR-TIV observations are HCC but some may be ICC, H-ChC, or other non-HCC malignancies. See [page 19](#) for guidance on reporting LR-TIV.

Is your patient a liver transplant candidate?

If yes, the LI-RADS category needs to be converted to OPTN Class by the radiologist or transplant team. The conversion is straightforward if the following are reported: size, major features, and number of LR-5 and LR-5g observations, and path-proven HCCs – or the viable tumor size if treated. For more advanced disease, report the presence of nodal or distant metastasis and LR-TIV observations. Also, report LR-M observations as these may affect transplant eligibility.

See Manual (pending) for detailed LI-RADS to OPTN conversion instructions.

Avoid language that compels biopsy or other invasive procedure

- If consideration for liver biopsy is appropriate, the following phrases might be used:
 - “Options for diagnostic workup include ____ and possibly biopsy.”
 - “The distinction between HCC and ____ in this patient cannot be determined with imaging alone. If distinction would be helpful for patient management, biopsy may be considered.”
 - “Biopsy may be necessary to distinguish between HCC and ____.”
 - “...probably HCC. To establish a definite diagnosis, biopsy may be considered.”



CT/MRI LI-RADS® v2017 Reporting

Untreated observation	Reporting requirement	Recommended report content
No observation	Should be reported in Impression.	“There are no reportable LI-RADS observations.”
LR-NC	Must be reported in Impression.	Provide causative technical limitations or artifacts, and work-up suggestions.
LR-1 LR-2	Summarize in aggregate OR Report in Impression if: was suspicious nodule on the antecedent ultrasound or was LR-4, -5, or -M on prior.	Provide category range and approximate number of observations. If downgrading from prior exam, provide rationale.
LR-3	Report in Impression if: no higher category observations or was LR-4, LR-5, or LR-M on prior.	Provide major features, growth, and contributory ancillary features. Indicate relevant change since prior.
LR-4 LR-5 LR-M	Must be reported in Findings and Impression. May summarize in aggregate for clarity.	Provide major features, growth, contributory ancillary & other features. Indicate relevant change since prior. For LR-5: Indicate if LR-5g or LR-5us.
LR-TIV	Must be reported in Findings and Impression.	Indicate likely etiology (HCC, non-HCC, unsure); describe vessel(s) involved.
Treated observation	Reporting requirement	Recommended report content
LR-TR Nonevaluable	Must be reported in Findings and Impression.	Provide causative technical limitations or artifacts, and work-up suggestions.
LR-TR Nonviable LR-TR Equivocal LR-TR Viable	Must be reported in Findings and Impression. May summarize in aggregate for clarity.	Provide pretreatment category and size, current response category. For TR viable or equivocal: Report viable tumor size (or range if in aggregate), criteria for viability, and change since prior.

All reported observations should include

- **Identifier:** sequential number or other unique identifier, keep fixed on all exams.
- **Location information:** series and image number on which size is measured. If possible, also save key images on PACS.

Note: if observation is a path-proven malignancy or is a benign lesion of non-hepatocellular origin, report pathology diagnosis rather than LI-RADS category. See [FAQs](#).



LI-RADS® CT/MRI Phases

Arterial phase (AP)

Early AP Late AP



In LI-RADS, the arterial phase refers to the hepatic arterial phase unless otherwise specified. The arterial phase is a postcontrast injection time range with the following characteristics:

- Hepatic artery and branches are fully enhanced.
- Hepatic veins not yet enhanced by antegrade flow.

Two subtypes:

- Early AP: Subtype of AP in which portal vein is not yet enhanced.
- Late AP: Subtype of AP in which portal vein is enhanced.

Late AP is strongly preferred for HCC diagnosis and staging, because the degree of enhancement in HCC usually is higher in the late than in the early AP. Some HCCs may show hyperenhancement only in the late AP.

Extracellular phase (ECP)

Postcontrast phase in which liver enhancement is attributable mainly to extracellular distribution of a contrast agent. Operationally, this refers to:

- PVP and DP if an extracellular agent or gadobenate is given.
- PVP only if gadoxetate is given.

Portal venous phase (PVP)



Postcontrast injection time range with the following characteristics:

- Portal veins are fully enhanced.
- Hepatic veins are enhanced by antegrade flow.
- Liver parenchyma usually is at peak enhancement.

Delayed phase (DP)



Postcontrast phase acquired with extracellular agents or gadobenate after the portal venous phase and with the following characteristics:

- Portal and hepatic veins are enhanced but less than in PVP.
- Liver parenchyma is enhanced but usually less than in PVP.

Typically acquired 2 to 5 minutes after injection.

Transitional phase (TP)



Postcontrast phase acquired with a hepatobiliary agent after the extracellular phase, before the hepatobiliary phase, and with the following characteristics:

- Liver vessels and hepatic parenchyma are of similar signal intensity.
- Both the intracellular and extracellular pools of the agent contribute substantially to parenchymal enhancement.

Typically acquired 2 to 5 minutes after injection of gadoxetate.
Typically not obtained with gadobenate.

Hepatobiliary phase (HBP)



Postcontrast phase acquired with a hepatobiliary agent where:

- Liver parenchyma is hyperintense to hepatic blood vessels.
- There is excretion of contrast into biliary system.

Typically acquired about 20 minutes after injection with gadoxetate.
Typically not obtained with gadobenate. If obtained, typically acquired 1-3 hours after injection with gadobenate.

HBP is suboptimal if liver is not more intense than hepatic blood vessels.

LI-RADS® Major Imaging Features

APHE
(not rim)



Nonrim-like enhancement in arterial phase unequivocally greater in whole or in part than liver. Enhancing part must be higher in attenuation or intensity than liver in arterial phase. *Contrast with [rim APHE](#) (inclusion criterion for LR-M, page 20).*

“Washout”
(not peripheral)



Nonperipheral visually assessed temporal reduction in enhancement in whole or in part relative to composite liver tissue from earlier to later phase resulting in hypoenhancement in the extracellular phase:

- portal venous or delayed phase if ECA or gadobenate is given
- portal venous phase if gadoxetate is given

Can apply to any enhancing observation, even if no APHE. *Contrast with [peripheral “washout”](#) (inclusion criterion for LR-M, page 20) or [TP or HBP hypointensity](#) (ancillary features favoring malignancy, page 21).*

Enhancing “capsule”



Smooth, uniform, sharp border around most or all of an observation, unequivocally thicker or more conspicuous than fibrotic tissue around background nodules, and visible as as enhancing rim in PVP, DP, or TP. *Contrast with [nonenhancing capsule](#) (ancillary feature favoring HCC, page 21) or [corona enhancement](#) (ancillary feature favoring malignancy, page 21).*

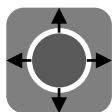
Size



Largest outer-edge-to-outer-edge dimension of an observation:

- Include “capsule” in measurement.
- Pick phase, sequence, plane in which margins are clearest.
- Do not measure in arterial phase or DWI if margins are clearly visible on different phase (size may be overestimated in arterial phase due to summation with perioobservation enhancement and is not measured reliably on DWI due to anatomic distortion).

Threshold growth



Size increase of a mass by a minimum of 5 mm AND as follows:

- $\geq 50\%$ increase in size in ≤ 6 months **OR**
- $\geq 100\%$ increase in size in > 6 months **OR**
- Previously unseen on CT or MRI, now ≥ 10 mm, in ≤ 24 months

Measure on same phase, sequence, and plane on serial exams.



Note: Apply threshold growth *only* if there is a prior CT or MRI exam of sufficient quality and appropriate technique to gauge if an observation is new or has grown. Do not assess threshold growth by comparing to prior US or CEUS exams.



LI-RADS® Tumor in Vein

Tumor in vein



Unequivocal enhancing soft tissue in vein, regardless of visualization of parenchymal mass

Additional clues to diagnosis of tumor in vein:

Imaging features that suggest tumor in vein but do NOT establish its presence are listed below:

- Occluded vein with ill-defined walls
- Occluded vein with restricted diffusion
- Occluded or obscured vein in contiguity with malignant parenchymal mass
- Heterogeneous vein enhancement not attributable to artifact

If these features are seen, scrutinize vein for enhancing soft tissue.

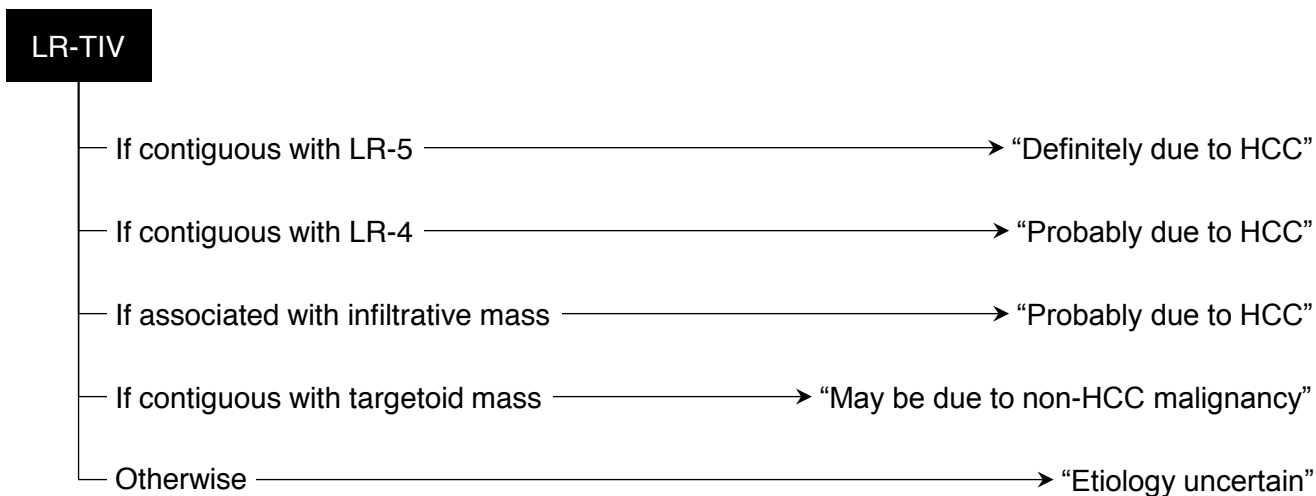
Categorization:

Categorize as LR-TIV.

Reporting:

Indicate in report most likely etiology.

See below for guidance:





LI-RADS® LR-M Criteria

Targetoid mass (see below for definition and imaging appearances)

OR

Nontargetoid mass with one or more of the following:

- Infiltrative appearance. See [page 25](#).
- Marked diffusion restriction. See manual (pending).
- Necrosis or severe ischemia. See manual (pending).
- Other feature that in radiologist’s judgment suggests non-HCC malignancy (specify in report). See manual (pending).

No tumor in vein
Not meeting LR-5 criteria

Targetoid, definition

Target-like imaging morphology. Concentric arrangement of internal components. Likely reflects peripheral hypercellularity and central stromal fibrosis or ischemia.

Characteristic of




- Cholangiocarcinoma
- Hepatocholangiocarcinoma
- Other non-HCC malignancies

Can be seen in HCC with atypical appearance.



Therefore, targetoid appearance suggests non-HCC malignancy but does not exclude HCC.

Targetoid mass, imaging appearance on various phases or sequences

Targetoid dynamic enhancement:

	Rim APHE	Spatially defined subtype of APHE in which arterial phase enhancement is most pronounced in observation periphery
	Peripheral “washout”	Spatially defined subtype of “washout” in which apparent washout is most pronounced in observation periphery
	Delayed central enhancement	Central area of progressive postarterial phase enhancement

Targetoid appearance on DWI or TP/HBP:

	Targetoid restriction	Concentric pattern on DWI characterized by restricted diffusion in observation periphery with less restricted diffusion in observation center
	Targetoid TP or HBP appearance	Concentric pattern in TP or HBP characterized by moderate-to-marked hypointensity in observation periphery with milder hypointensity in center



LI-RADS® Ancillary Imaging Features Favoring Malignancy & The Imaging Modalities in Which They Are Visible

Ancillary features favoring malignancy, not HCC in particular

Feature	Definition	CT	MRI ECA	MRI HBA
US visibility as discrete nodule	Unenhanced US visibility as discrete nodule or mass corresponding to CT- or MRI-detected observation	+	+	+
Subthreshold growth	Unequivocal size increase of a mass, less than threshold growth. See page 18 for definition of threshold growth.	+	+	+
Corona enhancement	Periobservational enhancement in late arterial phase or early PVP attributable to venous drainage from tumor	+	+	+
Fat sparing in solid mass	Relative paucity of fat in solid mass relative to steatotic liver OR in inner nodule relative to steatotic outer nodule	+ / -	+	+
Restricted diffusion	Intensity on DWI, not attributable solely to T2 shine-through, unequivocally higher than liver and/or ADC unequivocally lower than liver	-	+	+
Mild-moderate T2 hyperintensity	Intensity on T2WI mildly or moderately higher than liver and similar to or less than non-iron-overloaded spleen	-	+	+
Iron sparing in solid mass	Paucity of iron in solid mass relative to iron-overloaded liver OR in inner nodule relative to siderotic outer nodule	-	+	+
Transitional phase hypointensity	Intensity in the transitional phase unequivocally less, in whole or in part, than liver	-	-	+
Hepatobiliary phase hypointensity	Intensity in the hepatobiliary phase unequivocally less, in whole or in part, than liver	-	-	+

Ancillary features favoring HCC in particular

Feature	Definition	CT	MRI ECA	MRI HBA
Nonenhancing “capsule”	Capsule appearance not visible as an enhancing rim. See page 18 for definition of enhancing “capsule”.	+	+	+
Nodule-in-nodule architecture	Presence of smaller inner nodule within and having different imaging features than larger outer nodule	+	+	+
Mosaic architecture	Presence of randomly distributed internal nodules or compartments, usually with different imaging features	+	+	+
Fat in mass, more than adjacent liver	Excess fat within a mass, in whole or in part, relative to adjacent liver	+ / -	+	+
Blood products in mass	Intralesional or perilesional hemorrhage in the absence of biopsy, trauma or intervention	+ / -	+	+

+ usually evaluable - not evaluable + / - may or may not be evaluable

ADC = apparent diffusion coefficient, DWI = diffusion-weighted imaging, ECA = extracellular agent, HBA = hepatobiliary agent, PVP = portal venous phase, T2WI = T2-weighted imaging



LI-RADS® Ancillary Imaging Features Favoring Benignity & The Imaging Modalities in Which They Are Visible

Ancillary features favoring benignity

Feature	Definition	CT	MRI ECA	MRI HBA
Size stability ≥ 2 years	No significant change in observation size measured on exams ≥ 2 years apart in absence of treatment	+	+	+
Size reduction	Unequivocal spontaneous decrease in size over time, not attributable to artifact, measurement error, technique differences, or resorption of blood products	+	+	+
Parallels blood pool enhancement	Temporal pattern in which enhancement eventually reaches and then matches that of blood pool	+	+	+
Undistorted vessels	Vessels traversing an observation without displacement, deformation, or other alteration	+	+	+
Iron in mass, more than liver	Excess iron in a mass relative to background liver	+ / -	+	+
Marked T2 hyperintensity	Intensity on T2WI markedly higher than liver and similar to bile ducts and other fluid-filled structures	-	+	+
Hepatobiliary phase isointensity	Intensity in hepatobiliary phase nearly identical to liver	-	-	+

+ usually evaluable - not evaluable + / - may or may not be evaluable

ECA = extracellular agent, HBA = hepatobiliary agent, T2WI = T2-weighted imaging



LI-RADS® Treatment Response Features

Viability

Presence of live tumor cells within or along the margin of a treated lesion.

Radiologic viability is not synonymous with pathologic viability as imaging is not sensitive to microscopic or small foci of residual tumor.

Treatment-specific expected enhancement



Expected temporal and spatial pattern of posttreatment enhancement attributable to treatment-related changes in parenchymal perfusion.

For some treatments, early posttreatment enhancement patterns may not reliably differentiate viable from nonviable tumor. In the early postprocedural period for such treatments, the most appropriate response category may be LR-TR Equivocal.

No lesional enhancement



Absence of enhancement within or along the margin of a treated lesion.

Posttreatment APHE



Nodular, masslike, or thick and irregular APHE contained within or along the margin of a treated lesion suggests posttreatment tumor viability.

Posttreatment "washout"



Nodular, masslike, or thick and irregular washout appearance contained within or along the margin of a treated lesion suggests posttreatment tumor viability.

Posttreatment enhancement similar to pretreatment



Nodular, masslike, or thick and irregular enhancement similar to pretreatment enhancement in all postcontrast phases contained within or along the margin of a treated lesion suggests posttreatment tumor viability, even in the absence of APHE or washout appearance.



Examples of LR-1 and LR-2 Entities

LR-1

Definite:

- Cyst
- Hemangioma
- Perfusion alteration (e.g., arteriportal shunt)
- Hepatic fat deposition/sparing
- Hypertrophic pseudomass
- Confluent fibrosis or focal scar

Spontaneous disappearance

List above not meant to be exhaustive

LR-2

Probable:

- Cyst
- Hemangioma
- Perfusion alteration (e.g., arteriportal shunt)
- Hepatic fat deposition/sparing
- Hypertrophic pseudomass
- Confluent fibrosis or focal scar

Distinctive nodule without malignant imaging features (see below)

List above not meant to be exhaustive

Solid nodule < 20 mm distinctive in imaging appearance compared to background nodules **AND** with no major feature of HCC, no feature of LR-M, and no ancillary feature of malignancy.

Distinctive nodule without malignant features

Common examples:

- T1 hyperintense
- T2 hypointense
- Siderotic
- HBP hyperintense
- Any combination of above

No APHE, WO, capsule, or growth
No feature of LR-M (see [page 20](#))
No ancillary feature of malignancy (see [page 21](#))

If ≥ 20 mm, categorize as LR-3



Caution: Nodules with features suggestive of focal nodular hyperplasia (FNH) or hepatocellular adenoma (HCA) usually should be categorized LR-3. With caution, they may be categorized LR-2. They should not be categorized LR-1.

Rationale: these are diagnoses of exclusion in high-risk patients.



Observation with Infiltrative Appearance



Observation with infiltrative appearance

Observation with non-circumscribed margin (indistinct transition) thought to represent malignancy with permeative growth pattern.

Terminology:

- Malignancies with permeative growth pattern are frequently termed “infiltrative”.
- LI-RADS prefers the term infiltrative appearance. Rationale: may represent true infiltration of tumor cells into liver parenchyma, confluence of tiny nodules, or both. The distinction is difficult.

Differential diagnosis for malignancies with infiltrative CT and MRI appearance:

- Common: HCC
- Uncommon: ICC, H-ChC, metastasis to liver from extrahepatic primary, lymphoma

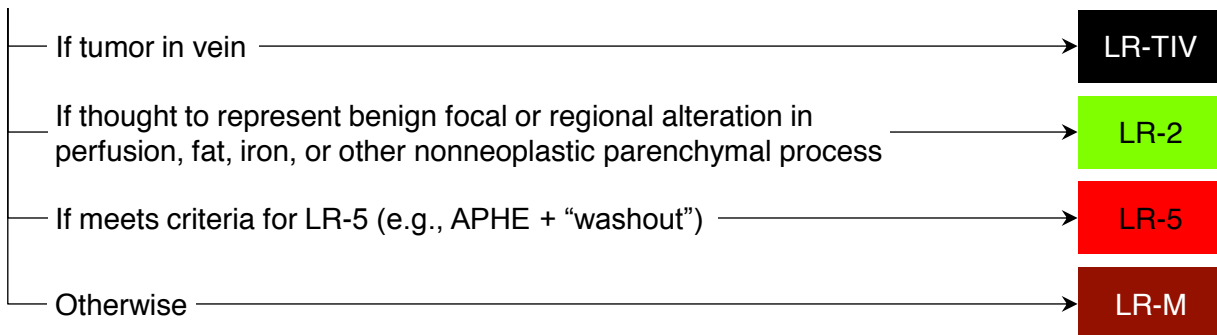
CT and MRI detection of malignancies with infiltrative appearance:

- May manifest as diffuse ill-defined mass, often involving more than one segment
- Despite large size, may be difficult to detect
 - Pre-contrast imaging may help.
 - Careful analysis of all available images frequently is necessary.
- Suggestive features (partial list):
 - Tumor in vein (often first and most helpful clue)
 - Obscured or non-visualized veins not attributable to chronic benign occlusion
 - Heterogeneous attenuation/signal intensity
 - Mild-to-moderate T1 hypointensity, T2 hyperintensity, restricted diffusion
 - Heterogeneous enhancement in one or more phases
 - Presence of multiple vague or ill-defined nodules
 - Architectural distortion

Pitfall: Some benign processes may have infiltrative appearances and be misinterpreted as malignant. Examples: focal or regional alteration in perfusion, fat deposition, iron deposition. Clue: these do not invade veins, obscure vessels, or distort parenchymal architecture.

LI-RADS categorization of ill-defined observations:

Ill-defined observation without pathologic proof in patient at high risk for HCC





Getting Started

What is a LI-RADS observation?

An observation is a distinctive area compared to background liver at imaging. It may be a lesion (mass or nodule) or pseudolesion (e.g., perfusion alteration, hypertrophic pseudomass, or artifact).

Why does LI-RADS not apply to patients without risk factors, to patients < 18 years old, or to patients with cirrhosis due to congenital hepatic fibrosis?

The positive predictive value of imaging for HCC may not be sufficiently high in such patients.

Why does LI-RADS not apply to patients with cirrhosis due to a vascular disorder such as hereditary hemorrhagic telangiectasia, Budd-Chiari syndrome, chronic portal vein occlusion, cardiac congestion, or diffuse nodular regenerative hyperplasia?

Such conditions are associated with formation of benign hyperplastic nodules that may resemble HCC on imaging, potentially causing false positive diagnoses.

I am not sure if my patient has cirrhosis. Can I apply CT/MRI LI-RADS?

You can apply LI-RADS and provide a conditional category. For example: “25 mm mass with APHE and washout appearance. If the patient has cirrhosis or chronic hepatitis B, this meets criteria for LR-5 (definitely HCC).”

My institution is a transplant center and is required to use the OPTN system. Can I use LI-RADS instead of or in addition to OPTN?

Yes, you may use LI-RADS in any patient with cirrhosis, chronic hepatitis B, or current or prior HCC. This includes liver transplant candidates and/or recipients with any of those risk factors.

My patient has active extrahepatic primary malignancy. Can I use LI-RADS?

Yes. LI-RADS may be applied, but assignment of LR-5 should be done with caution because LI-RADS imaging criteria and observation categories were not developed or validated in this setting. Concurrent extrahepatic malignancy reduces the positive predictive value of LR-5 for HCC, especially if the primary tumor is hypervascular. If in doubt, categorize as LR-M rather than LR-5; consider additional imaging and multidisciplinary discussion.

Why does LI-RADS not apply to single-phase CT or MRI exams?

Characterization of all LI-RADS major imaging features is possible only if multiple imaging phases are acquired. See [page 12](#) for LI-RADS technical recommendations.

How do I interpret and report observations on single-phase CT or MRI in at-risk patients?

Provide your best diagnosis or differential diagnosis. Suggest multiphase CT or MRI if a formal LI-RADS categorization would help in patient management.

Why shouldn't I assign a LI-RADS category for path-proven malignancies and for path-proven benign lesions of non-hepatocellular origin?

LI-RADS is intended to clarify communication. Assigning a LI-RADS category to a pathologically proven lesion (in which there is now certainty about the diagnosis) may cause confusion, especially for LI-RADS categories that convey some uncertainty (i.e., LR-2, LR-3, LR-4, or LR-M).

Should I assign a LI-RADS category to path-proven benign lesions of hepatocellular origin (e.g., regenerative or dysplastic nodules)?

These are exceptions to the prior rule. For path-proven regenerative or dysplastic nodules, assign a LI-RADS category in addition to the path diagnosis. Assigning LI-RADS categories alleviates potential harm from false-negative pathology, facilitates monitoring of nodules for possible progression, and informs management decisions.



Diagnosis

How do I determine if an observation is noncategorizable (LR-NC)?

An observation is considered noncategorizable if it cannot be categorized meaningfully because key phases were omitted or degraded, preventing assessment of one or more major features. As a direct result, reasonable categories range from those in which cancer is unlikely (LR-1 or LR-2) to those in which cancer is likely (LR-4, LR-5, LR-M). Do not assign LR-NC if categorization is challenged only by unusual imaging features or by inability to characterize ancillary features.

How do I categorize observations as LR-1 or LR-2?

Use your knowledge and experience to categorize observations as definitely benign (100% certainty of benignity) or probably benign (confident but not 100% certain). See [page 24](#) & Manual (pending).

What is the difference between LR-5 and LR-M? Does LR-M exclude HCC?

LR-5 indicates 100% certainty of HCC. LR-M indicates high certainty of malignancy but the features are not specific for HCC. LR-M does not exclude HCC. The differential diagnosis for LR-M includes HCC with nonspecific imaging features in addition to cholangiocarcinoma and other malignancies.

How do I categorize a tumor in vein?

LR-TIV, regardless of etiology. See [page 19](#) for guidance on reporting.

How do I categorize a mass with infiltrative appearance not meeting LR-TIV or LR-5 criteria?

LR-M. The features suggest malignancy but are not diagnostic of HCC. See [page 20](#).

Why doesn't LI-RADS have a category for path-proven HCC analogous to BI-RADS 6?

Biopsy plays a less important role in the workup and management of HCC in at-risk patients than it does in breast cancer. Nevertheless, such a category may be useful in some situations and a Path category is planned for the next LI-RADS major update in 2020 or 2021.

Why can't ancillary features be used to upgrade to LR-5?

Ancillary features increase diagnostic confidence and modify the probability of malignancy. The features do not have sufficient specificity for HCC to allow upgrading to LR-5, however.

Why did LI-RADS make ancillary features optional in v2017?

This was done to encourage more radiologists to adopt LI-RADS by reducing its complexity. As new users become familiar with LI-RADS, they can use ancillary features to further improve their practice.

Why did LI-RADS change LR-5V to LR-TIV?

Since non-HCC malignancies (e.g., ICC, H-ChC) can cause tumor in vein, categorizing all observations with tumor in vein as LR-5V (i.e., definitely HCC with tumor in vein) is incorrect.

Why does the tiebreaking rule choose the category reflecting lower certainty?

This maintains 100% certainty for LR-5 and LR-1. For example, if there is doubt about whether an observation is definitely or probably benign, then it cannot be considered definitely benign. The rule also helps achieve 100% positive predictive value of LR-5 for HCC. If there is uncertainty between LR-5 and LR-4 or between LR-5 and LR-M, the tiebreaking rule selects LR-4 or LR-M, respectively.

What should I do if some ancillary features favor benignity and others favor malignancy?

Do not change category (see [page 8](#)).

Does a category of LR-3 or LR-4 exclude non-HCC malignancy?

No. LR-3 and LR-4 criteria are not specific for hepatocellular origin and so do not exclude non-HCC malignancy. Thus, a small minority of LR-3 or LR-4 observations may be non-HCC malignancies.



Treatment Response

What is a treated observation?

An observation that has been treated by locoregional therapies such as radiofrequency ablation, percutaneous ethanol ablation, cryoablation, microwave ablation, transarterial embolization or chemoembolization, doxorubicin-eluting bead chemoembolization, transarterial radioembolization, and external beam radiotherapy. See Manual (pending).

What about observations treated by systemic therapy?

LI-RADS v2017 does not address systemic treatment response assessment.

How do I determine if a treated observation is nonevaluable?

A category of LR-TR Nonevaluable should be assigned if treatment response cannot be meaningfully evaluated due to inappropriate imaging technique or inadequate imaging quality. Do not assign a response category of nonevaluable if image quality is adequate, even if imaging features are difficult to characterize or interpret. See Manual (pending).

What if the arterial phase is inadequate but the portal venous phase shows unequivocal enhancement? Is that Nonevaluable or Equivocal?

Assign a response category of LR-TR Equivocal. Consider immediate repeat imaging or, if needed to ensure an adequate arterial phase, alternative imaging.

What is the optimal follow-up interval to assess treatment response?

Optimal follow-up intervals depend on the treatment, institutional guidelines, and reimbursement constraints. In general, follow-up CT or MRI is recommended every 3 months, although initial imaging at 1 month may help after certain treatments. See [page 13](#).

Are there any pitfalls in assessing response too soon after treatment?

Treatment-related changes in parenchymal perfusion may resemble or obscure tumor enhancement, potentially leading to false positive or false negative assessment of viability.

What should I do if I am unsure about tumor viability versus posttreatment change?

Categorize as LR-TR Equivocal if image quality is adequate. See [page 10](#).

Does LR-TR nonviable exclude microscopic viability?

No. LR-TR nonviable means there is no evidence of gross viable tumor, but small foci of live tumor cells cannot be excluded by noninvasive imaging.

How do I distinguish residual tumor from new tumor adjacent to a treated observation?

In contrast to new tumor in adjacent liver, residual tumor usually arises within or at the margin of the treated observation. No single threshold distance from the margin reliably distinguishes a new lesion from a marginal recurrence. Use your judgment to make the distinction and apply the corresponding LI-RADS algorithm (CT/MRI Treatment Response or Diagnostic). Example: a new observation has features indicating de novo origin (e.g., nodule in nodule) and/or excluding metastasis from the treated lesion (e.g., differences in fat, iron, HBP intensity): this should be considered a new tumor.

How do I assess the response of tumor in vein to treatment?

This can be challenging. Apply the LI-RADS treatment response criteria as best you can.

Do I need to assess response of each observation if the number of observations is large?

If there are a large number of treated observations with similar posttreatment imaging features and likely representing similar response, you may assess treatment response in aggregate.



Technique

What modality and contrast agent type does LI-RADS recommend for diagnosis or staging?

LI-RADS provides guidance on proper imaging technique for each modality (CT, MRI) and agent (ECA, HBA) but does not recommend any particular modality or agent. The choice of modality and agent depends on patient preference, tolerance, and safety; numerous factors that may affect image quality or exam feasibility; prior imaging modality and agent; and institutional and radiologist expertise. Radiologists are encouraged to tailor the modality and agent to the individual patient.

What about for monitoring treatment response?

Although treatment response may be monitored with CT or MRI and with any contrast agent:

- MRI may be preferable to CT after iodized oil-TACE because high-density oil within an embolized tumor may obscure residual or recurrent tumoral enhancement
- MRI with an extracellular agent may be preferable to MRI with gadoxetate, which is prone to arterial phase motion artifacts. In patients in which detection of new lesions is considered more important than assessing response of treated lesions, gadoxetate-MRI may be appropriate.

Radiologists should tailor the modality and agent to the individual patient and applied treatment.

Can I use LI-RADS for interpretation and reporting if recommended images are omitted?

Yes. A specific LI-RADS category often can be assigned even if recommended images are omitted. For example, an exam with only arterial and delayed phase images would allow confident LR-5 categorization if those images depicted a mass with APHE, “washout”, and “capsule”.

Are LI-RADS technical recommendations for CT and MRI consistent with OPTN?

Yes. See [page 14](#) for brief review of OPTN & LI-RADS. See Manual (pending) for detailed review.

Why does LI-RADS use “transitional phase” rather than “delayed phase” for gadoxetate?

For gadoxetate-enhanced MRI, the period from 2-5 minutes postinjection represents a transition from extracellular-dominant (i.e., portal venous phase) to intracellular-dominant (i.e., hepatobiliary phase) enhancement, and so is termed the “transitional phase”. During this period, both the intracellular and the extracellular pools of gadoxetate contribute substantially to parenchymal enhancement. This is fundamentally different from the conventional delayed phase using other agents, where enhancement reflects extracellular distribution of contrast material.

Why is the late arterial phase strongly preferred? And what is the optimal scan delay?

Late arterial phase is strongly preferred, because HCC enhancement is usually higher in the late than in the early arterial phase and some HCCs show enhancement only in the late arterial phase. The optimal delay depends on the modality (CT/MRI); type, volume and concentration of contrast agent; rate of contrast injection; timing method (fixed/bolus tracking/timing run); and number and time to K-space center of arterial phases (for MRI). See Manual (pending).

How do I gauge if liver enhancement is adequate during the hepatobiliary phase (HBP)?

Liver enhancement during the HBP is adequate if the parenchyma is unequivocally hyperintense relative to hepatic blood vessels. It is suboptimal otherwise. The mechanism for suboptimal HBP enhancement is not well understood but probably reflects reduced number of functional hepatocytes or dysfunctional cellular transport mechanisms. Pitfall: visible excretion of gadoxetate into bile duct does not indicate adequate liver enhancement. See Manual (pending).

If HBP is suboptimal, should I delay the acquisition or increase the flip angle?

Delaying the HBP acquisition may improve image quality in cirrhotic livers with diminished function, but has unknown impact on diagnostic accuracy. Increasing the flip angle improves lesion-to-liver contrast-to-noise ratio for metastases in normal livers, but has unknown impact on image quality and diagnostic accuracy in cirrhotic livers with diminished function.



Management

LI-RADS indicates that it may be appropriate to recommend alternative diagnostic imaging in ≤ 6 months if there is no observation. Can you explain the rationale?

In most cases in which no observation is detected at multiphase CT or MRI, return to routine surveillance in 6 months suffices. However, there may be cases where the antecedent screening test is so strongly positive (e.g., a definite solid nodule on ultrasound or a markedly elevated AFP) that alternative imaging may be needed to exclude a false negative result on the initial CT or MRI. In such cases, use your judgment for recommending the appropriate alternative imaging exam and time interval. If available at your institution, CEUS may be particularly helpful in cases in which screening ultrasound detected a solid nodule that was not identified at follow-up diagnostic multiphase CT or MRI.

Does optimal patient management derive directly from the LI-RADS category?

No, optimal management is determined by a combination of the LI-RADS category and a clinical assessment that integrates patient preferences, co-morbidities, hepatic disease burden, eligibility for liver transplantation, socioeconomic and health insurance status, and appointment availability. Since radiologists may not know all relevant factors, multidisciplinary discussion for consensus-based management may be helpful in difficult cases.

If I think that biopsy will be needed to establish a diagnosis, should I recommend this?

It is reasonable to state that biopsy might be necessary to establish a diagnosis, but there are factors other than the imaging test itself that might influence a decision to biopsy, as mentioned above. Beyond providing information to be considered, it is best to not compel a clinician to undertake an invasive procedure, since there may be reasons unknown to the radiologist why this may not be appropriate for a given patient.

I am concerned my clinical colleagues will not want me to recommend imaging follow-up time frames in my reports. Am I required to include that information in my reports?

No, the follow-up time frames listed on page 13 are typical times, but use your judgment about whether to include specific time frames in your reports.

The management for LR-3 is different in the CEUS and CT/MRI algorithms. Why is that?

As shown by two recent studies^{1,2}, most CT- or MRI-detected LR-3 observations are benign perfusion alterations or indolent lesions that can be followed safely without multidisciplinary discussion (see Manual, pending).

Less is known about the natural history of LR-3 observations detected at CEUS, but indirect evidence suggests that such observations warrant close scrutiny. By definition, all CEUS observations are visible on precontrast B-mode images. In a cirrhotic liver, sonographically visible nodules have high probability of being HCC, unless contrast enhancement features are diagnostic of hemangioma or other benign entity. Verifying the high HCC probability, a recent retrospective study³ found that 60% (45/75) of CEUS LR-3 observations are HCC (see CEUS manual, pending).

References

1. J-Y Choi et al. Indeterminate observations (Liver Imaging Reporting and Data System Category 3) on MRI in the cirrhotic liver: fate and clinical implications. *AJR* 2013. PMID 24147469
2. M Tanabe et al. Imaging outcomes of Liver Imaging Reporting and Data System Version 2014 Category 2, 3, and 4 observations detected at CT and MR Imaging. *Radiology* 2016. PMID 27115054
3. E Terzi, L. De Bonis, S. Leoni, et al. *Dig Liv Dis*, 2017; 49, Suppl 1, e22



Reporting

How many observations should I report individually?

Use your judgment in deciding how many observations to report individually, in aggregate, or as a combination of both. Use the method that conveys your clinically relevant findings and impression in the clearest manner.

What should I report if I see no concerning observations?

LR-1 and LR-2 observations can be reported in aggregate in the Findings. The Impression should convey a simple summary statement such as “no LI-RADS observations suspicious for malignancy”.

How should I report a treated observation?

Report the current response category and current tumor viable size if appropriate. Also, whenever possible, report the pretreatment LI-RADS category (or path diagnosis), and the pretreatment size.

- LR-TR Nonviable, (pretreatment LR-5, 22 mm)

For example:

- LR-TR Viable 20 mm, (pretreatment, LR-5, 32 mm)
- LR-TR Equivocal 15 mm, (pretreatment path-proven HCC, 21 mm)

Any special reporting considerations for transplant candidates with HCC?

A standard CT/MRI LI-RADS report contains the needed information for transplant candidates with HCC: number and size of LR-5 observations, LR-5g observations, and path-proven HCCs, or their viable tumor sizes if treated by a locoregional therapy. List major features for each LR-5 observation. Also report LR-M and LR-TIV observations, as these may affect pretransplant workup and transplant eligibility. LR-5us observations should be reported but they do not contribute to OPTN staging.

What should I report if an observation is biopsied and has a path-proven diagnosis?

This depends on the path diagnosis:

- If malignant or if benign of non-hepatocellular origin (e.g., hemangioma): report observation’s path diagnosis, clinically relevant imaging features, and change since prior: e.g., “path-proven hemangioma, stable in size and other imaging features since prior.”
- If benign of hepatocellular origin (e.g., regenerative or dysplastic nodule): report observation’s LI-RADS category and pathology diagnosis, imaging features, and change since prior: e.g., “LR-4 with path diagnosis of dysplastic nodule, has new APHE and interval growth from 12 to 16 mm.”

What if the path diagnosis is discordant with the LI-RADS category?

Indicate in your report there is discordance, providing the LI-RADS category and the path diagnosis. Explain briefly why this represents a discordance. Consider multidisciplinary discussion with consensus review of the histology, imaging, and other clinical data to adjudicate the discordance.

If I am not supposed to assign a LI-RADS category for path-proven observations, why am I supposed to report their imaging features and change since prior?

Radiologists should continue to characterize major features and key ancillary features for biopsy-proven observations as changes in these features may be clinically relevant. Examples: “Path-proven cholangiocarcinoma with interval growth, based on imaging, from 22 mm to 28 mm” or “Path-proven HCC with interval development, based on imaging, of tumor in vein”.

What should I do if the LI-RADS category assigned using LI-RADS criteria does not adequately convey the actual likelihood of malignancy based on my judgment?

Report LI-RADS category and your judgment assessment: e.g., “LR-4, highly likely to be HCC.”

Where do I find report templates to use in my practice and examples of LI-RADS reports?

These can be downloaded here (pending).



Imaging Features

Is there a minimum size for application of APHE, “washout”, and “capsule”?

No. It suffices that the presence of these features be definite in the judgment of the radiologist.

On what plane should I measure observation size?

For standardization, favor the axial plane. However, you may measure on a different plane on which margins are undistorted and well visualized. Use the same plane on future exams to assess growth.

Does washout appearance apply only to observations with APHE?

No, “washout” may apply even in the absence of APHE, as long as there is some enhancement.

Do washout appearance and APHE need to coincide in the same part of an observation?

No, APHE and washout appearance do not need to coincide in the same part. For example, a 25 mm mass with APHE in one part and “washout” in another part may be categorized LR-5.

Why does “washout” require comparison to composite liver tissue rather than nodules?

Historically, the literature in this field has assessed observation “washout” relative to the background liver—which we interpret as composite liver parenchyma—rather than nodules in particular. Until an alternative comparator is shown to be superior, we will preserve the current approach.

Why can’t I evaluate “washout” in the transitional phase when performing gadoxetate-MRI?

With gadoxetate-MRI, portal venous phase “washout” is relatively specific for HCC. However, transitional phase hypointensity lacks specificity because background liver uptake of the contrast agent is sufficiently high that cholangiocarcinomas and other non-HCC malignancies may appear hypointense. See Manual (pending).

Why does v2017 make a distinction between features that favor malignancy in general vs. features that favor HCC in particular?

Most features favoring malignancy are nonspecific, occurring in HCC and non-HCC. However, some features are specific for HCC and may help differentiate HCC from non-HCC.

If liver enhancement during the HBP is suboptimal, how do I characterize observations that are hypointense, isointense, or hyperintense relative to liver?

If an observation is hypointense in the hepatobiliary phase, it may be characterized as such despite suboptimal hepatobiliary phase parenchymal enhancement. However, if an observation is isointense or hyperintense, characterization of hepatobiliary phase intensity may be unreliable.

LR-M criteria seem most applicable to ICC. What about other non-HCC malignancies?

LR-M criteria were formulated based on limited available evidence, most of which concerns HCC vs. ICC differentiation. There is not yet sufficient evidence to formulate criteria for other non-HCC malignancies (primary or secondary). Fortunately, other malignancies are rare.

How do I differentiate HCC, cholangiocarcinoma, and hepatocholangiocarcinoma?

Some imaging features indicate hepatocellular origin (see below). The presence of such features excludes malignancies of non-hepatocellular origin such as intrahepatic cholangiocarcinoma (ICC) but they do not exclude hepatocholangiocarcinomas (H-ChCs), which contain both hepatocellular and cholangiocellular elements. Implication: for malignant masses with hepatocellular features, the differential diagnosis is HCC and H-ChC; differentiation of HCC from H-ChC may not be possible.

What features suggest hepatocellular origin?

Fat in mass, blood products in mass, nodule-in-nodule, mosaic architecture, intrinsic T1 hyperintensity, HBP isointensity or hyperintensity, enhancing or nonenhancing “capsule”.

Abbreviations

AASLD	American Association for the Study of Liver Diseases
ACR	American College of Radiology
ADC	Apparent diffusion coefficient
AF	Ancillary features
AFP	Alpha-fetoprotein
AP	Arterial phase
APHE	Arterial phase hyperenhancement
CEUS	Contrast-enhanced ultrasound
DP	Delayed phase
DWI	Diffusion-weighted imaging
ECA	Extracellular agent
ECP	Extracellular phase
FNH	Focal nodular hyperplasia
HBA	Hepatobiliary agent
HBP	Hepatobiliary phase
HCA	Hepatocellular adenoma
HCC	Hepatocellular carcinoma
H-ChC	Hepatocholangiocarcinoma
MDD	Multidisciplinary discussion
OPTN	Organ Procurement and Transplantation Network
PVP	Portal venous phase
T2WI	T2-weighted imaging
TACE	Transcatheter arterial chemoembolization
TIV	Tumor in vein
TP	Transitional phase
WO	“Washout” or washout appearance