THE UNIVERSITY OF MISSISSIPPI
MEDICAL CENTER

Pitfalls in Post COVID-19 vaccination PET/CT findings- Beware of different patterns of uptake during interpretation and patient's immune status

Authors

- Matin Goldooz, M.D.[1]
- Anson L. Thaggard, M.D.[1]
- William P. Berlin, M.D.[1]
- Vani Vijayakumar, M.D.[1]

[1] University of Mississippi Medical Center

Disclosure

Neither the authors nor their immediate family members have a financial relationship with a commercial organization that may have a direct or indirect interest in the content.

Purpose

To educate the interpreting diagnostic radiologist of the patterns of abnormal PET/CT uptake after mRNA-based COVID-19 vaccination and provide guidelines for post vaccine scheduling instructions.

Background

- After mRNA-based COVID-19 vaccination, a high proportion of patients show PET/CT uptake of the axillary and supraclavicular lymph nodes, which is more common in immunocompetent patients.
- There are cases of increased FDG uptake in axillary, supraclavicular, cervical lymph nodes and spleen following pneumococcal/influenza vaccination.[1]
- There is different intensity of FDG uptake related to the proximity to the site of vaccination.
- With Omicron infection there is prominent, symmetric FDG uptake throughout the nasopharynx, oropharynx, and tonsils with or without associated FDG-avid cervical lymphadenopathy, particularly in the suprahyoid neck.

[1]*McIntosh LJ, et. Al. COVID-19 Vaccination-Related Uptake on FDG PET/CT: An Emerging Dilemma and Suggestions for Management. AJR Am J Roentgenol. 2021*

Case 1:
65-year-old female with multiple solitary plasmacytomas (left acromion and left sixth rib) status post radiation therapy. Status post recent COVID-19 vaccination.

FDG PET/CT findings:
Maximum intensity projection (A), Fusion (B, C, D), Axial non-attenuation correlation CT (E, F, G) show mild abnormal uptake corresponds to subcentimeter left **subdeltoid**, **axillary**, and **supraclavicular** nodes.
The left supraclavicular node yields an SUVmax 3.5.

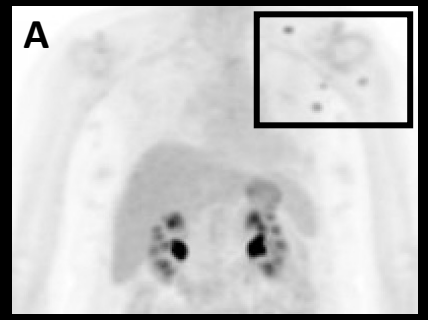

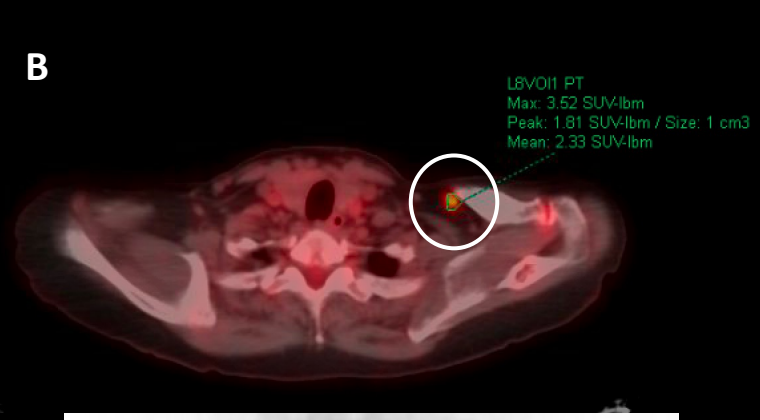

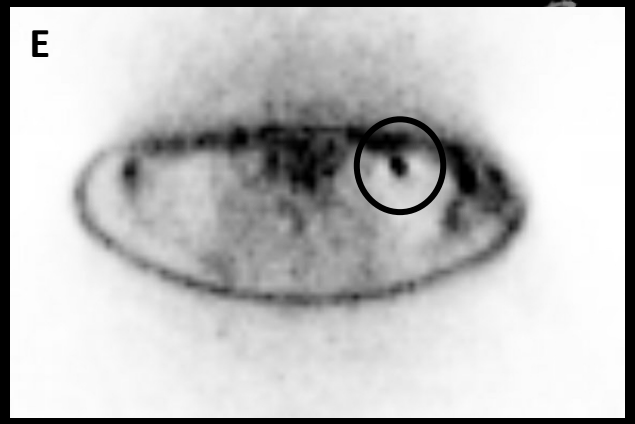

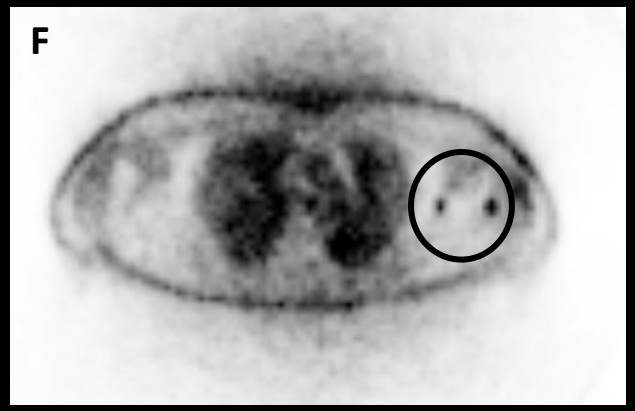

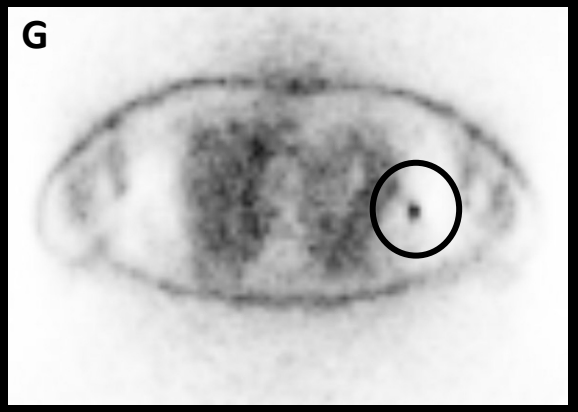

Case2:
51-year-old female with metastatic right-sided breast cancer, status post mastectomy and right axillary nodal dissection, followed by chemotherapy.
COVID-19 Moderna vaccine administration to the left arm three weeks before the exam.

FDG PET/CT findings:
Maximum intensity projection (A), Fusion (B), Axial non-attenuation correlation CT (C) show low-level uptake corresponds to nonenlarged left **axillary/subpectoral** nodes with preserved fatty hila, SUVmax 2.5.

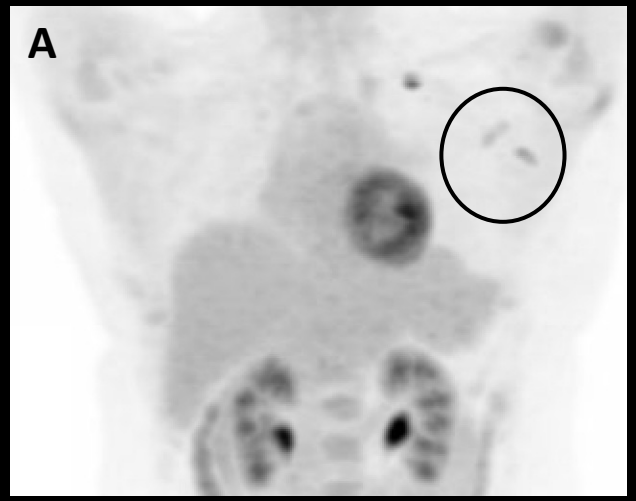

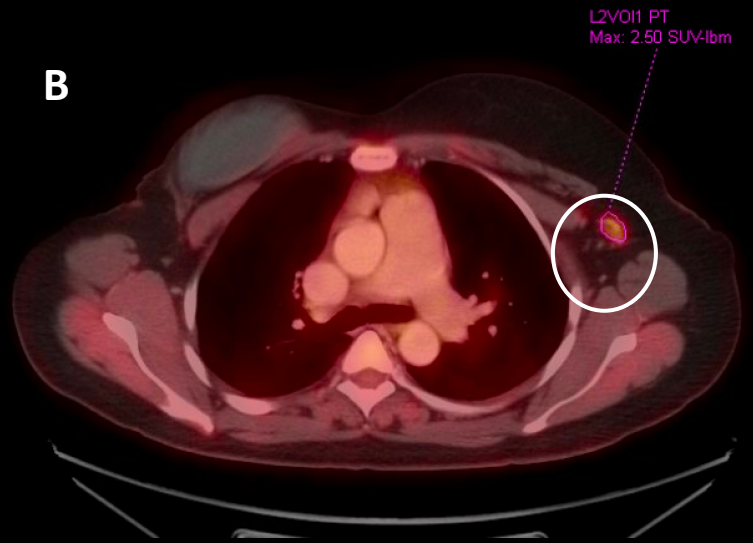

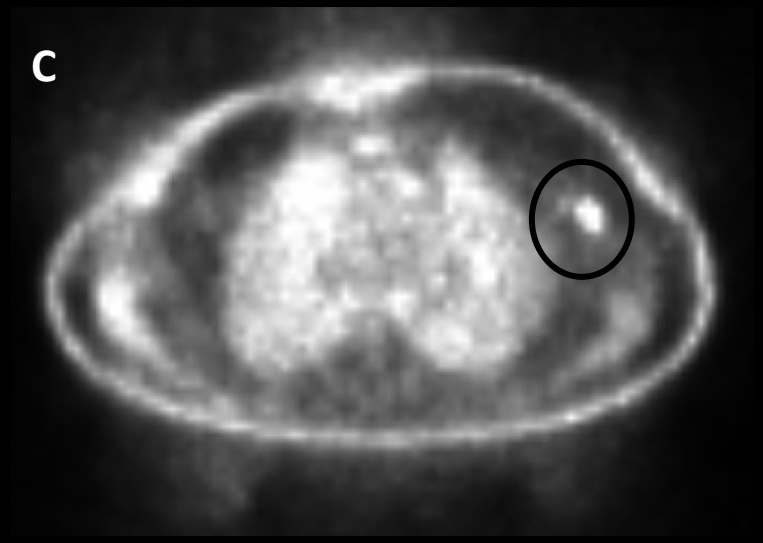

Case 3:
47-year-old male with cutaneous T-cell lymphoma/mycosis fungoides, status post chemotherapy and autologous bone marrow transplant. Status post Pfizer COVID-19 vaccination on Left deltoid 2/5 weeks before the exam.

FDG PET/CT findings:
Maximum intensity projection (A), Fusion (B, C), Axial attenuation correlation CT (D) show FDG-avid nonenlarged morphologically normal **axillary** nodes.
The left axillary node yields an SUVmax 4.8.

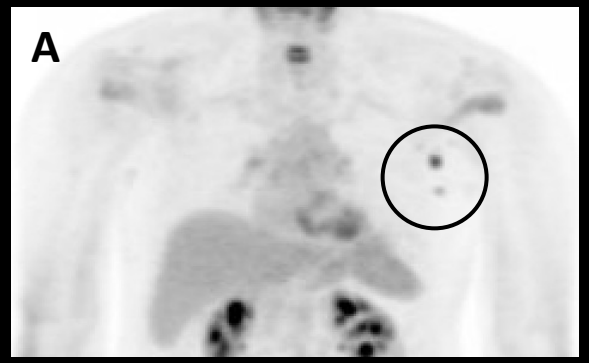

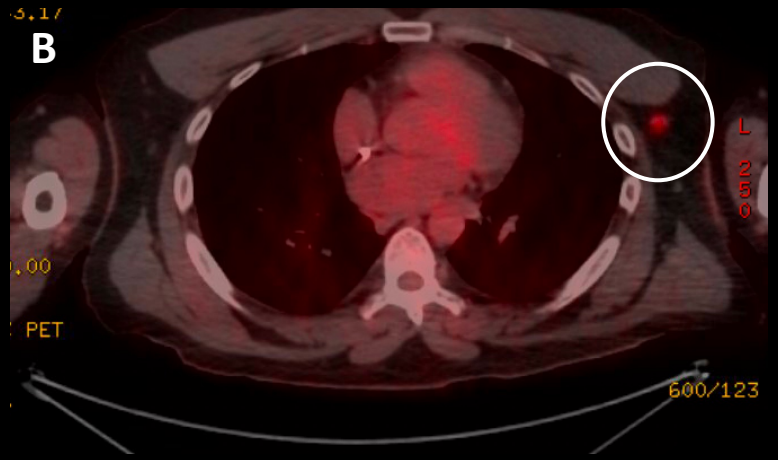

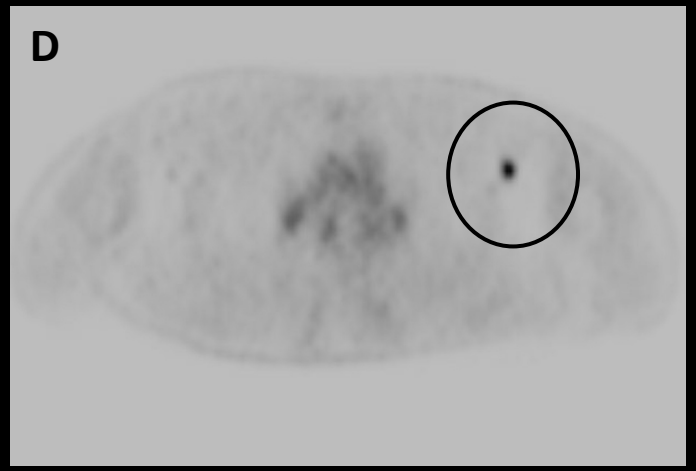

Case 4:
67-year-old female with adenocarcinoma of the RUL (T3N0M0), status post lobectomy and chemotherapy. Recent receipt of COVID-19 vaccine in the left deltoid.

FDG PET/CT findings:
Fusion (A, B, C), Axial non-attenuation correlation CT (D, E) show reactive left **axillary** nodal uptake, SUVmax 1.5, related to recent receipt of the COVID-19 vaccine.

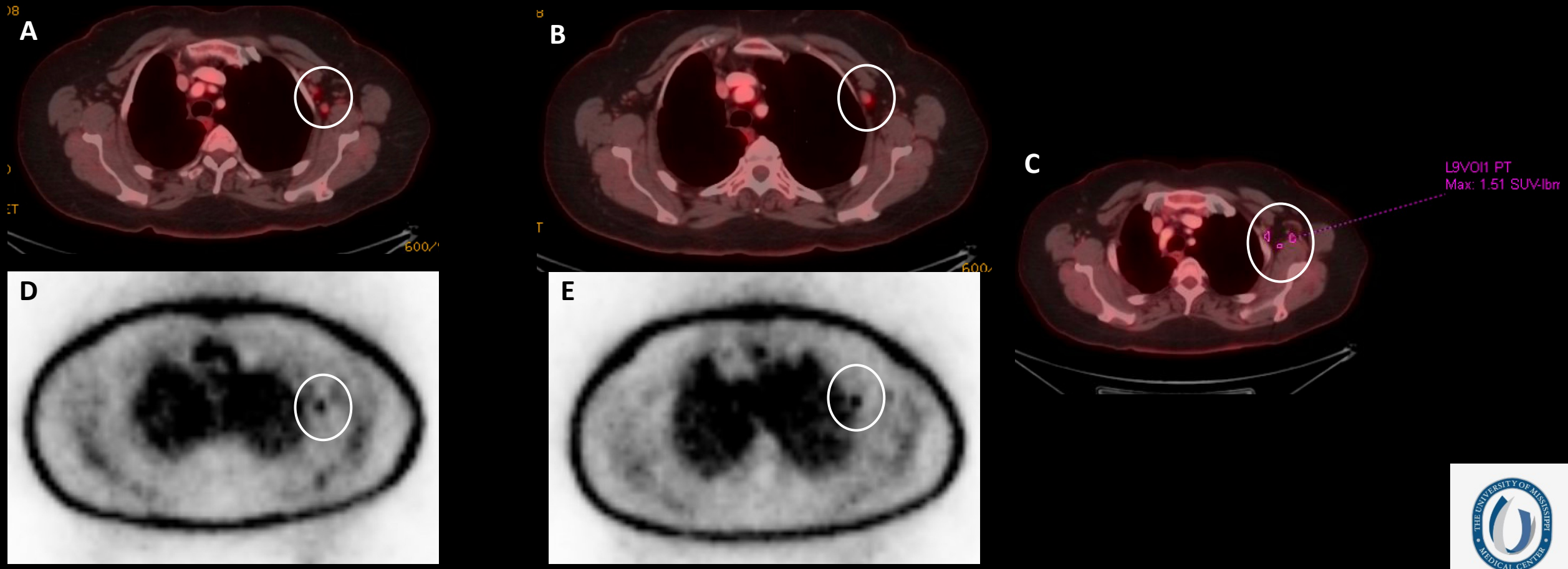

Case 5:
64-year-old female with stage IIB, HR+ Left breast cancer, status post left mastectomy and chemotherapy and right mastectomy for DCIS. Status post recent receipt of the COVID-19 vaccine in the right upper gluteal quadrant.

FDG PET/CT findings:
Axial attenuation correlation CT (A), Fusion (B), Maximum intensity projection (C), show mild uptake corresponds to slightly enlarged but morphologically normal right **inguinal** nodes, likely reactive.
The most hypermetabolic inguinal node registers SUVmax 2.9.

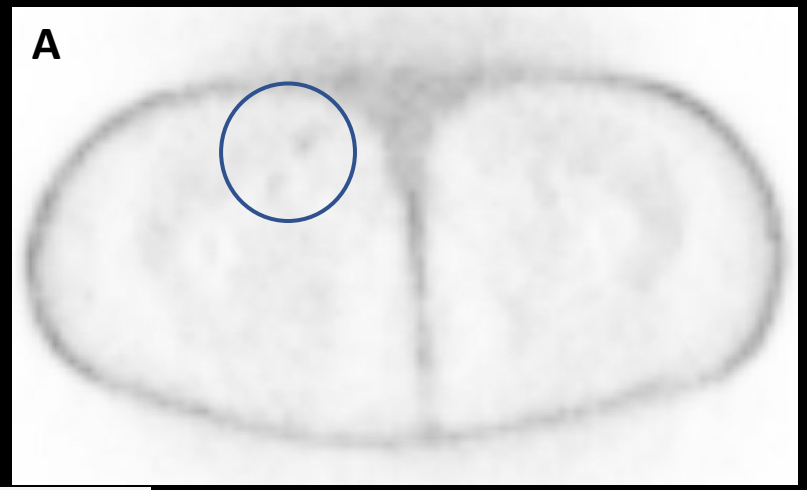

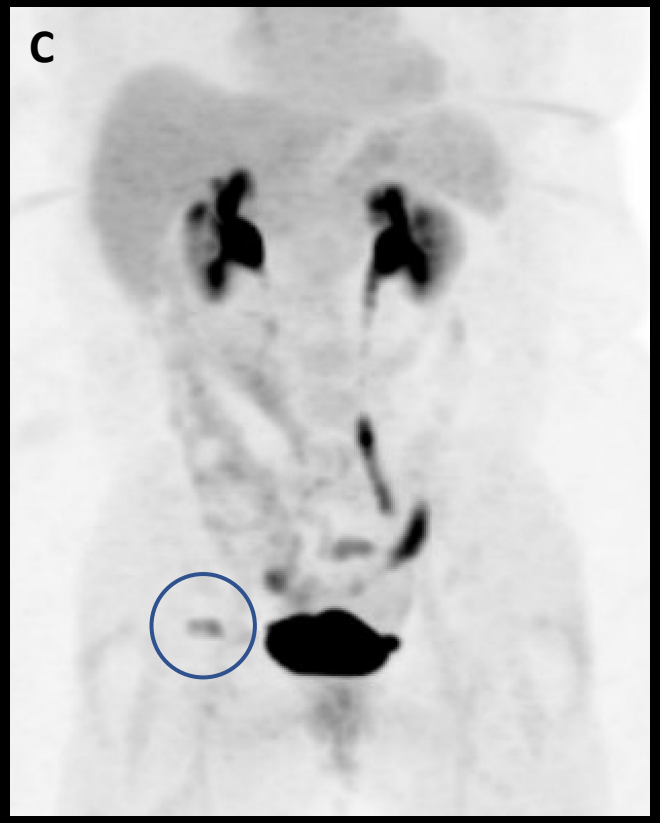

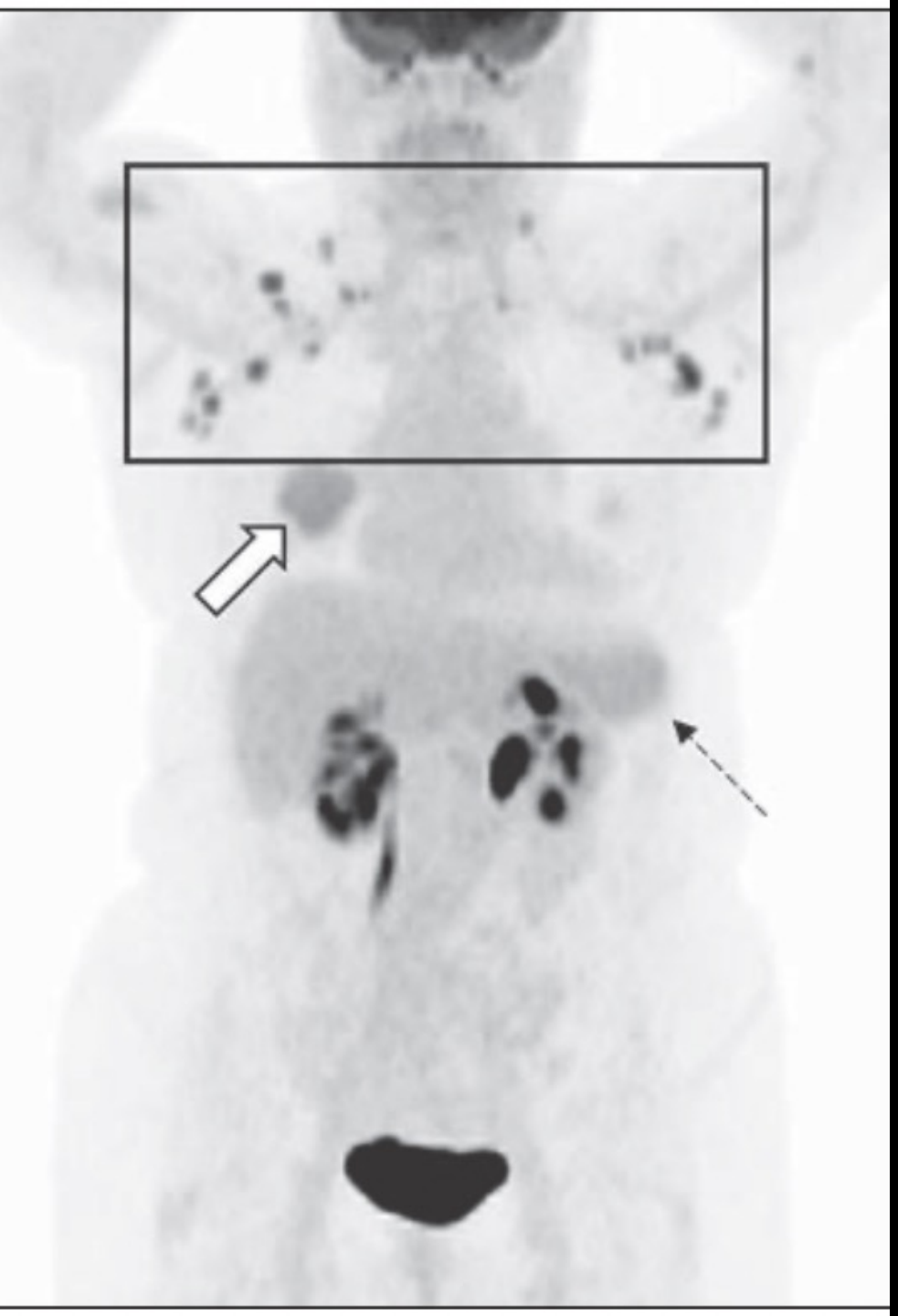

- **Case 6:**

FDG PET/CT scan four weeks after right pneumococcal and left influenza deltoid vaccination represent FDG uptake in bilateral axillary, supraclavicular and cervical lymph nodes. FDG uptake in spleen is mildly increased.[1]

[1] Case courtesy of McIntosh LJ, et. Al. COVID-19 Vaccination-Related Uptake on FDG PET/CT: An Emerging Dilemma and Suggestions for Management. AJR Am J Roentgenol. 2021

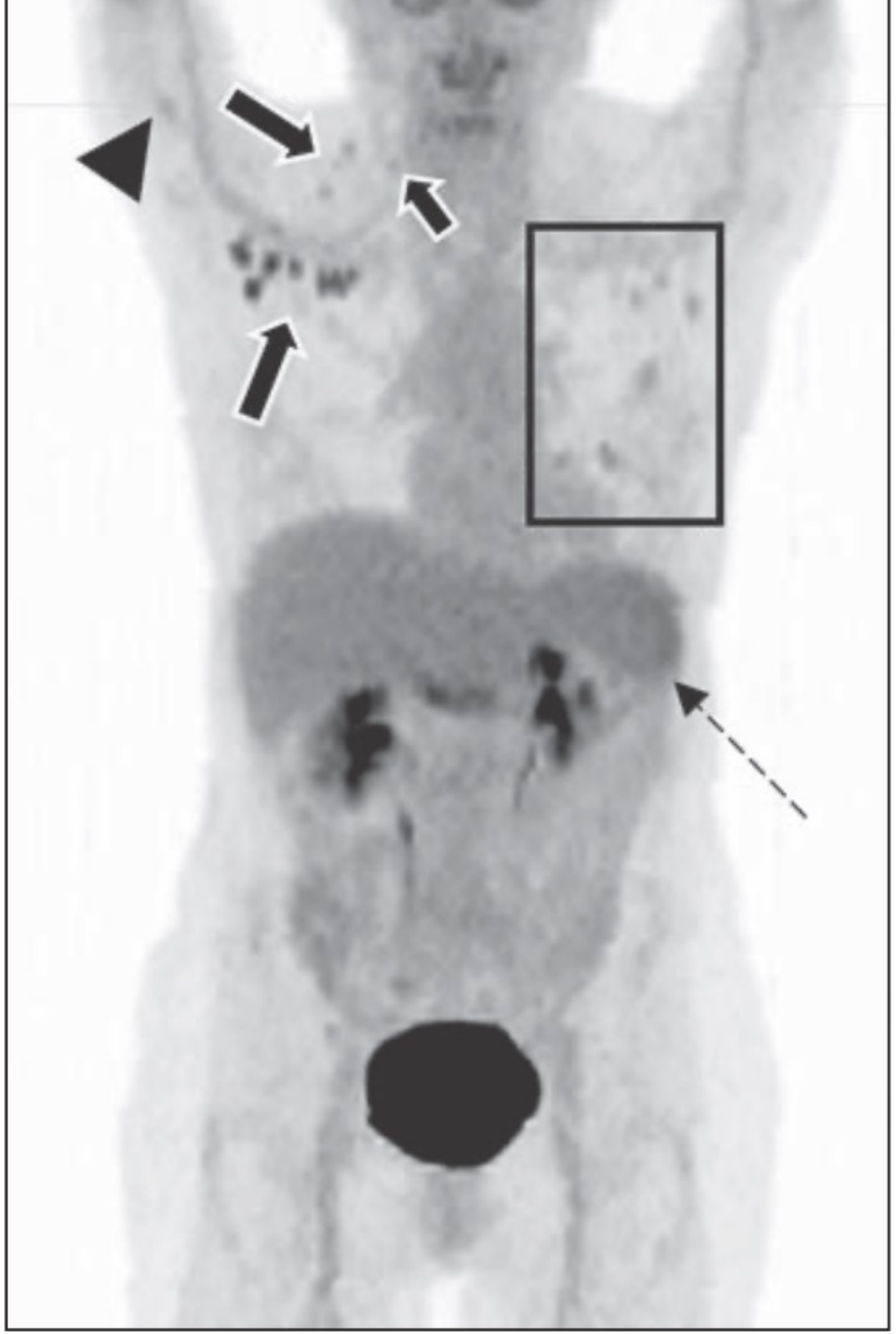

- **Case 7:**

Patient with history of breast cancer with left sided nodal involvement. Two days following right deltoid influenza vaccine, FDG PET/CT shows increased uptake in right cervical, supraclavicular and axillary lymph nodes.

[1] *Case courtesy of McIntosh LJ, et. Al. COVID-19 Vaccination-Related Uptake on FDG PET/CT: An Emerging Dilemma and Suggestions for Management. AJR Am J Roentgenol. 2021*

Conclusion

- Ipsilateral lymph node FDG PET/CT uptake after COVID-19 vaccination can misinterpret as progressive/metastatic cancer. Therefor a thorough data collection regarding the prior vaccination is warranted to identify the COVID-19 vaccination as the potential cause of the lymph node uptake.
- Mostly lymph node-predominant diseases including lymphoma and Castleman disease, as well as cancers prone to involvement of lymph nodes, including breast cancer, trunk or upper extremity melanoma or sarcoma, lung cancer (particularly upper lobes), head and neck cancers are also involved by COVID-19 vaccination.
- Perform FDG PET/CT before or at least 2 weeks after, but optimally 4–6 weeks after vaccine administration if possible; do not delay COVID-19 vaccination or FDG PET/CT examination that is clinically warranted earlier. Advise patients to receive vaccine in contralateral arm if disease has laterality.
- After mRNA-based COVID-19 vaccination, a high proportion of patients show ipsilateral axillary lymph node uptake, which is more common in immunocompetent patients. This information will help with the recognition of PET/CT pitfalls and may hint about the patient’s immune response to the vaccine.

References:

1. *McIntosh LJ, Bankier AA, Vijayaraghavan GR, Licho R, Rosen MP. COVID-19 Vaccination-Related Uptake on FDG PET/CT: An Emerging Dilemma and Suggestions for Management. AJR Am J Roentgenol. 2021 Oct;217(4):975-983. doi: 10.2214/AJR.21.25728. Epub 2021 Mar 1. PMID: 33646823.*

2. *Eifer M, Tau N, Alhoubani Y, Kanana N, Domachevsky L, Shams J, Keret N, Gorfine M, Eshet Y. COVID-19 mRNA Vaccination: Age and Immune Status and Its Association with Axillary Lymph Node PET/CT Uptake. J Nucl Med. 2022 Jan;63(1):134-139. doi: 10.2967/jnumed.121.262194. Epub 2021 Apr 23. PMID: 33893188; PMCID: PMC8717182.*