Clinico-Anatomical Correlation Method: Utilizing Free Software and Novel MultiJet Fusion Technology to Create Stand-Alone, Fully Customizable, Colored and Labeled 3D Printed Educational Models

Lauren Arsenault MS, Muhammad Rehman BA, Navjot Singh MD, Ahmed Abdelmonem MBBS, Murwarid Rahimi BA, Ramin Javan MD

GW School of Medicine & Health Sciences

Disclosures

- None of the authors have individual disclosures to report
- The printing and materials of the surface anatomy of the brain model used in this manuscript were printed free of charge by HP printing services.

Purpose

3D Printing (3DP) remains somewhat elusive to anatomy educators and learners as an independent tool.

Factors such as cost, design difficulty, and lack of model versatility and utility developing **standalone, colored and labeled** was not simple

Now, MultiJet Fusion (MJF) technology allows for such models to be created. These standalone models can be tailored to correlate seamlessly with radiologic studies for educational purposes.

We hope to demonstrate that the use of complex standalone 3D printed models will allow learners to better conceptualize difficult anatomical structures and relationships as they pertain to important clinical contexts.

Methods/Materials

- Blender was utilized via image texturing to create colored and labeled 3D models that were either 3D reconstructed from cross-sectional imaging or graphically designed, both realistically and conceptually.
- Models were then printed using MJF technology. A set of clinical case series are shown to highlight the usefulness of the aforementioned custom-made 3D models.

Methods/Materials

Clinico-anatomical correlation examples include:

- **Dorello's canal Schwannoma**, **nasopharyngeal carcinoma** as a cause for unilateral mastoid effusion
- **Metastatic lesion in Broca's area**
- **Cholesteatoma** in the Prussak space
- **Infarct in hand motor** activation center in the precentral gyrus

Dorrelo's Canal Schwannoma

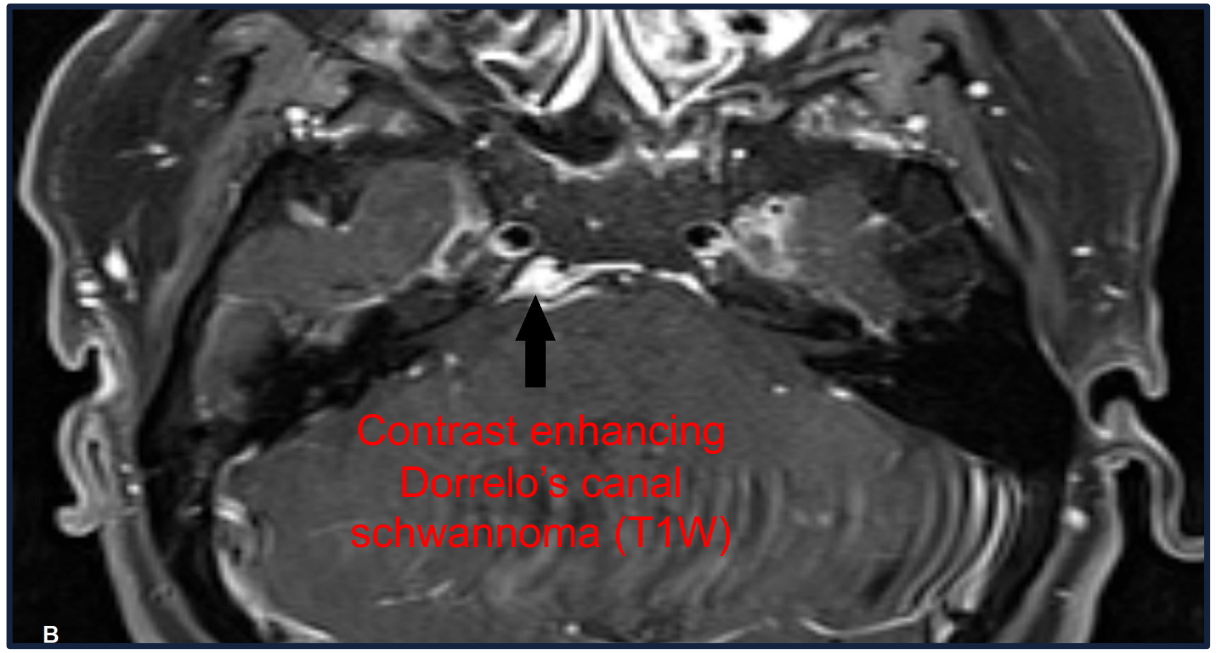

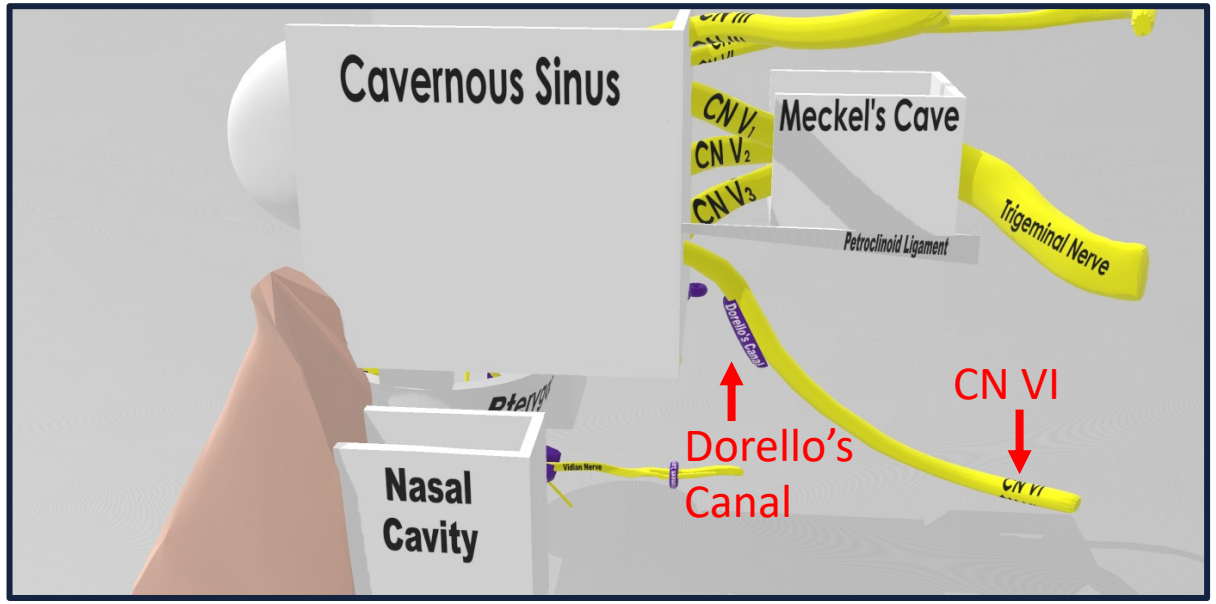

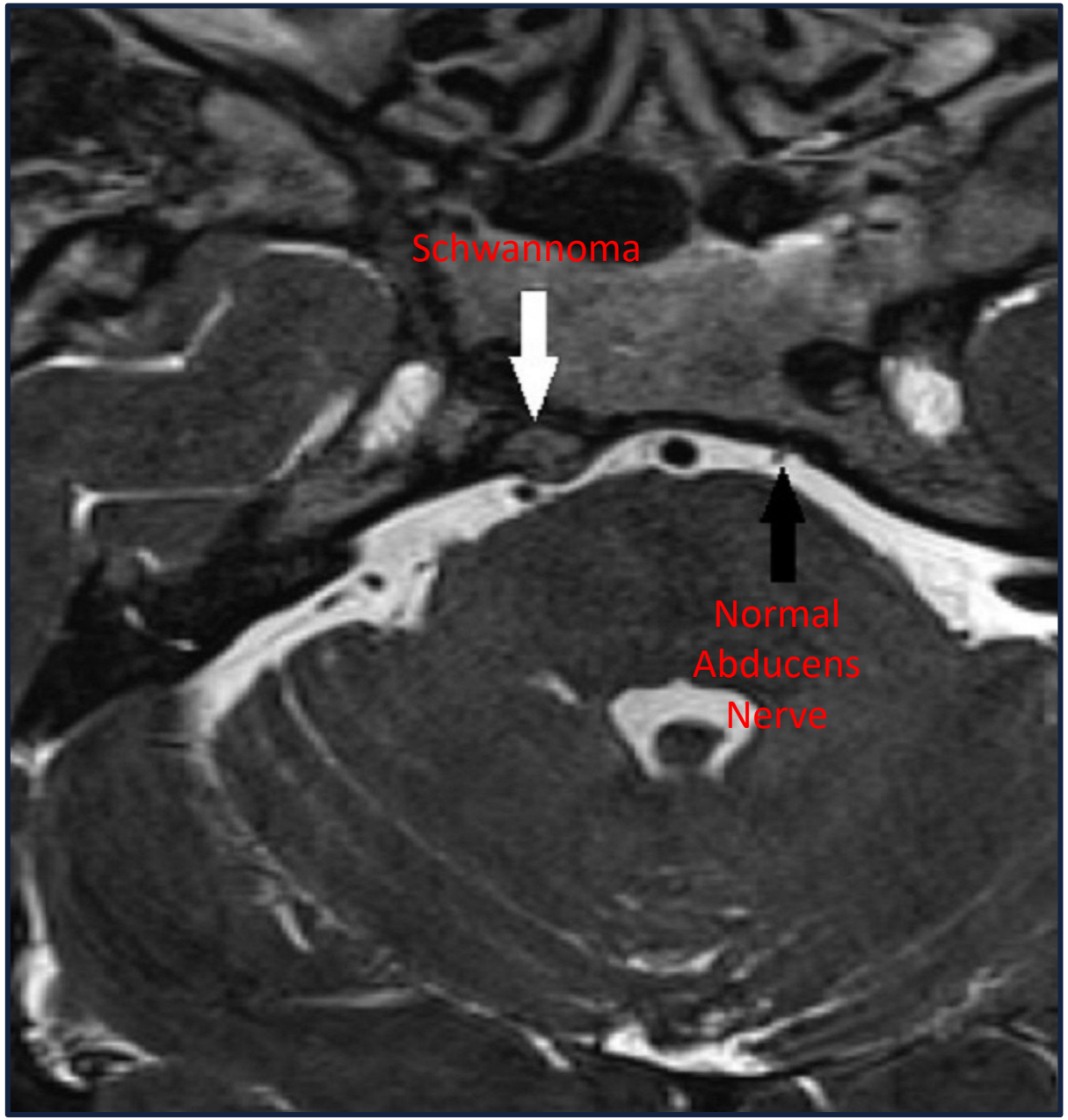

Nasopharyngeal Carcinoma with Eustachian Tube Obstruction and Mastoid Air Cell Fluid

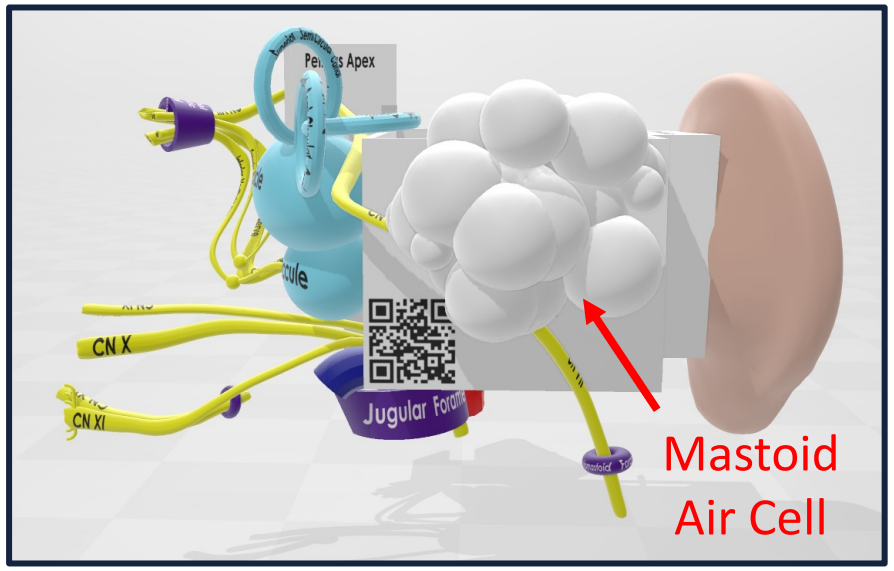

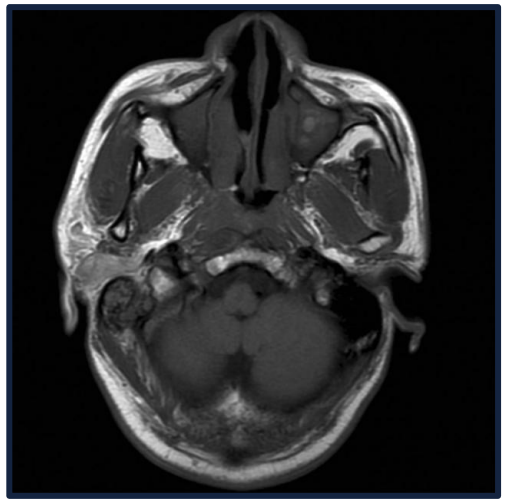

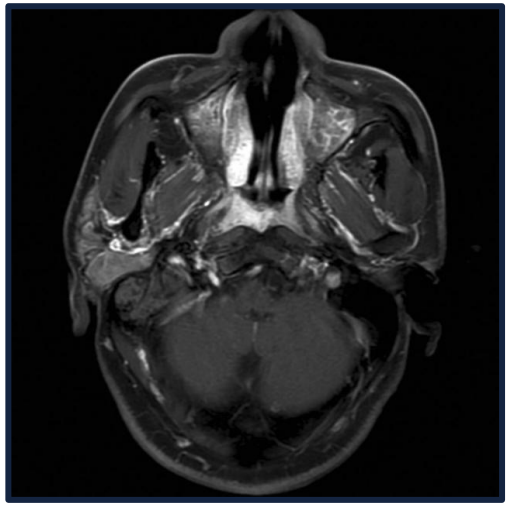

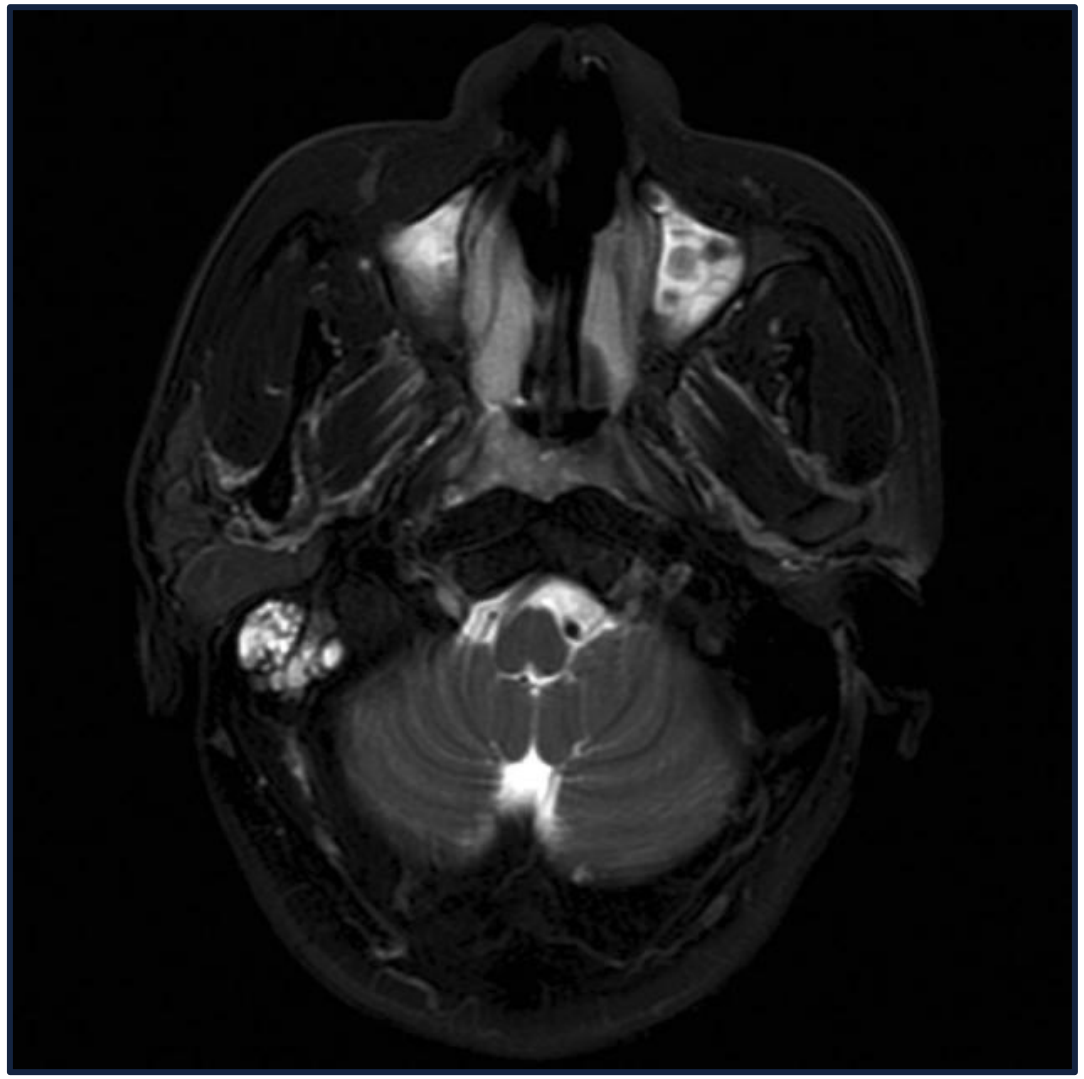

MRI Images from:
Gaillard, F. Nasopharyngeal carcinoma. Case study, Radiopaedia.org. (accessed on 11 Apr 2022) https://doi.org/10.53347/rID-8968

Metastasis In Supramarginal Gyrus

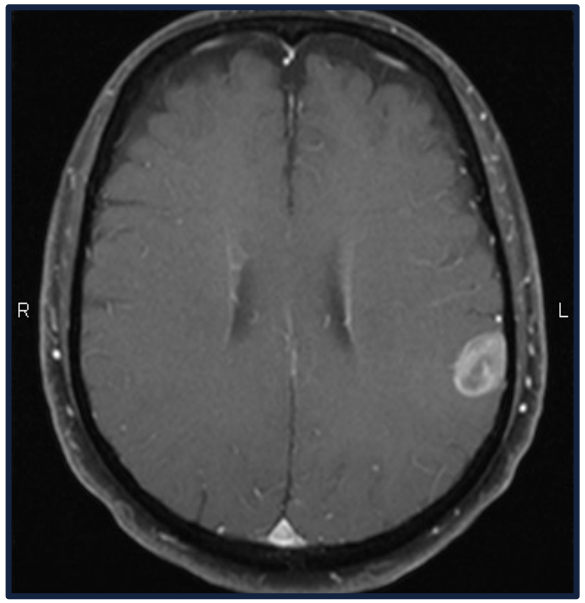

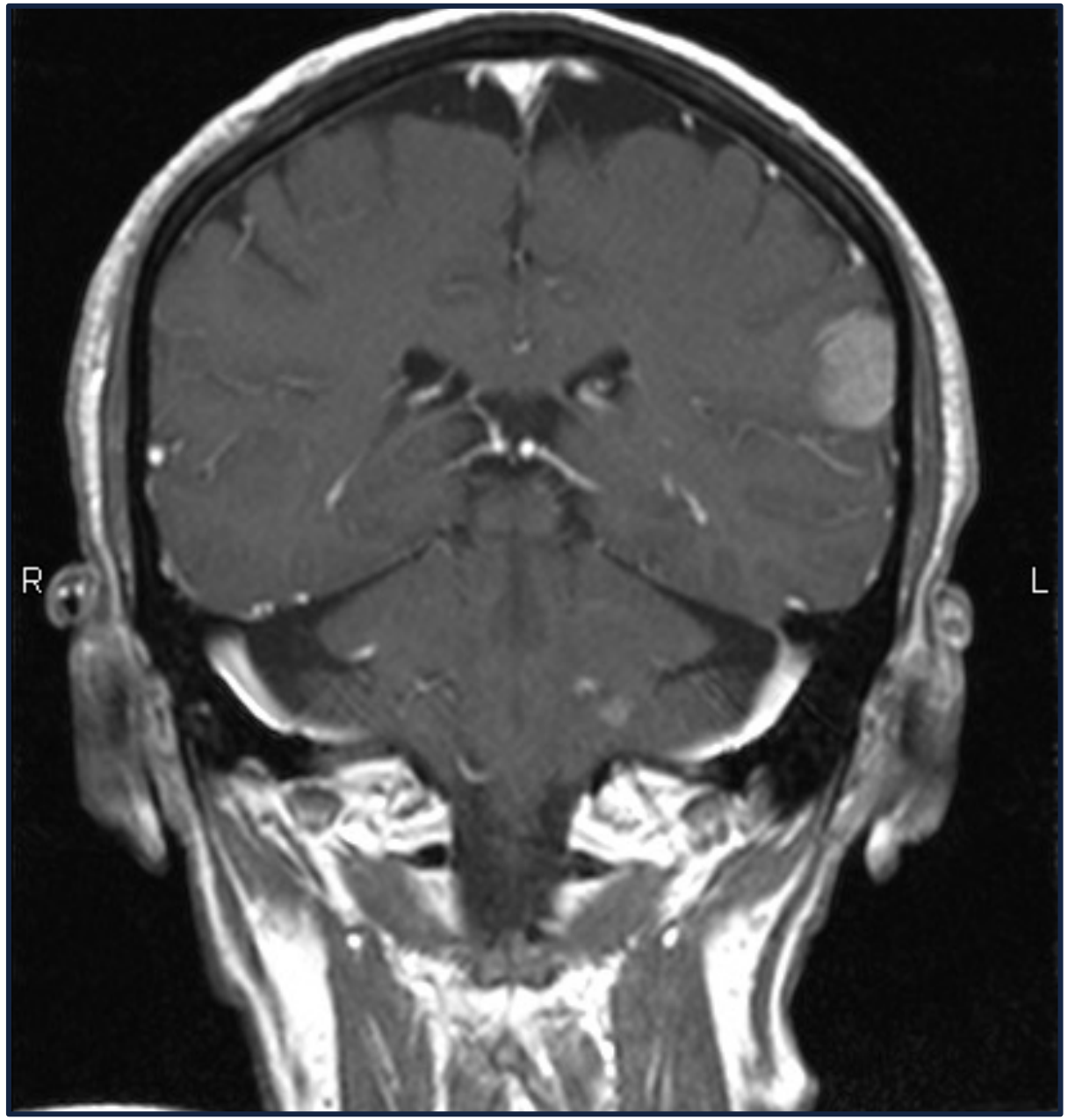

Ganglioglioma in Broca's Area

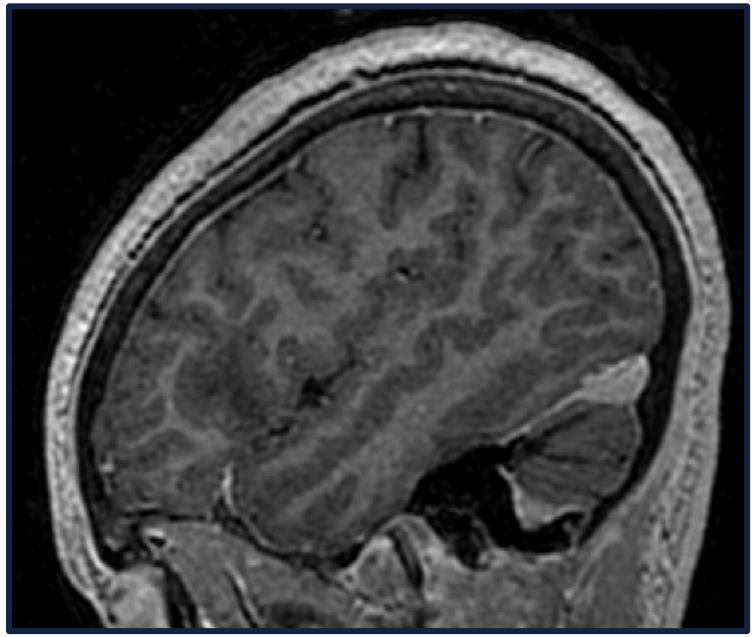

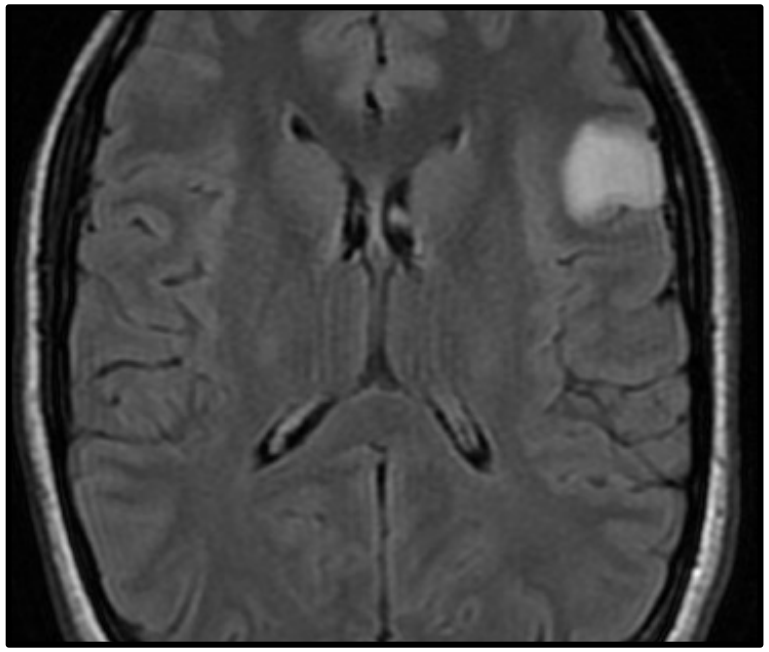

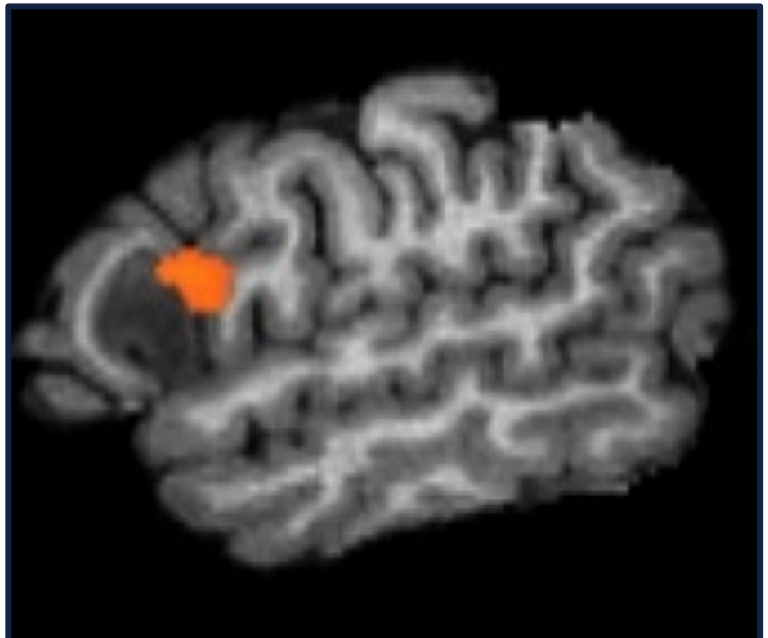

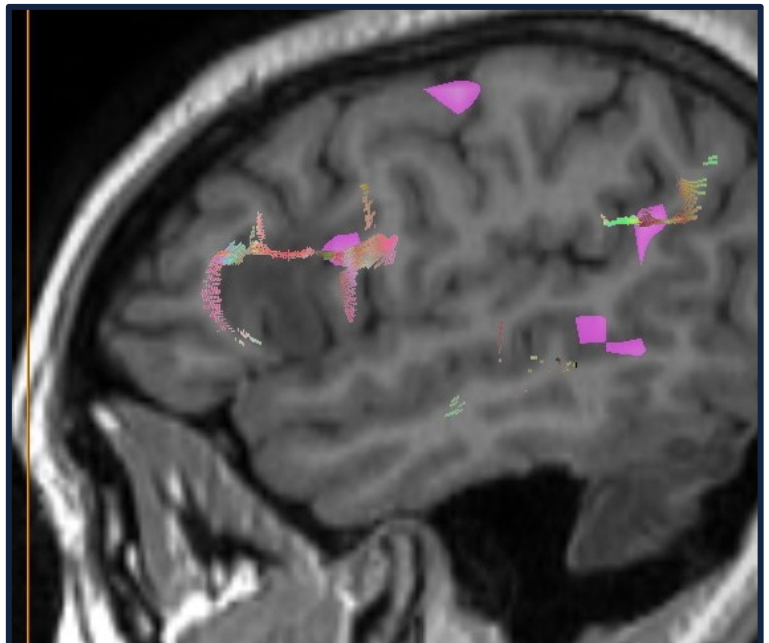

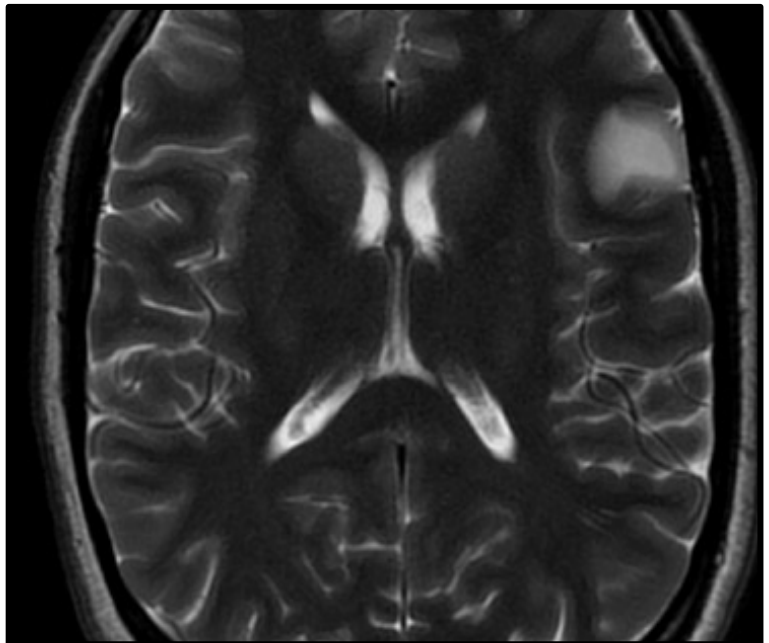

Cholesteatoma in Prussak's Space

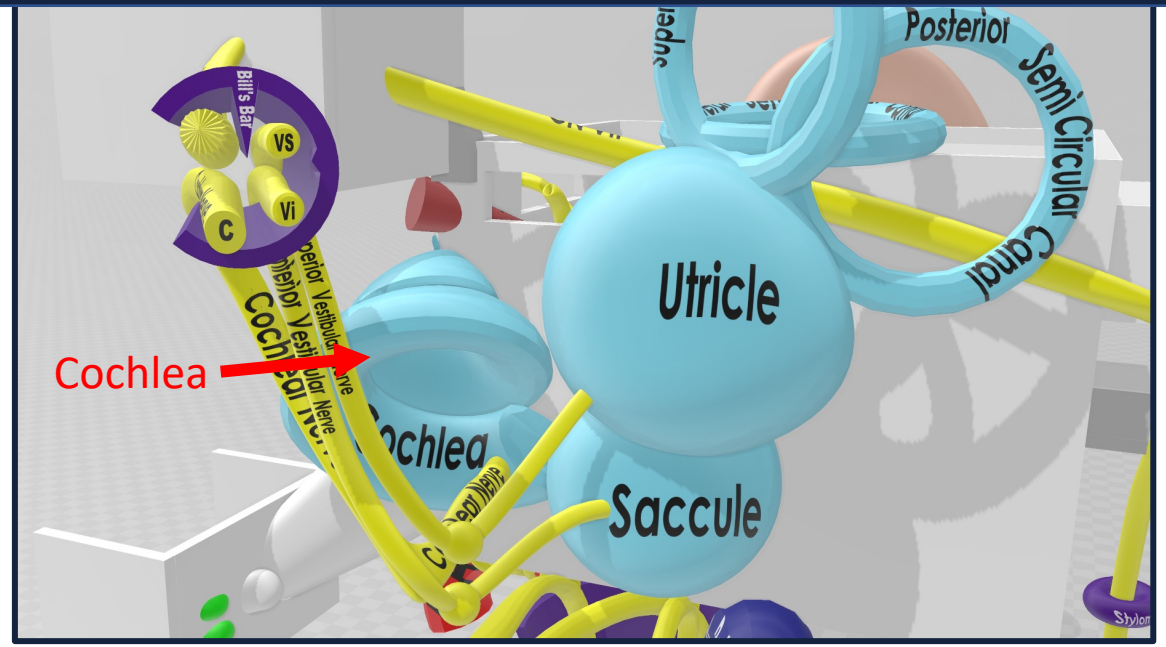

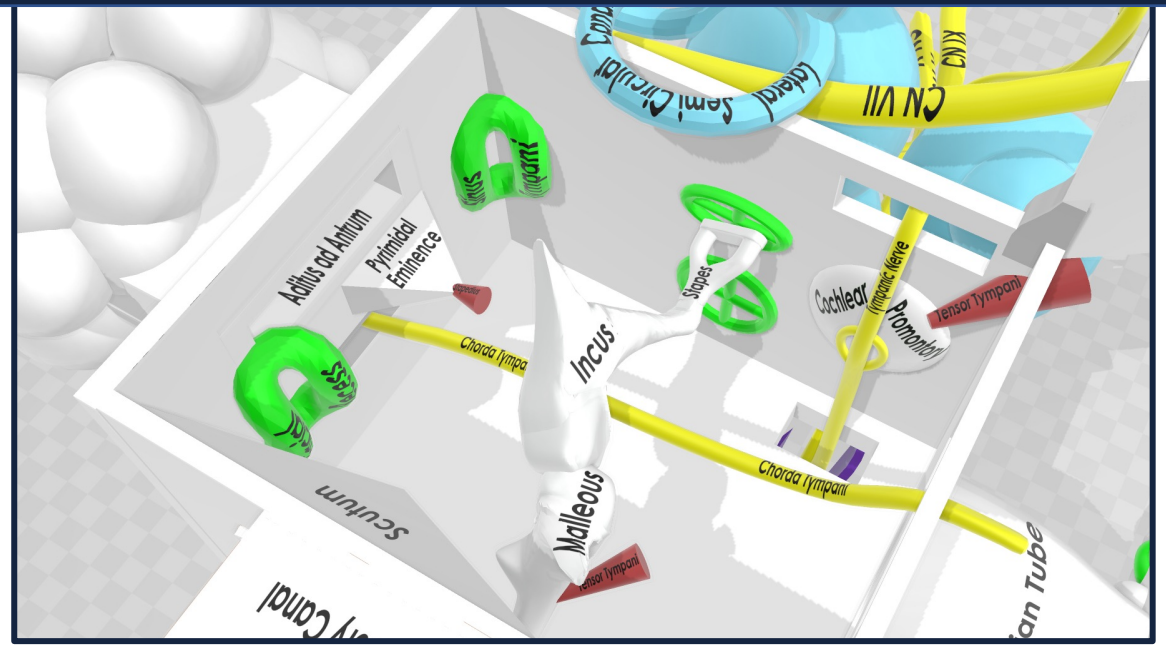

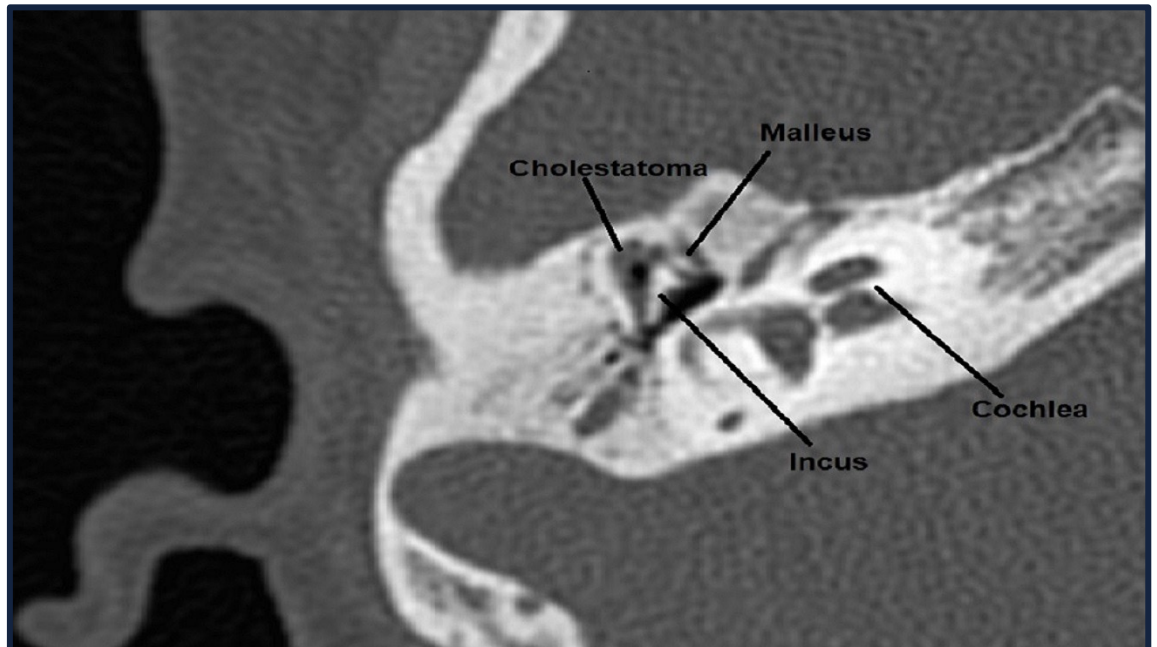

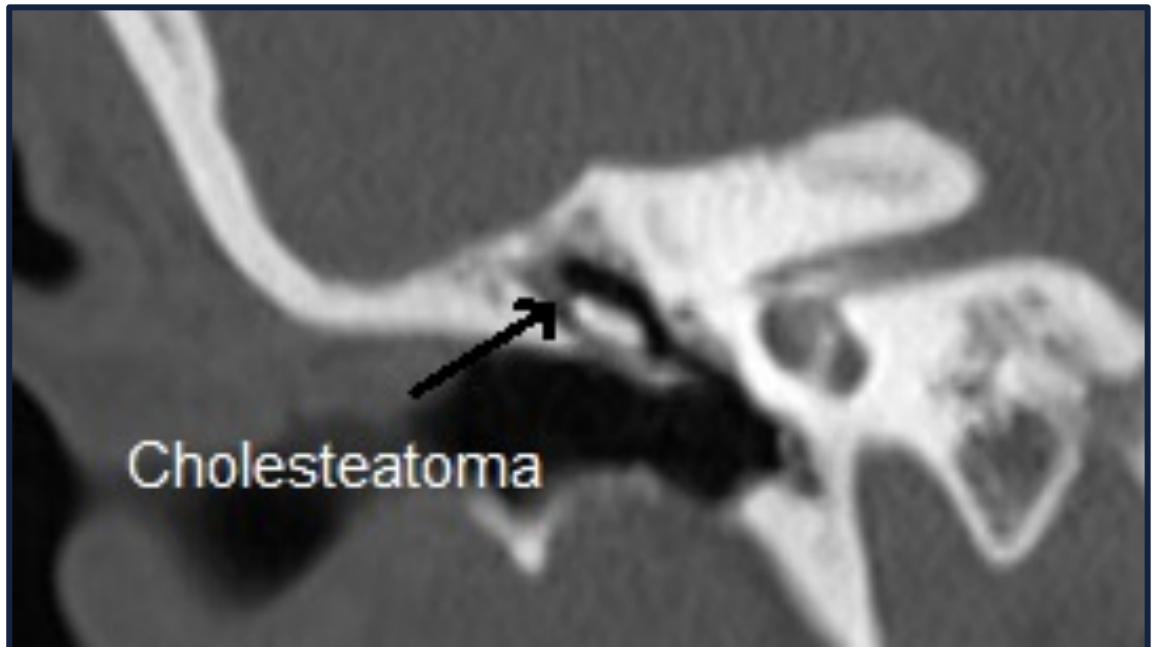

Hand Motor Cortex Infarct

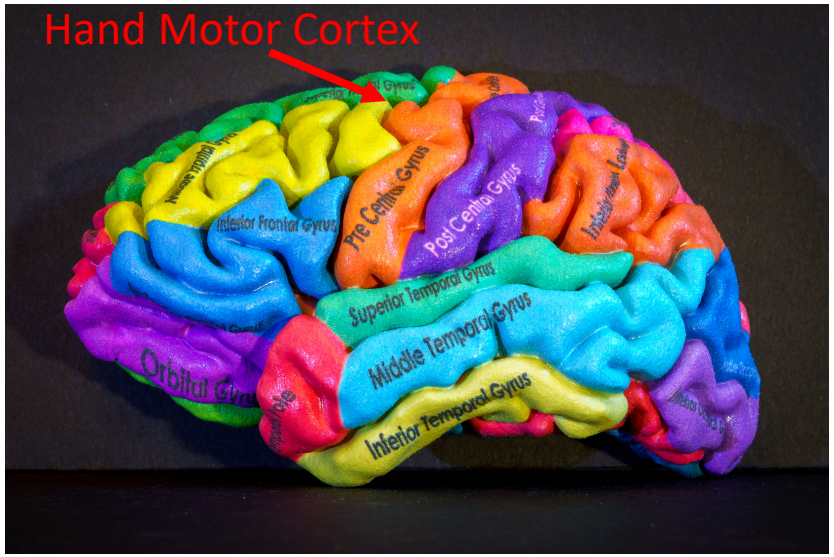

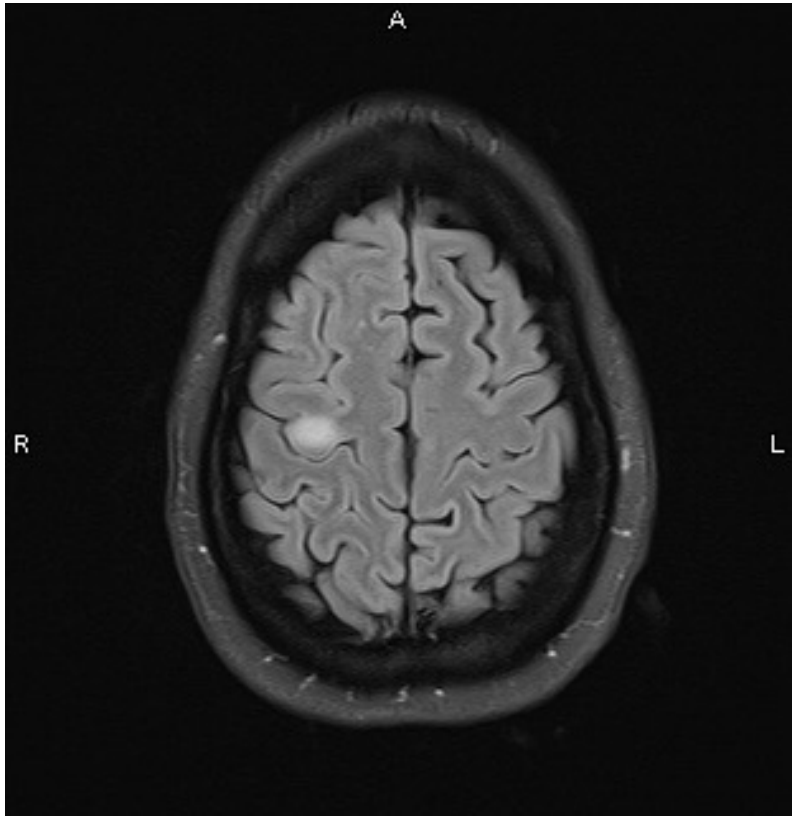

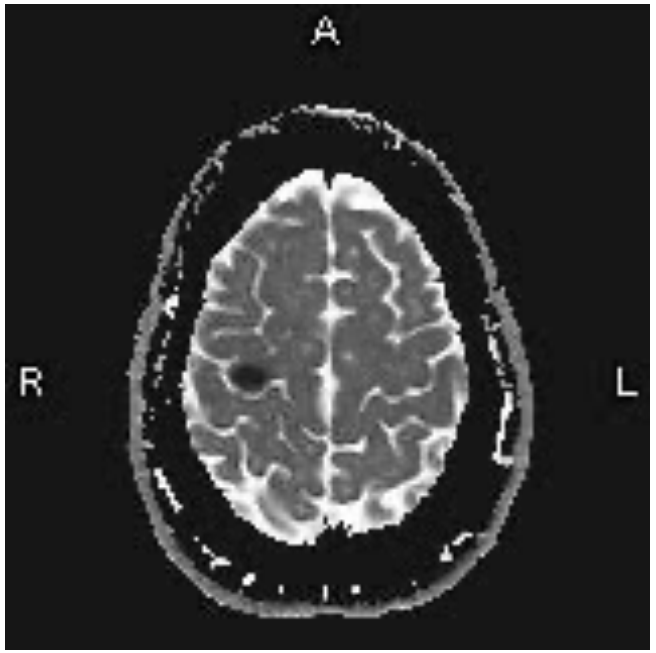



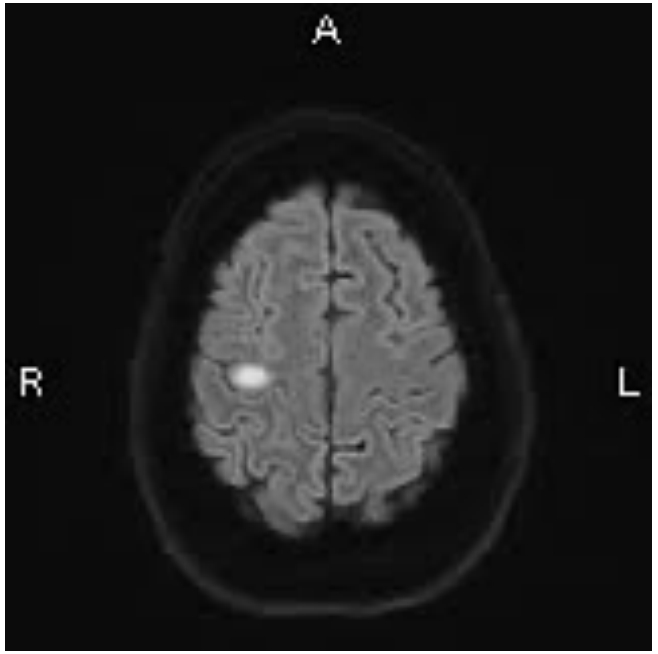

Results

We provide customized color and labeled 3D renderings of the liver segments and coronary arteries and prints of the brain surface, ventricles of the brain, and a detailed conceptual skull base model that demonstrate their uniqueness in highlighting clinical correlates as they pertain to radiology.

Conclusions

- 3DP is a field of technology that continues to innovate, allowing us to develop new use case scenarios.
- From an education standpoint, models are now capable of featuring dynamic color, texture, clear labels, and do not require keys or additional information to learn from them.
- Our stand-alone 3D models are useful learning tools for future and current trainees, especially with the addition of clinical correlates that demonstrate relevant pathology.

References

- Gaillard, F. Nasopharyngeal carcinoma. Case study, Radiopaedia.org. (accessed on 11 Apr 2022) https://doi.org/10.53347/rID-8968
- Mitsouras D, Liacouras P, Imanzadeh A, Giannopoulos AA, Cai T, Kumamaru KK, George E, Wake N, Caterson EJ, Pomahac B, Ho VB, Grant GT, Rybicki FJ. Medical 3D Printing for the Radiologist. Radiographics 35(7):1965-88. DOI: 10.1148/rg.2015140320, Nov-Dec 2015.
- Ballard DH, Trace AP, Ali S, et al.: Clinical Applications of 3D Printing: Primer for Radiologists. Acad Radiol, DOI:10.1016/j.acra.2017.08.004, 2018.
- Ye Z, Dun A, Jiang H, et al. The role of 3D printed models in the teaching of human anatomy: a systematic review and meta-analysis. BMC Med Educ 20(1):335. DOI:10.1186/s12909-020-02242-x, September 29, 2020.