UTSouthwestern
Medical Center
Radiology

Best Practices:

Evidence-based Imaging Algorithm for Pathologic Nipple Discharge in Women

Joshua Amaya, BS; Yin Xi, PhD; Stephen Seiler, MD;
Başak Dogan, MD
University of Texas Southwestern Medical Center,
Department of Radiology, Dallas, TX

Disclosures

The authors have no relevant conflicts of interest

Introduction

- Pathological nipple discharge (PND) can be benign or malignant and tends to be unilateral, spontaneously from a single duct, and serous or blood-stained.

- Intraductal papilloma is the most common cause of PND (21-57%), followed by ductal ectasia and fibrocystic change (14-43%). Cancer is identified in etiology in 5-16% of patients with PND.

- Most commonly, mammogram, ultrasound and MRI is performed. There is a very wide range of diagnostic performance
  - **Mammo** – Sensitivity: 13%, Specificity: 97%
  - **US** – Sensitivity: 73%, Specificity: 97%
  - **MRI** – Sensitivity: 75%, Specificity: 100%

Purpose

- While these modalities are used complementarily, it is unclear when MRI is warranted. It is also unclear and if surgical excision is needed if imaging is negative.
- Therefore, our aim is to use contemporary sensitivity, specificity, positive predictive value (PPV), and negative predictive value (NPV) data to develop a best practices algorithm for evaluating pathologic nipple discharge (PND).

Methods- Search criteria, inclusion and exclusion

Studies between January 1, 2000, and May 5, 2021 that published sensitivity, specificity, PPV, and/or NPV data on all imaging modalities used to diagnose the etiology of PND were reviewed.

Inclusion

- Title/abstract pertains to pathological, spontaneous, bloody and unilateral" discharge
- Sensitivity, specificity, PPV, and/or NPV data available
- Female gender
- Age, 40 or older
- Mammography and/or ultrasound and/or MRI performed for diagnosis
- Ductogram was not included

Sensitivity and specificity end point:
1. Detection of malignancy in etiology.
2. Detection of benign or malignant etiology.

Diagnostic odds ratio and AUC were calculated.

Methods- Analysis

Forest plots were performed to pool sensitivity and specificity of Mammography, Ultrasound and MRI in identifying

A) Any etiology (duct ectasia, benign papilloma, periductal inflammation, ductal carcinoma in situ or invasive cancer)

B) Cancer

To summarize the sensitivity and specificity data for study as a single number, logarithm diagnostic odds ratios (DOR) were calculated.

Summary receiver operator characteristic (ROC) plots were generated to assess the performance of each modality and show the precision of each studies sensitivity and specificity data.

Additionally, In order to detect performance against all possible detection thresholds, **posterior distribution** of area under curve (AUC) was performed

Results

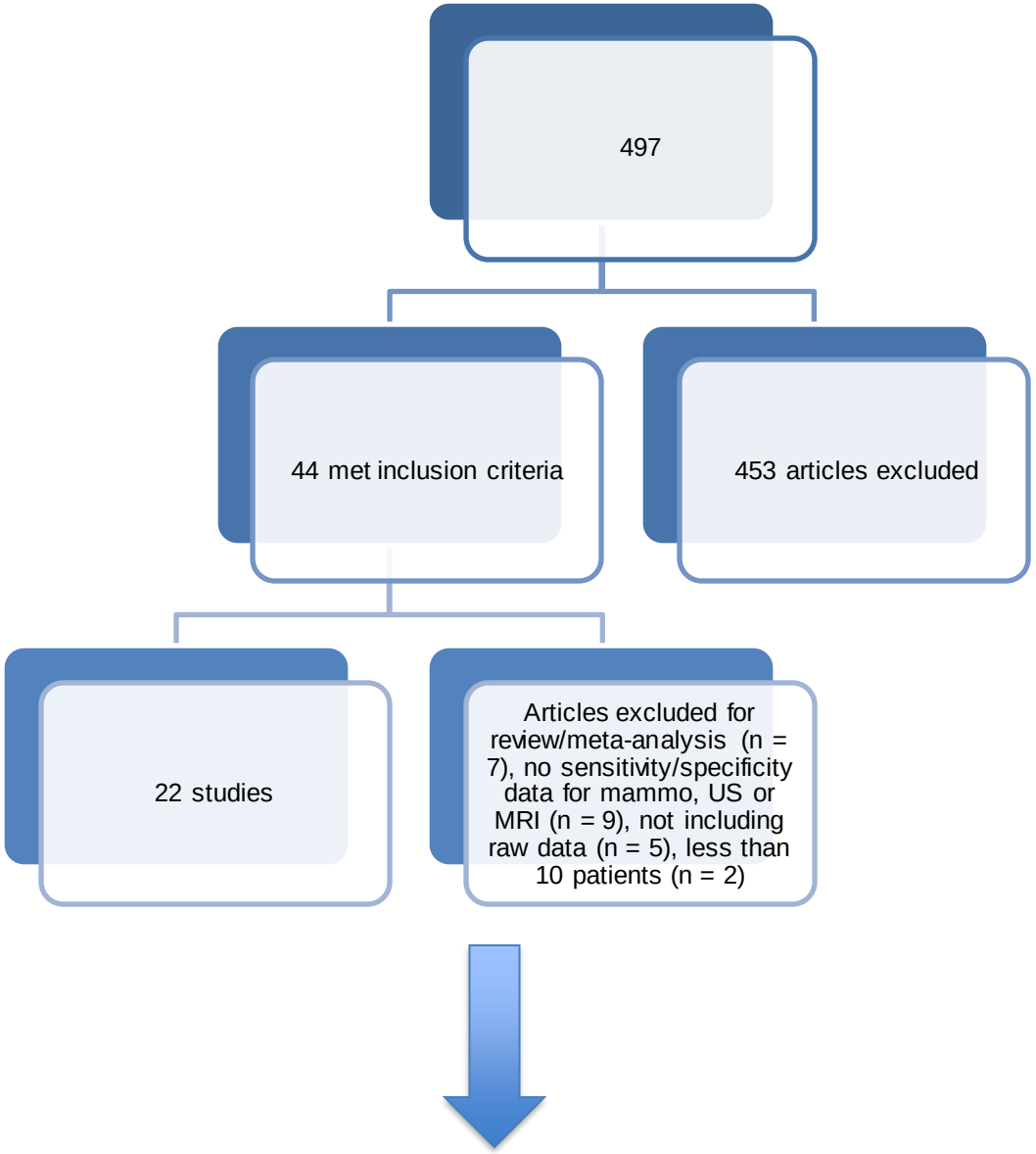

22 studies (N = 2454) patients with PND analyzed

MRI was significantly more sensitive in identifying malignancy compared to mammo, US and mammo + US.

Forest plot for true positive rate (sensitivity)

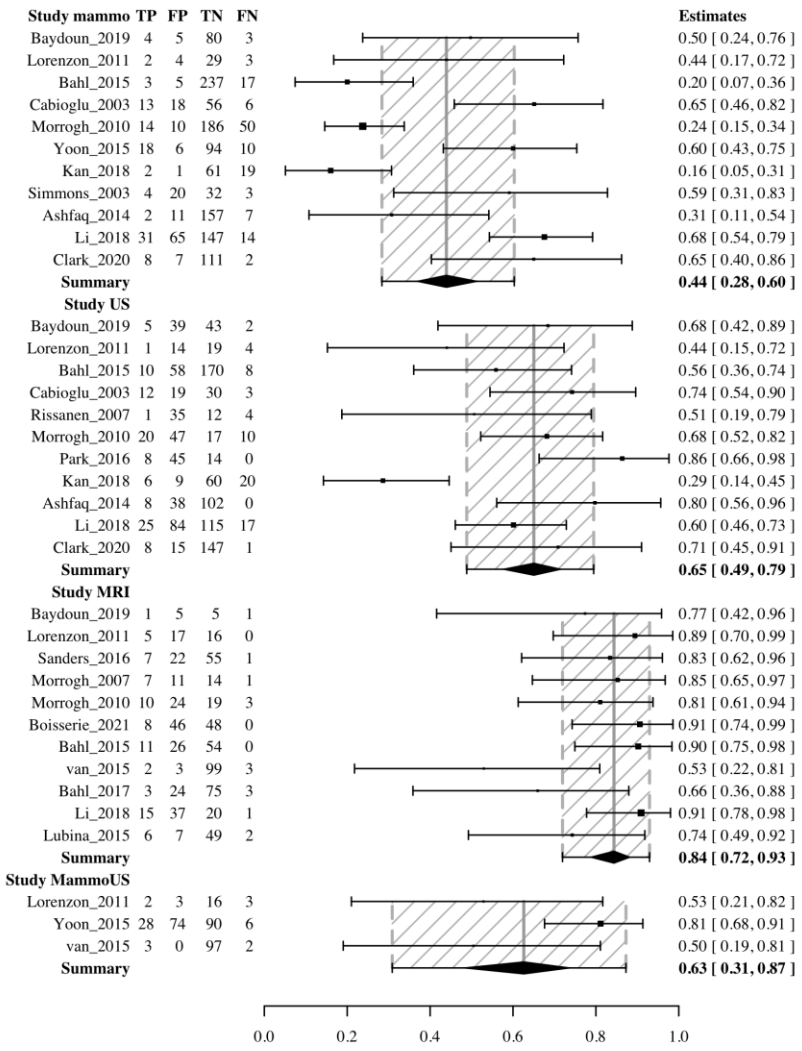

Mammo = 0.44

Ultrasound = 65%

Mammo+US = 63%

MRI = 84%

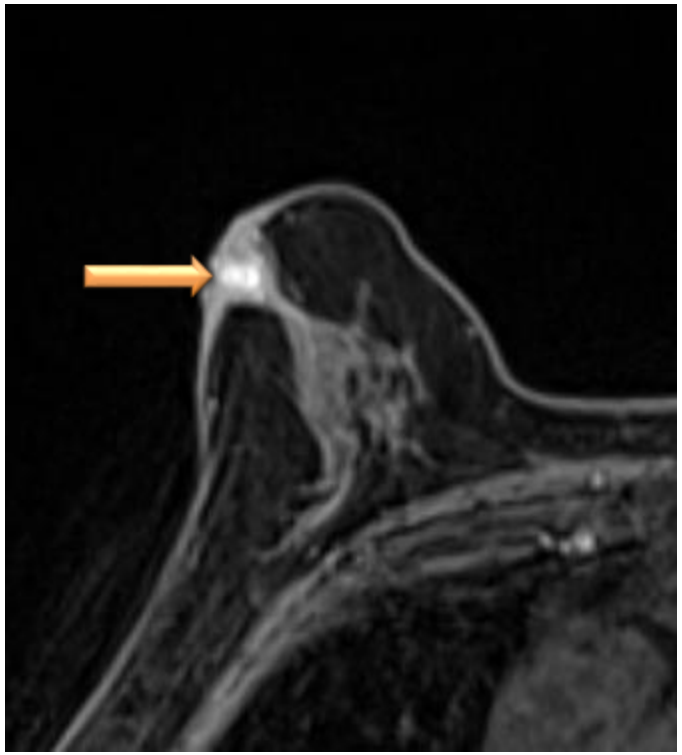

Mammography had the highest specificity for ruling in malignant lesions

Forest plot for true negative rate (specificity)

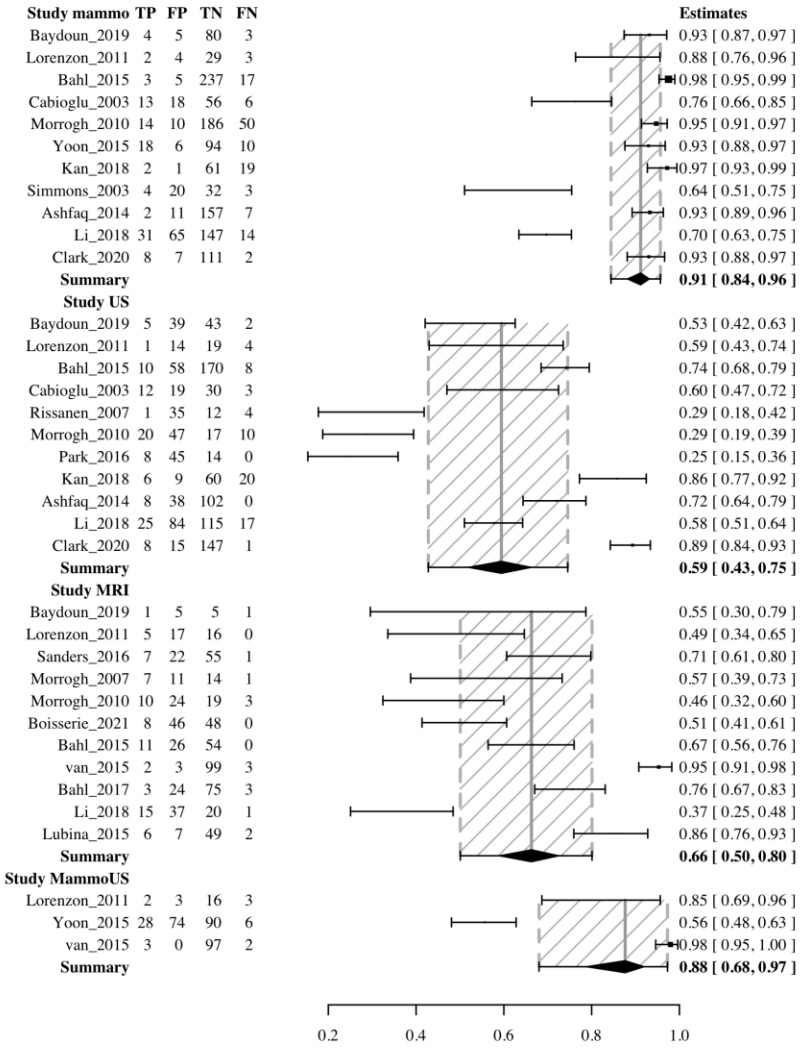

Mammo = 0.91

Ultrasound = 0.59

Mammo+US = 0.88

MRI = 0.66

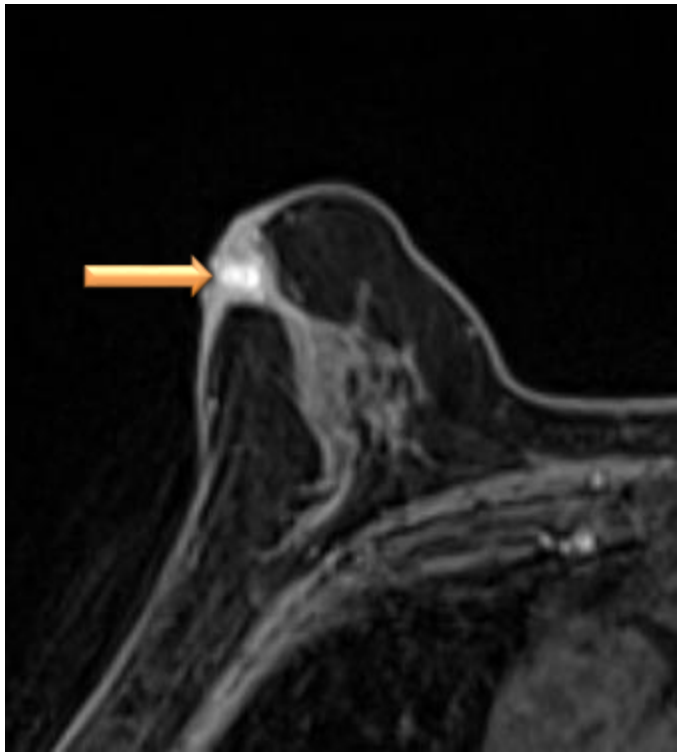

Diagnostic odds ratio (DOR)

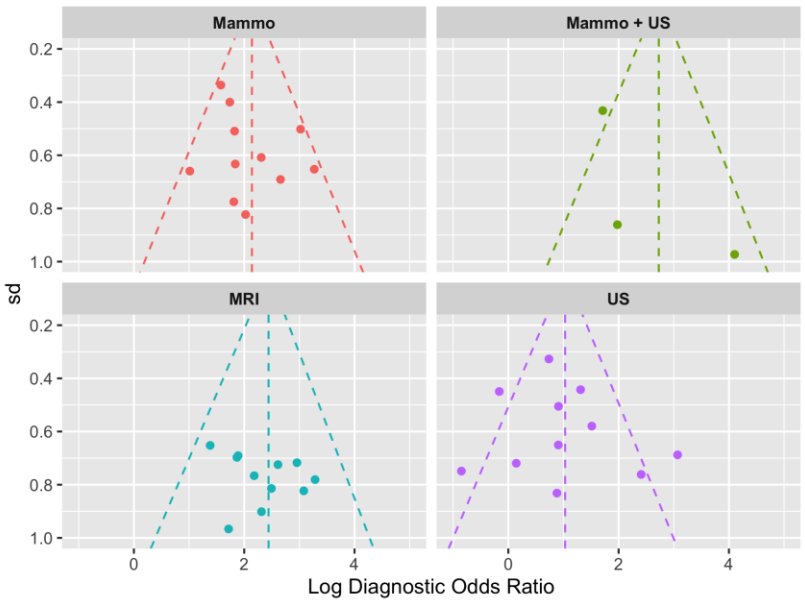

MRI had the highest DOR for detecting **malignancy** out of the other single modalities. The use of mammo and US together had similar DOR but was only based off three studies.

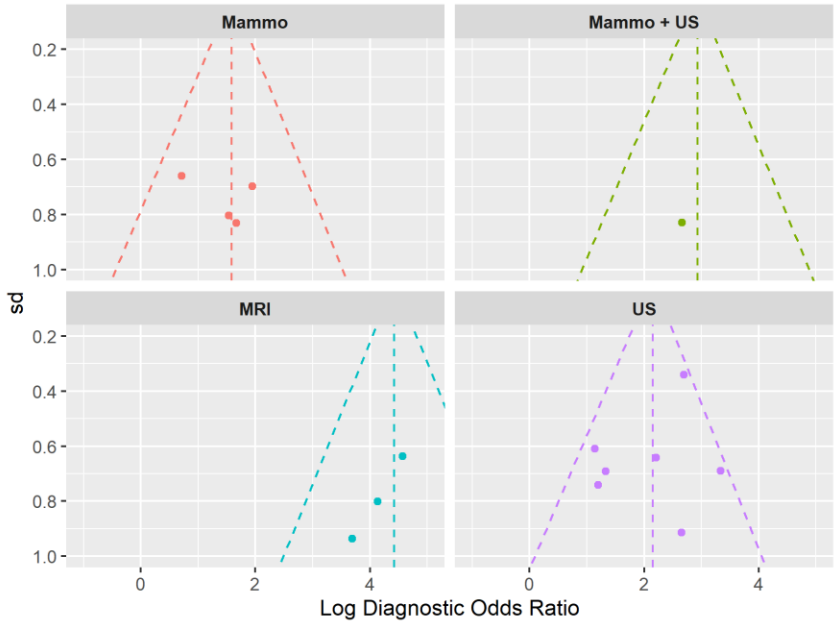

MRI had the highest DOR for detecting **any etiology** of pathologic nipple discharge at 4.42 compared to mammo (1.60), US (2.17) and mammo + US (2.92).

MRI had the highest area under the curve (AUC) to detect any PND etiology

AUC for diagnosing malignancy

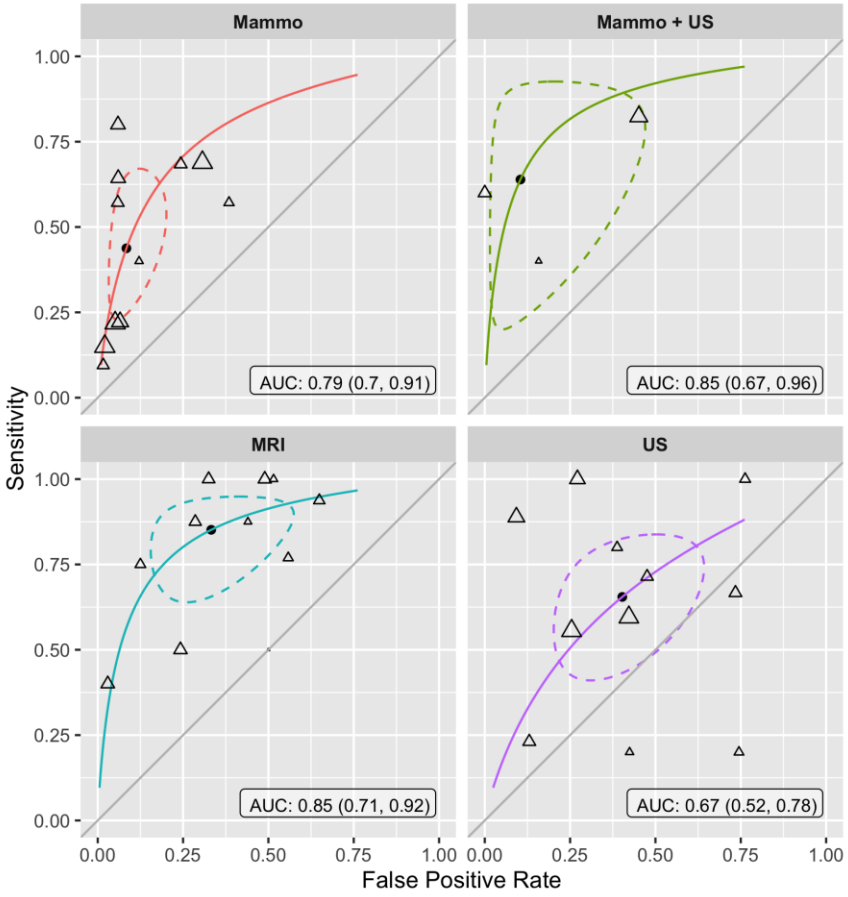

AUC for diagnosing any PND etiology

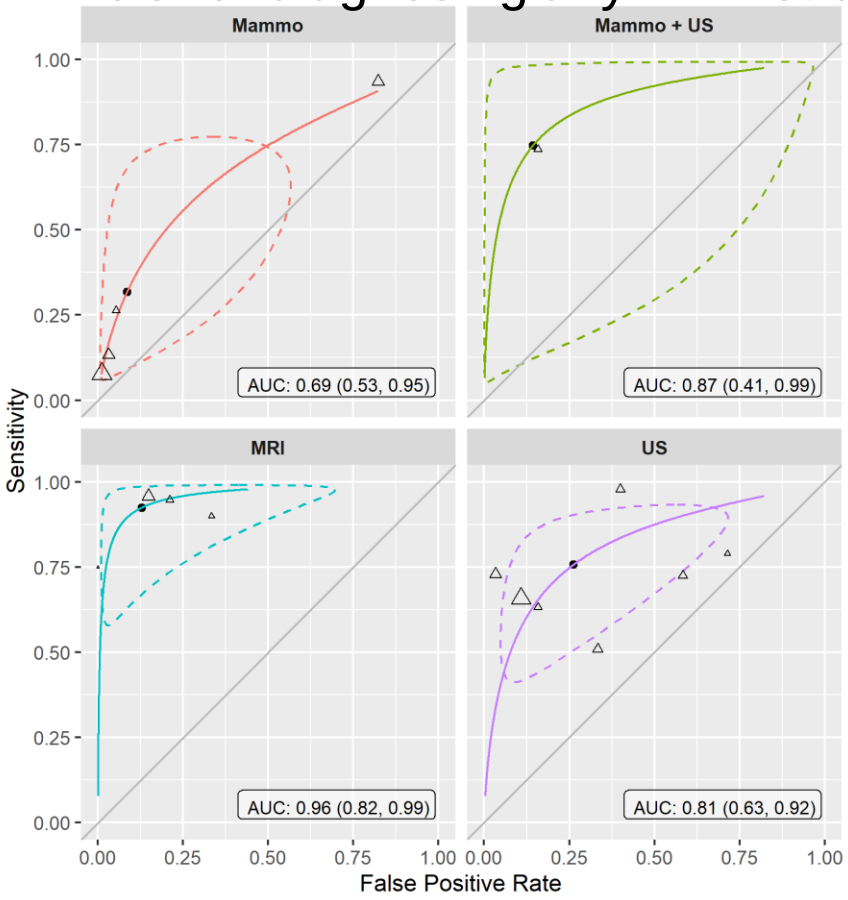

AUC score interpretation in assessing diagnostic accuracy:
0.6 to 0.7 – poor
0.7 to 0.8 – fair
0.8 to 0.9 – good
0.9 – excellent

Curved lines demonstrate the precision of all the studies

Suggested evidence-based diagnostic imaging algorithm in patients with nipple discharge

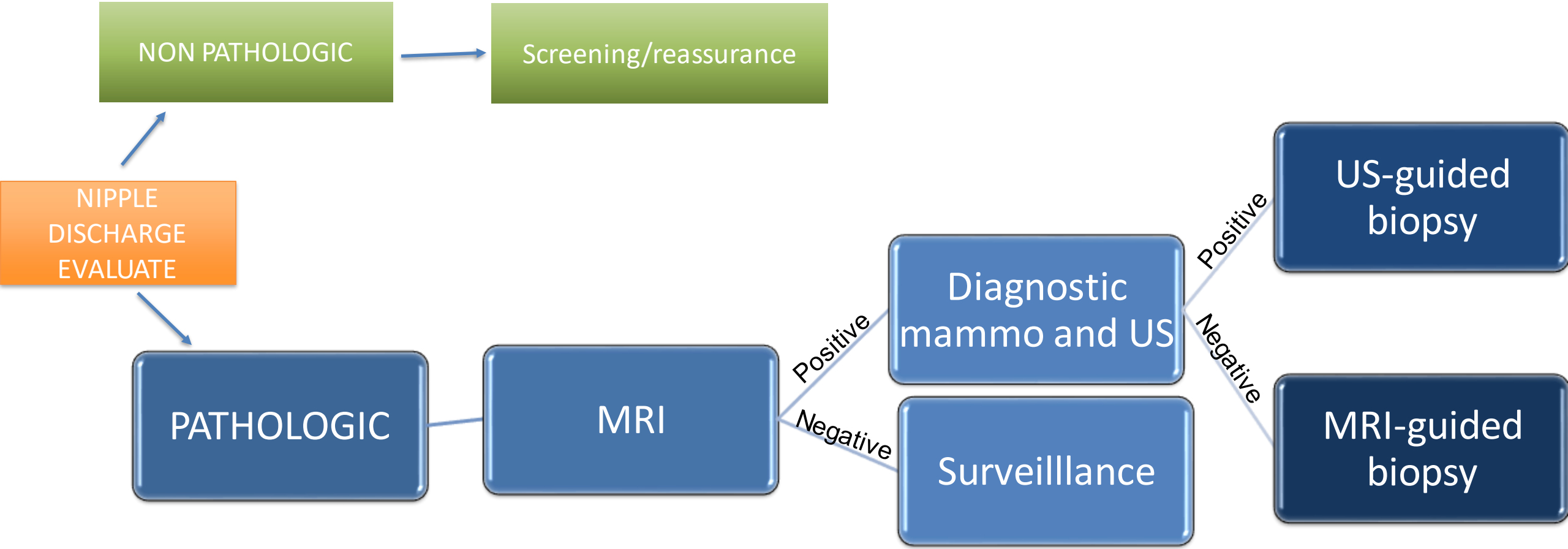

Conclusion

- MRI is the most accurate imaging modality for detection of breast cancer and benign lesions in patients presenting with pathological nipple discharge.
- Our analysis supports the use of MRI as the initial imaging test to be conducted in this patient population.
- It is reasonable to offer the patient reassurance and elect for surveillance as opposed to surgical evaluation in the setting of a negative MRI.

Limitations

- PND mainly in patients 40 years and older.
- Ultrasound may be more appropriate for women younger than 40.
- Multiple papers had differing criteria for what constitutes pathologic discharge.
- Multiple studies excluded patients with positive mammogram and/or US results.

References

Baydoun S, Gonzalez P, Whitman GJ, Dryden M, Xi Y, Dogan B. Is Ductography Still Warranted in the 21st century? Breast J 2019; 25:654-662

Expert Panel on Breast I, Lee SJ, Trikha S, et al. ACR Appropriateness Criteria((R)) Evaluation of Nipple Discharge. J Am Coll Radiol 2017; 14:S138-S153

Patel BK, Ferraro C, Kosiorek HE, et al. Nipple Discharge: Imaging Variability Among U.S. Radiologists. AJR Am J Roentgenol 2018; 211:920-925

Bahl M, Baker JA, Greenup RA, Ghate SV. Diagnostic Value of Ultrasound in Female Patients With Nipple Discharge. AJR Am J Roentgenol 2015; 205:203-208

Any Questions? Contact me at Joshua.Amaya@utsouthwestern.edu **Twitter: @JoshAmaya14**