Safety and Cost-Effectiveness of Image-Guided Gastrostomy Tube Placement as an Outpatient Procedure

EMORY UNIVERSITY SCHOOL OF MEDICINE

Ryan S. Dolan MD, Richard Duszak Jr MD, Janice Newsome MD, Zachary L. Bercu MD, Nima Kokabi MD

ACR Annual Meeting
Washington DC
May 2019

Financial Disclosures

Authors: Ryan S. Dolan MD, Richard Duszak Jr MD, Janice Newsome MD, Zachary L. Bercu MD, Nima Kokabi MD

Relevant Disclosures: None

Background

EMORY UNIVERSITY SCHOOL OF MEDICINE

Gastrostomy Tubes

- Purpose : Nutritional support, Gastric decompression

- How: Surgical, Endoscopic, Radiologic (Image-guided)

- Post-Procedure: Traditionally monitored as an inpatient with advancement of diet starting 12-24 hours post procedure. Recently, expedited feeding protocols (advance diet after 4-6 hours NPO) have been introduced, particularly following endoscopically-placed tubes.

Background

EMORY UNIVERSITY SCHOOL OF MEDICINE

Institution of an expedited feeding protocol following image-guided placement:

- Low intermittent wall suction for 1 hour
- Remain NPO for 4 hours post placement, then start feeding:
  - If tube feeding: Start feeding by slow gravity for 45-60 minutes then slowly increase over next 24 hours
  - If still eating: Start clear liquids per mouth after 4 hours and clamp tube for 2 hours after ingestion
- Discharge if 1) no signs of peritonitis, 2) pain < 4/10, and 3) afebrile and hemodynamically stable

Purpose

To assess the safety and cost-effectiveness of image-guided percutaneous gastrostomy tube placement as an outpatient procedure with an expedited feeding protocol

Methods

Retrospective review of 33 patients who underwent percutaneous gastrostomy tube placement by “push” technique under fluoroscopic guidance from January 2017 to March 2018

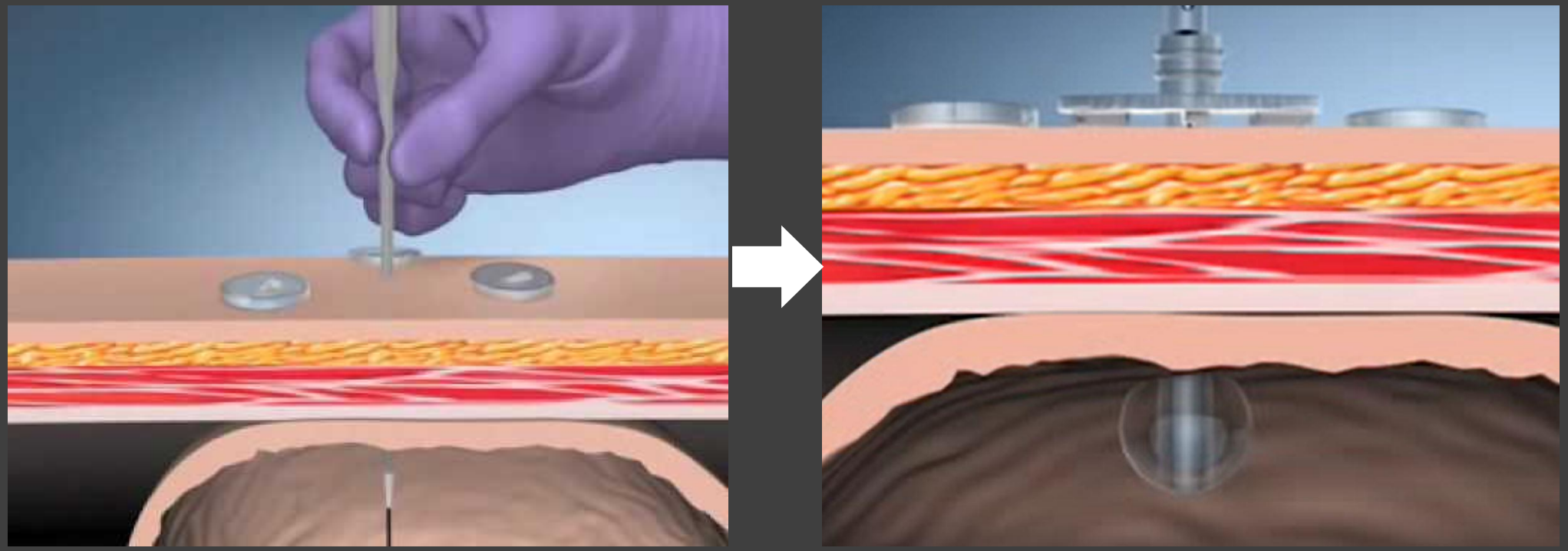

Courtesy: Kimberly Clark

Methods

EMORY UNIVERSITY SCHOOL OF MEDICINE

1. Compared complications within 3 months of placement:
    1) All-cause mortality
    2) Mortality related to gastrostomy tube
    3) Significant pain (requiring extra narcotic use or ER visit)
    4) Significant bleeding (requiring IR inspection, intervention, or ER visit)
    5) Aspiration pneumonia (possibly related to tube)
    6) Gastrostomy site cellulitis requiring antibiotic treatment
    7) Surgical consultation related to tube
    8) Tube failures (broken, inadvertent dislodgement)

2. Compared combined insurer and patient payments to the hospital

Results

Outpatient Procedure: N=25

- Age 65.3 ± 8.0 years, 20% female
- Followed expedited feeding protocol (NPO 4 hours)
- Discharged home after 4+ hours

Inpatient Procedure: N=8

- Age 61.3 ± 13.6 years, 63% female
- Followed traditional feeding protocol (NPO 24 hours)
- Discharged home after 24+ hours

Results

EMORY UNIVERSITY SCHOOL OF MEDICINE

	OUTPATIENT (N=25)	INPATIENT (N=8)	P
Complications	2 (8%)	2 (25%)	**0.20**
	(1 with cellulitis requiring antibiotic treatment, 1 with aspiration pneumonia possibly related to G tube)	(2 with cellulitis requiring antibiotic treatment)	
Total insurer and patient payments	$2,193 (per patient)	$2,701 (per patient)	**0.52**

Conclusions

EMORY UNIVERSITY SCHOOL OF MEDICINE

Outpatient placement of radiologic percutaneous gastrostomy tubes with an expedited feeding protocol is **NOT** associated with higher complication rates and may be a more cost-effective alternative to an inpatient hospital stay. Further prospective study and cost-effective analysis are warranted.

Thank You

EMORY UNIVERSITY SCHOOL OF MEDICINE

Contact:

Ryan Dolan

ryan.dolan@emory.edu