



# US LI-RADS<sup>®</sup> v2017 CORE

[Screening](#) or [surveillance](#) US in [patient at high risk for HCC](#)

## US category

US-1	Negative
US-2	Subthreshold
US-3	Positive

Category	Concept	Definition
US-1 Negative	No US evidence of HCC	No <a href="#">observation</a> <b>OR</b> Only definitely benign observation(s)
US-2 Subthreshold	<a href="#">Observation</a> (s) detected that may warrant <a href="#">short-term US surveillance</a>	<a href="#">Observation</a> (s) < 10 mm in diameter, not definitely benign
US-3 Positive	<a href="#">Observation</a> (s) detected that may warrant multiphase contrast-enhanced imaging	<a href="#">Observation</a> (s) ≥ 10 mm in diameter, not definitely benign <b>OR</b> New thrombus in vein

## US visualization score

A	No or minimal limitations
B	Moderate limitations
C	Severe limitations

Score	Concept	Examples
A. No or minimal limitations	Limitations if any are unlikely to meaningfully affect sensitivity	Liver homogeneous or minimally heterogeneous Minimal beam attenuation or shadowing Liver visualized in near entirety
B. Moderate limitations	Limitations may obscure small masses	Liver moderately heterogeneous Moderate beam attenuation or shadowing Some portions of liver or diaphragm not visualized
C. Severe limitations	Limitations significantly lower sensitivity for focal liver lesions	Liver severely heterogeneous Severe beam attenuation or shadowing Majority (>50%) of liver not visualized Majority (>50%) of diaphragm not visualized

# Table of Contents

		<b>Pages</b>
<b>Overview</b>	What is US LI-RADS®?	<a href="#"><u>2</u></a>
	US LI-RADS® Algorithm	<a href="#"><u>3</u></a>
<b>Algorithm</b>	Step 1. Assign US LI-RADS® Category	<a href="#"><u>4</u></a>
	Step 2. Apply Tiebreaking Rule if Needed	<a href="#"><u>6</u></a>
	Step 3. Assign US LI-RADS® Visualization Score	<a href="#"><u>7</u></a>
	Step 4. Final Check	<a href="#"><u>8</u></a>
<b>Technique</b>	US LI-RADS® Technical Recommendations	<a href="#"><u>9</u></a>
	US LI-RADS® Recommended US Views	<a href="#"><u>10</u></a>
<b>Definitions &amp; Criteria</b>	Observation	<a href="#"><u>12</u></a>
	US-1: Negative	<a href="#"><u>13</u></a>
	US-2: Subthreshold	<a href="#"><u>14</u></a>
	US-3: Positive	<a href="#"><u>15</u></a>
<b>Management</b>	US LI-RADS® Management Summary	<a href="#"><u>17</u></a>
<b>US LI-RADS® Key Concepts</b>	US LI-RADS® Key Concepts Overview	<a href="#"><u>18</u></a>
	HCC Screening or Surveillance Tests vs. Diagnostic Tests	<a href="#"><u>19</u></a>
	HCC Screening or Surveillance Tests vs. Diagnostic Tests LI-RADS® Terminology	<a href="#"><u>20</u></a>
<b>LI-RADS® Population</b>	Appropriate Population for Application of US LI-RADS®	<a href="#"><u>21</u></a>
	Appropriate Population for Application of CT/MRI and CEUS-LI-RADS®	<a href="#"><u>22</u></a>
	Differences in the US LI-RADS® vs. CT/MRI and CEUS LI-RADS® Populations	<a href="#"><u>23</u></a>
<b>Gaps in Knowledge and Future Directions</b>		<a href="#"><u>24</u></a>
<b>US LI-RADS® Manual (with References) (pending)</b>		



# What is US LI-RADS®?

## The **U**ltrasound **L**iver **I**maging **R**eporting **A**nd **D**ata **S**ystem (US LI-RADS) is:

- A standardized system for imaging technique, interpretation, reporting, and data collection for [screening](#) or [surveillance](#) ultrasound exams in [patients at risk for developing HCC](#).
- A dynamic document, to be expanded and refined as knowledge accrues and in response to user feedback.
- Designed to improve communication, patient care, education, and research.
- Supported and endorsed by the American College of Radiology (ACR).
- Developed by a consortium of diagnostic radiologists and hepatologists with expertise in hepatobiliary ultrasound, with input from and approval by the LI-RADS Steering Committee.

## US LI-RADS may be used by:

- Community and academic radiologists
- Radiologists in training
- Other health care professionals providing care to patients with liver disease
- Researchers

## US LI-RADS includes:

- A lexicon of controlled terminology
- An illustrative atlas
- Reporting guidelines
- Educational material

## US LI-RADS US requires two types of assessments, both pertaining to the whole liver rather than specific nodules or other observations:

- US category
- US visualization score

The **US Category** summarizes the main results and helps determine the most appropriate follow-up. Three scores are possible:

- US-1 Negative
- US-2 Subthreshold
- US-3 Positive

The **US Visualization Score** reflects technical or other factors that may affect liver visualization or nodule detection. This information helps to communicate the expected level of sensitivity of the screening exam for HCC detection in an individual patient. Data on visualization scores may be used for quality assurance and to inform future refinements of LI-RADS and LI-RADS-related management guidelines. Three visualization scores are possible:

- A. No or minimal limitations
- B. Moderate limitations
- C. Severe limitations

# US LI-RADS® Algorithm

The next five slides summarize the LI-RADS Algorithm for assigning the US Category and US Visualization Scores.

---

Remember that the algorithm applies only to patients at risk for developing HCC. See pages [21](#) to [22](#) for details.

# Step 1. Assign US LI-RADS® Category

[Screening](#) or [surveillance](#) US in patient at high risk for HCC <sup>a</sup>

US category

- US-1 Negative
- US-2 Subthreshold
- US-3 Positive

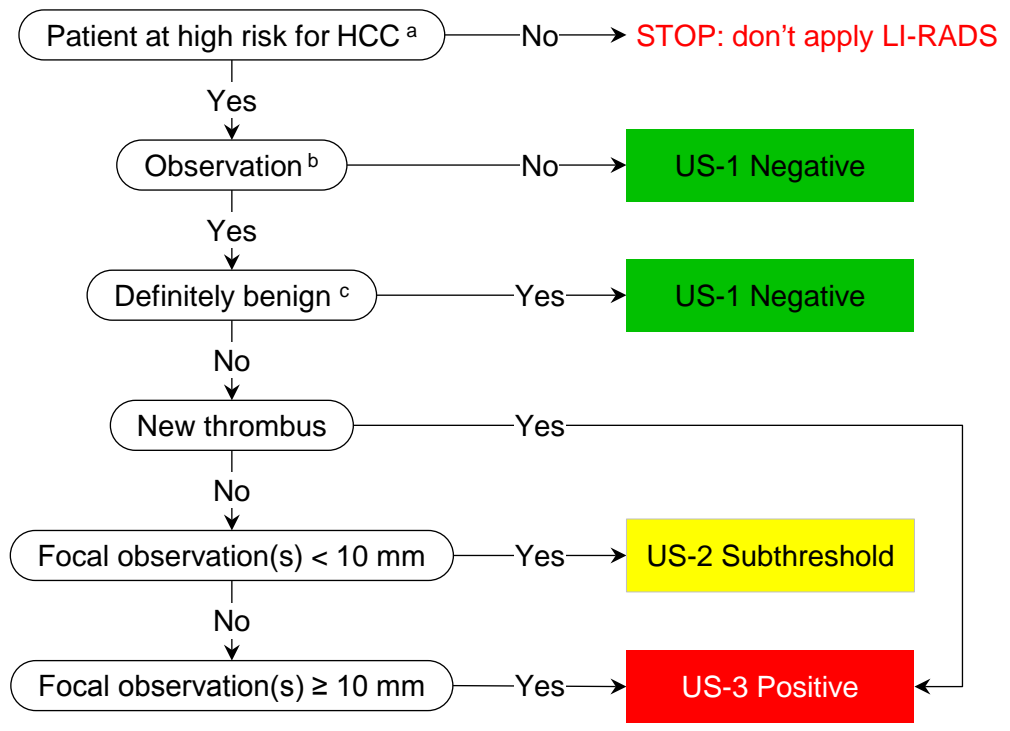
Category	Concept	Definition
US-1 Negative	No US evidence of HCC	No <a href="#">observation</a> <b>OR</b> Only definitely benign observation(s)
US-2 Subthreshold	<a href="#">Observation</a> (s) detected that may warrant <a href="#">short-term US surveillance</a>	<a href="#">Observation</a> (s) < 10 mm in diameter, not definitely benign
US-3 Positive	<a href="#">Observation</a> (s) detected that may warrant multiphase contrast-enhanced imaging	<a href="#">Observation</a> (s) ≥ 10 mm in diameter, not definitely benign <b>OR</b> New thrombus in vein

## Footnotes

- 
- a. Patient at high risk for HCC
- In general, this includes patients with cirrhosis of any cause or with chronic hepatitis B even in absence of cirrhosis.
  - See pages [21-22](#) for details
- 
- b. Observation
- Distinctive area compared to background liver
  - See page [12](#) for details
- 
- c. Definitely benign observation
- Examples: Simple cyst, focal fat sparing around gallbladder, previously confirmed hemangioma

# Step 1. Assign US LI-RADS® Category

(Same content as prior slide, alternative display)



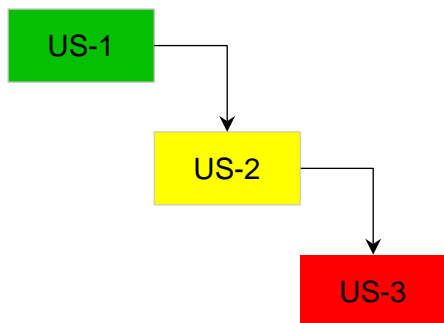
## Footnotes

- a. Patient at high risk for HCC
  - In general, this includes patients with cirrhosis of any cause or with chronic hepatitis B even in absence of cirrhosis.
  - See pages [21-22](#) for details
- b. Observation
  - Distinctive area compared to background liver
  - See page [12](#) for details
- c. Definitely benign observation
  - Examples: Simple cyst, focal fat sparing around gallbladder, previously confirmed hemangioma

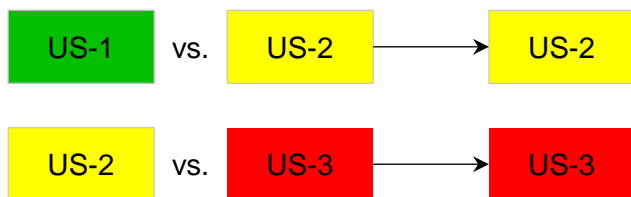


## Step 2. Apply Tiebreaking Rule<sup>a</sup> if Needed

If unsure between two categories, choose the one reflecting greater suspicion



Thus:



### Footnotes

a. Tie-breaking rule(s)

Rule(s) to assign a final single category when deciding between two categories

- For screening or surveillance exam (US LI-RADS)

Assign the category with a *higher degree of suspicion*.  
Rationale: In screening context, goal is to maximize sensitivity.

- For diagnostic exam (CEUS LI-RADS or CT/MRI LI-RADS)

Assign the category with a *lower degree of certainty*.  
Rationale: In diagnostic (confirmatory) context, emphasis is on specificity.



# Step 3. Assign US LI-RADS® Visualization Score

[Screening](#) or [surveillance](#) US in patient at high risk for HCC <sup>a</sup>

US visualization score

A	No or minimal limitations
B	Moderate limitations
C	Severe limitations

Score	Concept	Examples
<a href="#">A. No or minimal limitations</a>	Limitations if any are unlikely to meaningfully affect sensitivity	Liver homogeneous or minimally heterogeneous Minimal beam attenuation or shadowing Liver visualized in near entirety
<a href="#">B. Moderate limitations</a>	Limitations may obscure small masses	Liver moderately heterogeneous Moderate beam attenuation or shadowing Some portions of liver or diaphragm not visualized
<a href="#">C. Severe limitations</a>	Limitations significantly lower sensitivity for focal liver lesions	Liver severely heterogeneous Severe beam attenuation or shadowing Majority (>50%) of liver not visualized Majority (>50%) of diaphragm not visualized

## Footnotes

a. Patient at high risk for HCC

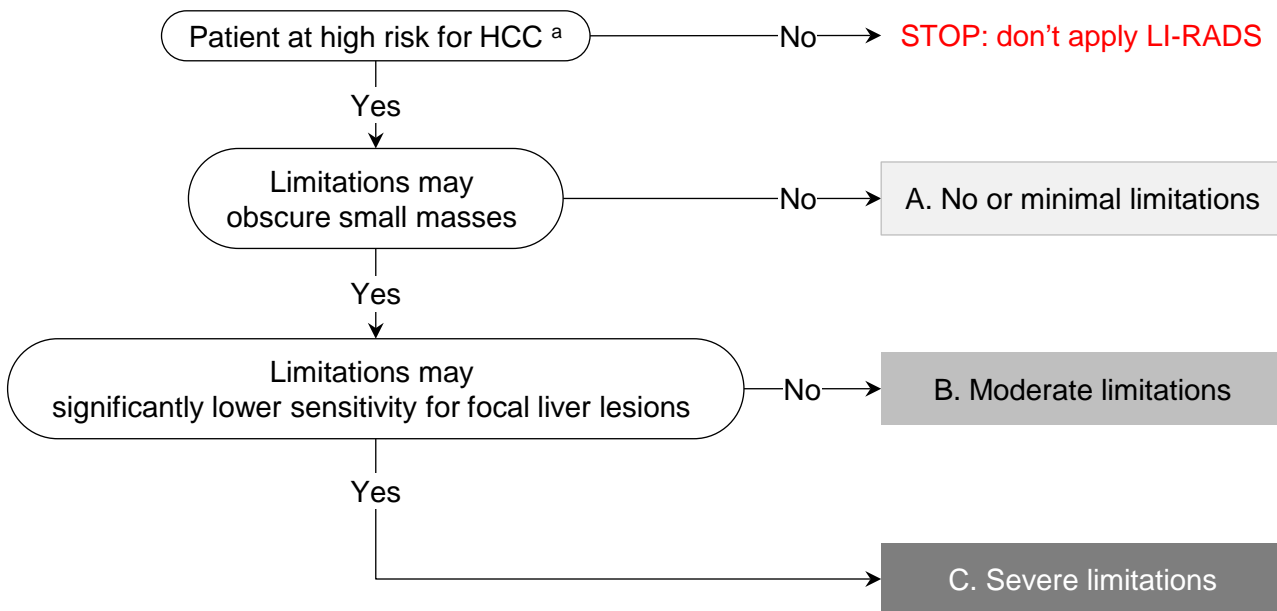
- In general, this includes patients with cirrhosis of any cause or with chronic hepatitis B even in absence of cirrhosis.
- See pages [21-22](#) for details





# Step 3. Assign US LI-RADS® Visualization Score

(Same content as prior slide, alternative display)



## Step 4. Final Check

After Steps 1, 2, and 3 –

Ask yourself if the assigned US category and visualization score seem reasonable and appropriate

**If YES:** You are done.

**If NO:** Assigned US category and/or visualization score may be inappropriate, so reevaluate.

### Footnotes

a. Patient at high risk for HCC

- In general, this includes patients with cirrhosis of any cause or with chronic hepatitis B even in absence of cirrhosis.
- See pages [21-22](#) for details.



# US LI-RADS® Technical Recommendations

## Overview

Screening ultrasound (US) technique should be in accordance with ACR Practice Parameter and Technical Standard for Performance of Ultrasound of the Abdomen and Retroperitoneum.

- [See \*ACR Practice Parameter and Technical Standards for details.\*](#)

---

## General technical considerations

Compare with prior exams whenever possible.

Use a standard protocol, as this may improve reproducibility and facilitate comparison.

Specific factors that may result in incomplete imaging of liver include:

- Large patient body habitus or inability to cooperate
- Limited acoustic window
- Parenchymal heterogeneity
- Reduced beam penetration

Suggestions to improve image quality and visualization of entire liver:

- Instruct patient to be NPO for 4-6 hours prior to exam
- Adjust patient positioning, inspiration level, and acoustic window
- Apply adequate probe pressure against abdominal wall
- Adjust image settings (e.g. transducer presets, pulse frequency, harmonics)

---

## Assessment of liver, biliary system, and portal veins

Acquire representative transverse and longitudinal grayscale (B-mode) images through entire liver to evaluate for cirrhotic morphologic changes and focal or diffuse observations.

- Optional: cine sweeps through liver
- [See page 10 for suggested views.](#)

Document patency of main portal vein with grayscale and color Doppler.

- Optional: color Doppler of right and left portal veins, and hepatic veins; spectral Doppler of main portal vein to assess waveform, velocity, and flow direction

Evaluate gallbladder and bile ducts.

---

## Documentation of liver observations

Obtain grayscale and color/power Doppler images in transverse and longitudinal views.

- Optional: cine sweeps through liver observations to permit more confident characterization

Record:

- Size of each focal liver observation in 3 dimensions
- Involved lobe and Couinaud segment if possible
- Proximity to or involvement of vessels, liver capsule, or bile ducts
- Arterialized flow within any occluded vein, which would indicate tumor in vein

---

## Other optional assessments and procedures

Record spleen size (required component of a complete abdominal US exam although optional for focused HCC screening/surveillance exam of liver).

Document presence and degree of ascites.

Use linear transducer to depict surface nodularity and any subcapsular observations.

Save cine loops to facilitate retrospective image evaluation.



# US LI-RADS® Recommended US Views

## Longitudinal images

Recommended views	<p>Left lobe:</p> <ul style="list-style-type: none"> <li>• left of midline</li> <li>• at midline; include proximal abdominal aorta, celiac artery, and SMA</li> <li>• with IVC; include caudate lobe, MPV, and pancreatic head</li> <li>• with left portal vein</li> </ul> <p>Right lobe:</p> <ul style="list-style-type: none"> <li>• with gallbladder</li> <li>• with right kidney</li> <li>• including right hemidiaphragm and adjacent pleural space</li> <li>• far lateral</li> </ul> <p>Main portal vein; include grayscale and color Doppler Common bile duct at porta hepatis; include diameter measurement</p>
Optional views	<p>Color Doppler of the right and left portal veins, and hepatic veins Spectral Doppler of main portal vein to assess waveform, velocity, and flow direction</p>

## Transverse images

Recommended views	<p>Dome with hepatic veins; include entire right and left lobe with medial and lateral liver edges (on separate images as needed)</p> <p>Left lobe:</p> <ul style="list-style-type: none"> <li>• with left portal vein</li> <li>• falciform ligament to evaluate for the presence of patent paraumbilical vein</li> </ul> <p>Main portal vein bifurcation</p> <p>Right lobe:</p> <ul style="list-style-type: none"> <li>• with right portal vein</li> <li>• with main portal vein</li> <li>• with gallbladder</li> <li>• with right kidney</li> <li>• near liver tip</li> </ul>
Optional views	<p>Color Doppler view of additional vascular structures</p>

## Cine loops

Recommended views	—
Optional views	<p>Longitudinal and transverse cine sweeps of left and right lobes, including as much hepatic parenchyma as possible</p>

Recommended views can be obtained in any order per institutional protocol. Additional views of focal observations should be obtained as needed. Additional anatomical and Doppler measurements may be included per institutional preferences and needs.



# US LI-RADS® Definitions and Category Criteria

The next four slides review the definitions and criteria for

- LI-RADS Observation
- US-1 Negative
- US-2 Subthreshold
- US-3 Positive

The slides present the same material as before but with a list-view display. These are intended for users who prefer such a display.



## Observation

Distinctive area compared to background liver

### Examples:

- Simple cyst
- Solid hypoechoic, hyperechoic, or mixed echogenicity nodule
- Thrombus in vein



## US-1: Negative

**Concept:**

No US evidence of HCC

**Definition:**

No observation  
OR  
Only definitely benign observation(s)

**Examples:**

- Simple cyst(s)
- Focal hepatic fat sparing around gallbladder fossa
- Previously confirmed hemangioma(s)



## US-2: Subthreshold

**Concept:**

Observation(s) detected that may warrant short-term US surveillance

**Definition:**

Observation(s) < 10 mm in diameter, not definitely benign

**Examples:**

- Solid nodule (any echogenicity) < 10 mm



## US-3: Positive

### Concept:

Observation(s) detected that warrant characterization with multi-phasic contrast-enhanced imaging

### Definition:

Focal observation(s)  $\geq$  10mm in diameter, not definitely benign  
OR  
New thrombus in vein

### Examples:

- Solid nodule (any echogenicity)  $\geq$  10 mm
- Parenchymal distortion <sup>a</sup>
- Thrombus in vein, not previously confirmed to be benign

## Footnotes

### a. Parenchymal distortion

Parenchymal area  $\geq$ 10 mm with one or more of the following manifestations:

- Ill-defined area of heterogeneity
- Refractive edge shadows
- Loss of normal hepatic architecture

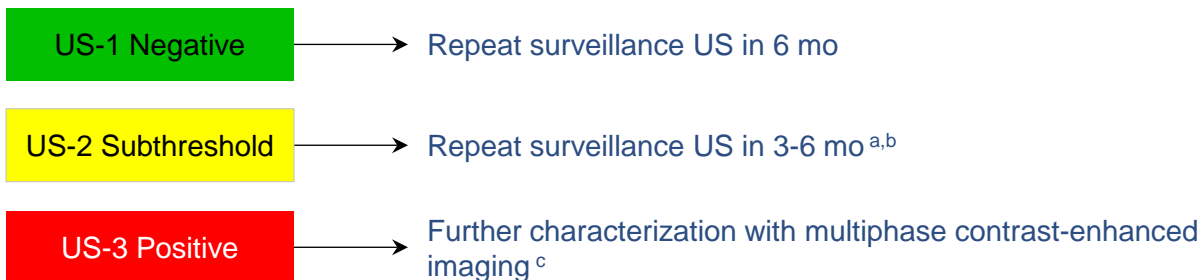

# US LI-RADS® Management

The next slide summarizes the suggested follow-up for patients based on the US LI-RADS Category. Note that the US Visualization Score is not used to determine follow up.



# US LI-RADS® Management Summary



## Footnotes

---

a. For observations < 10 mm in size (US-2 Subthreshold), follow-up in 3-6 months is suggested. If observation does not show growth over a 2-year period, observation can be considered to be benign and study can be categorized as US-1 Negative.

---

b. This is concordant with 2010 AASLD recommendations.

---

c. Multiphase imaging may include multiphase contrast-enhanced CT, MR, or CEUS.



# US LI-RADS® Key Concepts

US LI-RADS is a standardized system for imaging technique, interpretation, reporting, and data collection for **screening** or **surveillance ultrasound exams** in patients at risk for developing HCC.

This system is complementary to CT/MRI LI-RADS and to CEUS LI-RADS, which are standardized systems for technique, interpretation, reporting, and data collection for **contrast-enhanced diagnostic exams** in patients at risk for developing HCC .

---

The following slides review:

- Concepts about “HCC screening and surveillance tests” vs. “HCC diagnostic tests”
- The appropriate population for application of US LI-RADS
- The appropriate population for application of CT/MRI LI-RADS and CEUS LI-RADS
- Differences in the US LI-RADS vs. CT/MRI LI-RADS and CEUS LI-RADS populations
- Gaps in knowledge and future directions



# HCC Screening or Surveillance Tests vs. Diagnostic Tests

## HCC clinical practice guidelines classify imaging modalities as

- Screening or surveillance tests **OR**
- Diagnostic tests

**Screening or surveillance tests** are intended to *detect* HCC in defined populations.

- **Screening** refers to the application of an imaging or laboratory test to population at risk for developing disease. It aims to detect prevalent disease (e.g., HCC present at time of initial testing).
- **Surveillance** refers to repeated application of the screening test. It aims to detect incident disease (e.g., HCC that develops after initial testing).
- Thus, in a **screening and surveillance program**, the first (baseline) exam is considered a screening test. Subsequent (follow-up) exams are considered surveillance tests.
- Ideally, screening or surveillance tests should have high sensitivity, wide availability, low cost, and high patient acceptance.
- The most common imaging modality used for HCC screening or surveillance is **unenhanced US**. In select patients, other imaging modalities such CT or MRI may be used for this purpose. Circulating biomarkers such as serum alpha fetoprotein may be used for screening or surveillance in combination with imaging tests.
- US LI-RADS addresses the use of US for screening or surveillance. It does not address the possible use of other modalities or biomarkers for screening or surveillance.

**Diagnostic tests** are used to further characterize positive screening or surveillance tests or to characterize incidentally detected observations. Similar to screening and surveillance, the accuracy of diagnostic tests relies on the pre-test probability of disease. Hence, diagnostic algorithms should be applied only in high-risk populations.

- Ideally, diagnostic tests should have high specificity so the presence of HCC can be confirmed.
- In North America, the imaging modalities used most commonly for HCC diagnosis are **multiphase contrast-enhanced CT and MRI**. These modalities cover the entire liver and assess the extent (stage) of HCC.
- Another modality used for HCC diagnosis is **contrast-enhanced ultrasound (CEUS)**. This modality typically permits detailed characterization of a limited number of targeted observations but it may not reliably visualize the entire liver; hence, it is suitable for diagnosis but not usually for staging.
- Multiphase imaging is a requirement for HCC diagnosis; hence, single-phase imaging exams are not considered diagnostic tests for HCC. CT/MRI LI-RADS and CEUS LI-RADS address the use of the corresponding modalities for diagnosis.

## The distinction between screening or surveillance vs. diagnosis may be blurred.

In some radiology practices, multiphase contrast-enhanced imaging exams are done for screening or surveillance. In these instances, the same modality serves as the screening or surveillance test as well as the diagnostic test.

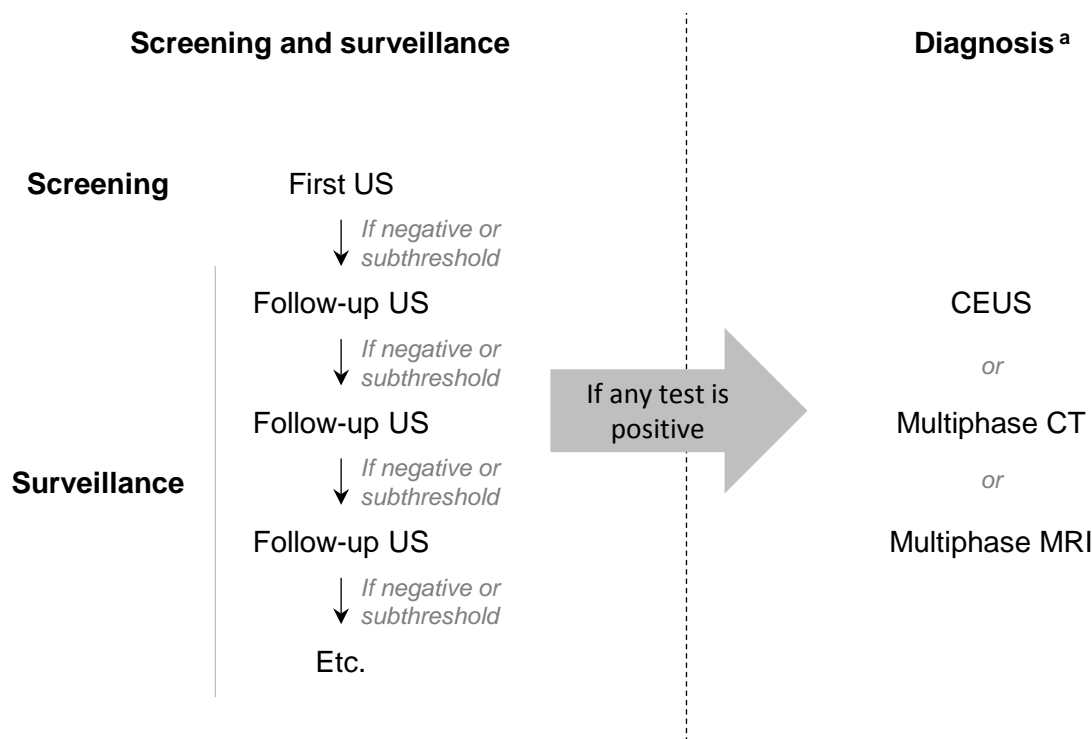


# HCC Screening or Surveillance Tests vs. Diagnostic Tests

## LI-RADS® Terminology

**LI-RADS adopts the screening and surveillance vs. diagnosis terminology used by clinical practice guidelines**

LI-RADS refers to unenhanced US as a “screening or surveillance” test and refers to contrast-enhanced US, multiphase CT, and multiphase MRI as “diagnostic” tests to maintain concordance with clinical practice guidelines. The use of the terms “screening or surveillance” and “diagnostic” in this setting are intended to clarify the context in which these imaging modalities are used and are not intended to imply differing levels of quality or value between these modalities.



### Footnotes

a. LI-RADS does not recommend any particular imaging modality for diagnosis, because the optimal choice of modality for individual patients depends on multiple factors, including availability, local expertise, patient preference, clinical context, and other considerations.



# Appropriate population for application of US LI-RADS®

**US LI-RADS should be applied to patients undergoing US as part of a screening and surveillance program for HCC.**

Recommended screening and surveillance populations include:

- Patients with cirrhosis of any etiology
- Noncirrhotic HBV Asian male > 40
- Noncirrhotic HBV Asian female > 50
- Noncirrhotic African/North American Blacks with HBV
- Noncirrhotic HBV patients with family history of HCC

Depending on geographic region, patients may be enrolled in an HCC screening and surveillance program if they have any of the following:

- Adults with cirrhosis of any cause
- Some adults with chronic hepatitis B viral infection even in the absence of cirrhosis
- Some adults with chronic hepatitis C viral infection even in the absence of cirrhosis

See your regional HCC clinical practice guidelines for details <sup>a</sup>.

## Footnotes

a. [Regional HCC clinical practice guidelines \(include, but are not limited to, the following\)](#)

Region	Organization	Abbreviation
USA	American Association for the Study of Liver Diseases National Comprehensive Cancer Network	AASLD NCCN
Europe	European Association For The Study Of The Liver European Organisation for Research and Treatment of Cancer	EASL EORTC
Asia	Japan Society of Hepatology Asian Pacific Association for the Study of the Liver Korean Liver Cancer Study Group and the National Cancer Center	JSH APASL KLCSG-NCC



# Appropriate population for application of CT/MRI and CEUS LI-RADS®

**CT/MRI and CEUS LI-RADS should be applied to patients undergoing contrast-enhanced multiphase CT or MRI or contrast-enhanced US (CEUS) with any of the following inclusion and none of the following exclusion criteria:**

---

## **Inclusion:**

Patient has one of the following:

- Cirrhosis
- Chronic hepatitis B even in absence of cirrhosis
- Current or prior HCC even in absence of cirrhosis

## **Exclusion:**

Patient has any of the following:

- Cirrhosis due to a vascular disorder such as Budd-Chiari, hereditary hemorrhagic telangiectasia, or cardiac cirrhosis or cirrhosis due to congenital hepatic fibrosis.
  - Such disorders are associated with non-malignant nodules that may resemble HCC at imaging. Imaging usually does not provide 100% specificity for HCC in such patients.
- Pediatric patients
  - No criteria have been validated

## **Rationale for these inclusion and exclusion criteria:**

These criteria define the population in which, based on current knowledge, the pretest probability of HCC is sufficiently high and the pretest probability of lesions mimicking HCC is sufficiently low that an observation meeting HCC imaging criteria can be assumed reliably and confidently to be HCC.

---

## **Applying the inclusion and exclusion criteria:**

Exclusion criteria take precedence over inclusion criteria. Hence, the presence of a single exclusion criterion makes the use of LI-RADS inappropriate, regardless of the number of inclusion criteria.

---

## **Conditional application of LI-RADS:**

If imaging features suggest cirrhosis or clinical data suggests chronic HBV but there is no documented history of cirrhosis or HBV, then LI-RADS may be applied **conditionally** and the conditional application must be reported explicitly.



## Differences in the US LI-RADS® vs. CT/MRI and CEUS LI-RADS® Populations

The US LI-RADS screening and surveillance population (patients in whom use of US LI-RADS is considered appropriate) and the LI-RADS diagnostic population (patients in whom use of CT/MRI or CEUS LI-RADS is appropriate) are not necessarily the same.

There may be patients for whom HCC screening and surveillance might be performed but LI-RADS is not appropriate even if a screening or surveillance test is positive: e.g., patients with cirrhosis due to vascular disorder such as Budd-Chiari, hereditary hemorrhagic telangiectasia, or cardiac cirrhosis or patients with congenital hepatic fibrosis.

There may be patients for whom LI-RADS might be appropriate but screening and surveillance are not appropriate: e.g., patients with cirrhosis and short life expectancy due to non-hepatic disease.





# Gaps in Knowledge and Future Directions

## Definition of LI-RADS screening and surveillance population

It is unknown whether non-cirrhotic patients with multiple HCC risk factors should undergo HCC screening and surveillance. LI-RADS encourages research to better define the HCC screening and surveillance population. Research is also needed to identify genetic and phenotypic factors (e.g., circulating biomarkers) that modulate HCC risk as these could inform further refinement of screening and surveillance guidelines.

---

## Definition of LI-RADS diagnostic population

It is not known if LI-RADS is appropriate for categorizing liver observations in adults with stage 2 or 3 fibrosis due to chronic HCV, in middle-aged and elderly men with non-cirrhotic NASH, and in elderly women with non-cirrhotic NASH. LI-RADS encourages research to identify all populations in which LI-RADS is appropriate.