Case Author(s): Samuel Wang, M.D. and Henry Royal, M.D., 1/9/97 . Rating: #D2, #Q3

Diagnosis: Metastatic prostate carcinoma

Brief history:

92-year old man with complaints of back pain

Images:

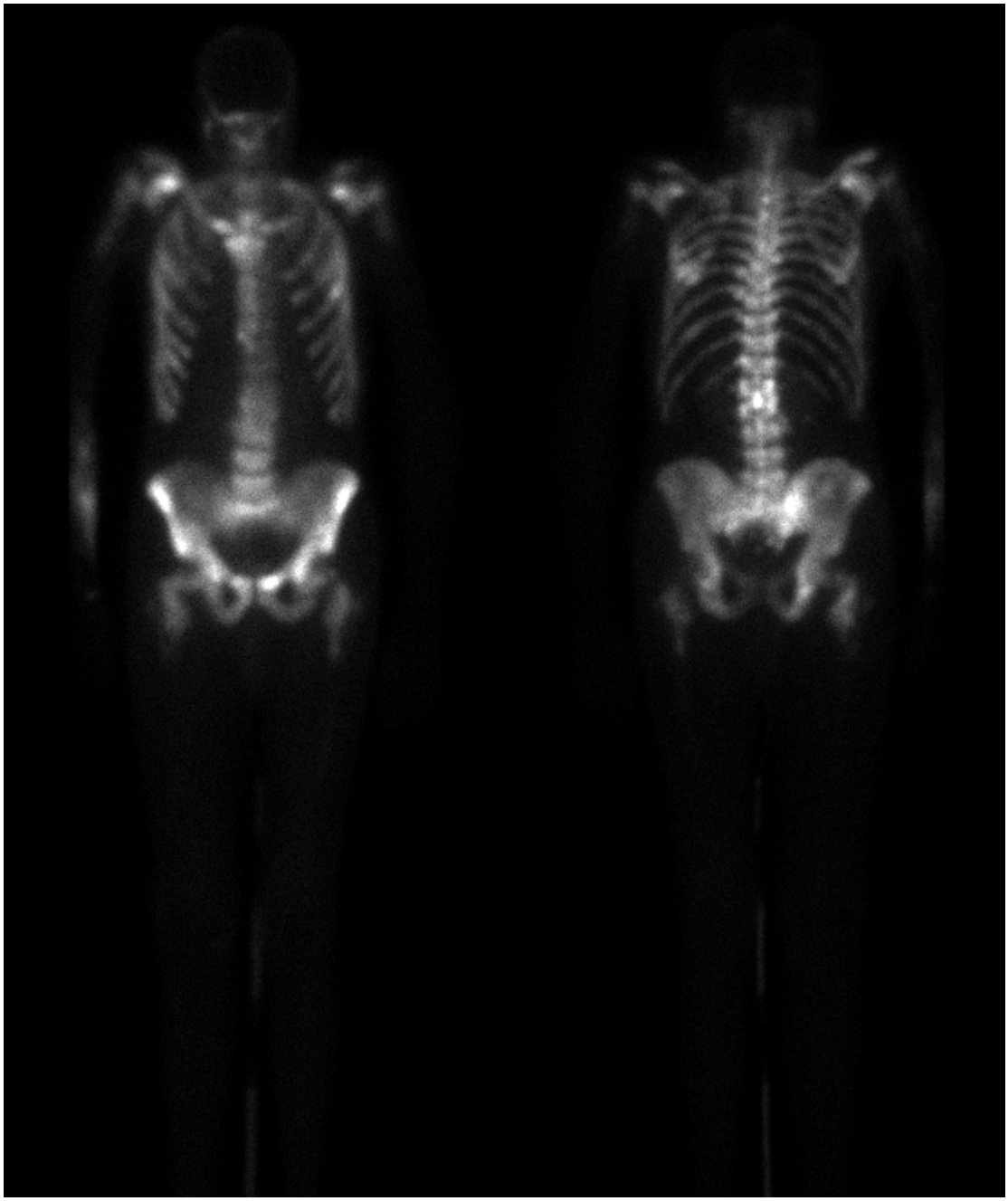

Anterior and posterior images.

View main image(bs) in a separate image viewer

View second image(xr). Plain film L-spine and pelvis

Full history/Diagnosis is available below

Diagnosis: Metastatic prostate carcinoma

Full history:

92-year old man with known metastatic prostate carcinoma. The patient had complaints of diffuse bony pain, most severe in the back. This examination was obtained to evaluate the extent of metastases prior to strontium therapy.

Radiopharmaceutical:

Tc-99m MDP

Findings:

Diffuse areas of markedly increased uptake of the radiopharmaceutical are noted throughout the axial skeleton. The appendicular skeleton is relatively spared with the exception of the proximal aspect of the right forearm. These findings are most consistent with widespread metastatic disease. The plain films confirm the presence of multiple blastic lesions throughout the spine and pelvis.

Discussion:

Widespread osseous metastatic disease may sometimes have a superscan appearance. Key differentiating features from metabolic causes of superscan include more patchy, heterogeneous bony uptake as well as the central axial distribution with relative sparing of the appendicular skeleton.

ACR Codes and Keywords:

- General ACR code: 43

References and General Discussion of Bone Scintigraphy (Anatomic field:Skeletal System, Category:Neoplasm, Neoplastic-like condition)

Search for similar cases.

Edit this case

Add comments about this case

Read comments about this case

Return to the Teaching File home page.

Case number: bs054

Copyright by Wash U MO