

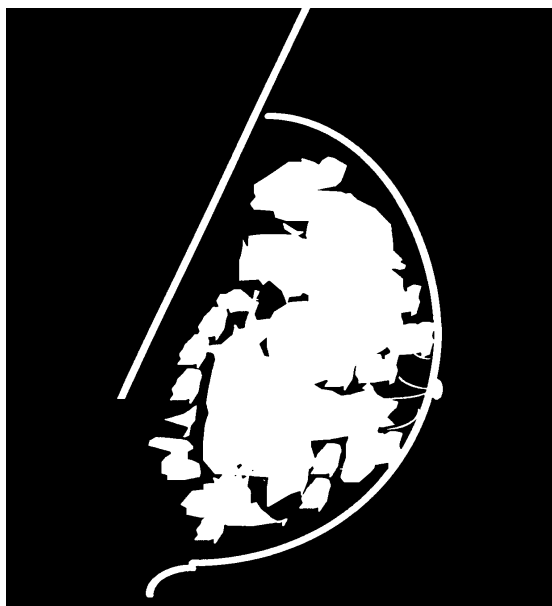


*In order for the ACR Clinical Image Reviewers to assess your image quality for a range of breast types, you must submit one complete exam of fatty breasts and one complete exam of dense breasts. If you are **REPEATING** because you received a deficiency for clinical image quality, you must resubmit **both fatty and dense cases**. If the ACR Reviewers do not believe that your images are of an appropriate density, we will return them to you and request another examination. (Note: Validation Film Check images may be of any breast density.) In addition, **ALL FILMS MUST BE INTERPRETED AS NEGATIVE** (i.e., BI-RADS® Assessment Category 1: "There is nothing to comment on. The breasts are symmetrical and no masses, architectural disturbances or suspicious calcifications are present"). If you have difficulty submitting negative images, please call the ACR.*

EXAMPLES OF FATTY BREAST IMAGES



The fatty breast images **must meet** BI-RADS® Breast Composition **Category 1** (composed almost entirely of fat: <25% glandular) or **Category 2** (scattered fibroglandular densities: 25-50% glandular).

EXAMPLES OF DENSE BREAST IMAGES



The dense breast image **must meet** BI-RADS® Breast Composition **Category 3** (heterogeneously dense: 51-75% glandular) or **Category 4** (extremely dense: >75% glandular).