

## IV. GUIDANCE CHAPTER

**W**ith the Fourth Edition of BI-RADS®, the committee includes this chapter on guidance in response to user comments. Many substantive changes have been incorporated in this edition to improve the clinical utility and to supply a unified base for research involving breast imaging. This chapter will expand on these changes as they appear in each section of BI-RADS® and provide explanations for the change. **What follows is intended for guidance and is not meant to imply required standards of practice.**

### Breast Imaging Lexicon

#### Masses

A mass is a three-dimensional structure demonstrating convex outward borders, usually evident on two orthogonal views. Due to confusion with the term “density,” which describes attenuation characteristics of masses, the term “density” which describes a finding other than a mass has been replaced with “asymmetry.” An asymmetry lacks convex outward borders and the conspicuity of a mass as discussed below.

#### Calcifications

It is confusing to have both “round” and “punctate” as separate descriptions unless each has characteristic features. The difference relates to size, with “punctate” defined as smaller than 0.5 mm and “round” as greater than or equal to 0.5 mm. The phrase “coarse heterogeneous” was added to describe calcifications of intermediate concern which are larger than 0.5 mm and variable in size and shape, but are smaller than those that usually occur in response to injury. When present as multiple bilateral groupings, coarse heterogeneous

calcifications are often due to fibrosis or fibroadenomas and follow-up may be appropriate. These tend to coalesce into typically benign calcifications. As an isolated cluster, “coarse heterogeneous” calcifications, however, have a small but significant likelihood of malignancy, especially when occurring together with smaller pleomorphic calcifications. Further data is needed on this issue. As with any calcifications, distribution must also be considered. Coarse heterogeneous calcifications in a linear or segmental distribution may be due to malignancy. To summarize, “coarse heterogeneous” was added and “fine pleomorphic” should be used to describe calcifications smaller than 0.5 mm that are variable in shape and have a higher probability of indicating malignancy.

#### Special Cases

Several questions were received by the BI-RADS® committee reflecting confusion distinguishing the terms “mass,” “focal asymmetry” and “asymmetry.” A mass should demonstrate completely or partially visualized convex outward borders and is usually depicted on orthogonal views.

Asymmetries are planar, lack convex borders, usually contain interspersed fat and lack the conspicuity of a three-dimensional mass. In order to clarify asymmetry, the term “global asymmetry” was introduced with this edition to underscore the difference between generalized and focal asymmetry. “Global asymmetry” involves a large portion of the breast (at least a quadrant). In the absence of a palpable correlate, a “global asymmetry” is usually due to normal variations or hormonal influence. A “focal asymmetry” differs from a mass since it usually lacks convex outward borders and differs from “global asymmetry” only in

the size of the area of the breast involved. A focal asymmetry is of more concern than a global asymmetry. Comparison to prior films is critical in evaluating asymmetries. A developing density requires additional evaluation in the absence of a history of surgery, trauma or infection at the site. What appears to be a focal asymmetry seen on screening, when further evaluated with spot compression views and/or ultrasound, may prove to be due to an indistinctly marginated mass.

### Report Organization

Many of the suggestions and questions received by the BI-RADS® committee concerned the assessment categories. We have responded and hopefully made changes that allow more flexibility and mirror what occurs in clinical practice.

BI-RADS® was designed as a mammographic tool. With the Fourth Edition, BI-RADS® for mammography has been combined with BI-RADS®–Ultrasound and BI-RADS®–MRI. Where appropriate, these two new lexicons are arranged in a similar manner. Both Ultrasound and MRI have features that are unique to each modality but, wherever applicable, terms having been developed for mammography are used. Assessment categories are the same for all BI-RADS® lexicons.

### Assessment Categories

BI-RADS® assessments are divided into incomplete (Category 0) and final assessment categories (Categories 1, 2, 3, 4, 5 and 6). An incomplete assessment requires further evaluation with additional mammographic views, comparison films, ultrasound or, less commonly, MRI. When additional imaging studies are completed, a final assessment is rendered. Ideally, the report of diagnostic mammographic views and ultrasound will be included in the same report, with separate paragraphs detailing each, and one integrated final assessment that takes into consideration all breast imaging findings.

The Mammography Quality Standards Act (MQSA) requires that a single assessment be given to a mammographic study. Sites or individuals who wish to provide a BI-RADS® assessment separately for each breast may do so within the impression text or body of the report, provided that the single overall assessment for the study is clearly coded at the end of the entire report. The overall final assessment should, of course, be based on the most worrisome findings present. For example, if probably benign findings are noted in one breast and suspicious abnormalities in the opposite breast, the overall report should be coded BI-RADS® Category 4 suspicious abnormality. Similarly, if immediate additional evaluation is still needed for one breast, (as an example, the patient could not wait for an ultrasound examination at the time), and the opposite breast had probably benign findings, the overall code would be BI-RADS® Category 0, incomplete.

A great deal of confusion centers on the patient with a palpable finding and negative imaging. These reports should be coded with final assessments based on the imaging findings. When the interpretation of imaging findings is influenced by the clinical findings, the final assessment should take both into consideration and the clinical findings may be detailed in the report.

### Category 3

The use of Category 3, probably benign, is reserved for findings that are almost certainly benign. It must be emphasized that this is NOT an indeterminate category for malignancy, but one that, for mammography, has a less than 2% chance of malignancy (i.e. is almost certainly benign). Such findings are generally identified on baseline screening or on screening for which previous examinations are unavailable for comparison. Immediate evaluation with additional mammographic views and/or ultrasound is required to render a

Category 3, probably benign assessment. Lesions appropriately placed in this category include a nonpalpable, circumscribed mass on a baseline mammogram (unless it can be shown to be a cyst, an intramammary lymph node, or another benign finding), a focal asymmetry which partially thins on spot compression, and a cluster of punctate calcifications (1). The initial short-term follow-up is usually a unilateral mammogram at 6 months after the time of the initial screening examination. Assuming stability of the finding, the recommendation is then for a bilateral follow-up examination in another 6 months (corresponding to 12 months after the initial examination). If no other features of concern are noted at this bilateral second short-interval follow-up, the examination is again coded as Category 3 with recommendation typically bilateral 12-month follow-up. If the feature(s) again shows no change in the next subsequent 12-month examination (corresponding to 24 months after the initial examination), the final assessment may be Category 2, benign, or Category 3, probably benign at the discretion of the interpreting physician. According to the literature (2), after 2 to 3 years of stability, the final assessment category may be changed to a Category 2, benign, although diagnostic (rather than screening) follow-up may be appropriate if, for example, continued magnification views will be needed.

As with any interpretive examination, a less experienced reader may still perceive a minimal focal asymmetry that changes with workup to be a Category 3 finding. A more experienced reader at 6, 12 or 24 months may recognize this as a normal variant and classify it as Category 1, negative. With a properly worded report the assessment category may be then changed to one that the current reader feels is appropriate.

It is also possible that a Category 3 finding is biopsied as a result of patient and/or clinician

concern, or lack of confidence in the probably benign follow-up assessment (see Figure 1). In such instances the final assessment category should be based on risk of malignancy, rather than management provided. Lesions appropriately classified as probably benign on ultrasound include nonpalpable incidental complicated cysts. Individual centers have shown < 2% rate of malignancy for nonpalpable, oval circumscribed hypoechoic solid masses that may be indistinguishable from complicated cysts. Clustered microcysts without a discrete solid component may also be included in this category.

The proper use of a Category 3, probably benign, assessment requires auditing one's practice. The rate of malignancy for mammographic findings placed in this category should be < 2%. For ultrasound, the rate of malignancy also should be < 2%, but this has not been widely validated in the literature. For MRI, the types of findings to be placed in short interval follow-up and expected rate of malignancy require further study. It is imperative that short interval follow-up does not alter the stage distribution or the prognosis of the few patients with malignancies placed under surveillance: this information must be included in the audit.

#### Category 4

Category 4 is used for the vast majority of findings prompting breast interventional procedures ranging from aspiration of complicated cysts to biopsy of pleomorphic calcifications. Many institutions have, on an individual basis, subdivided Category 4 to account for the vast range of lesions subjected to interventional procedures and corresponding broad range of risk of malignancy. This allows a more meaningful practice audit, is useful in research involving receiver-operating characteristic (ROC) curve analysis, and is an aid for clinicians and pathologists. The **optional** division

of Category 4 into three subdivisions **internally** at the facility level helps to accomplish these goals.

#### Category 4A

Category 4A may be used for a finding needing intervention but with a *low suspicion for malignancy*. A malignant pathology report not expected and a 6-month or routine follow-up after a benign biopsy or cytology is appropriate. Examples of findings placed in this category may be a palpable, partially circumscribed solid mass with ultrasound features suggestive of a fibroadenoma, a palpable complicated cyst or probable abscess.

#### Category 4B

Category 4B includes lesions with an *intermediate suspicion of malignancy*. Findings in this category warrant close radiologic and pathologic correlation. Follow-up with a benign result, in this situation, depends on concordance. A partially circumscribed, partially indistinctly marginated mass yielding fibroadenoma or fat necrosis is acceptable, but a result of papilloma might warrant excisional biopsy.

#### Category 4C

Category 4C includes findings of *moderate concern, but not classic* (as in Category 5) for malignancy. Examples of findings placed in this category are an ill-defined, irregular solid mass or a new cluster of fine pleomorphic calcifications. A malignant result in this category is expected.

These internal divisions of Category 4 should encourage pathologists to initiate further evaluation of benign results in a Category 4C, and should allow clinicians to better understand follow-up recommendations after biopsy for findings placed in each subset of Category 4.

#### Category 5

Category 5 is used for lesions almost certainly representing breast carcinoma. In earlier editions of BI-RADS® when histopathologic or cytologic diagnoses obtained by needle biopsies were less common, this assessment category signified that a lesion might be treated definitively without prior tissue sampling. This category must be reserved for findings that are classic breast cancers, with a  $\geq 95\%$  likelihood of malignancy. A spiculated, irregular high-density mass, a segmental or linear arrangement of fine linear calcifications or an irregular spiculated mass with associated pleomorphic calcifications are examples of lesions that should be placed in Category 5. Findings that warrant biopsy but are not classic for malignancy should be placed in Category 4, ideally in one of the three subdivisions mentioned above.

#### Category 6

This category has been added for breast findings confirmed to be malignant by biopsy *but prior to definitive therapies* such as surgical excision, radiation therapy, chemotherapy or mastectomy. Unlike BI-RADS® categories 4 and 5, there is no associated intervention required to confirm malignancy. This category is appropriate for second opinions on findings previously biopsied and shown to be malignant or for the monitoring of responses to neoadjuvant chemotherapy prior to surgical excision.

There may be scenarios where patients with biopsy-proven malignancy are sent for further imaging evaluation prior to therapeutic intervention. For example, a patient with known malignancy in one breast may be sent for outside film consultation with resulting recommendation for additional evaluation of other abnormalities in the same or opposite breast (Category 0). As in any situation, the final assessment should be based on the most immediate action required. The additional

evaluation may show a cyst in the opposite breast, a benign finding that requires no action, and the final assessment would then revert to Category 6 due to the known but as yet untreated cancer. If additional evaluation reveals a separate suspicious finding requiring biopsy, the overall assessment should be Category 4, suspicious, with biopsy recommended as that is the next action required.

If additional work-up is performed only on the opposite breast, it should be coded appropriately for the findings in that breast alone, however, it may be advisable to add a comment in the impression/recommendation that definitive treatment of the known cancer in the opposite breast is still required.

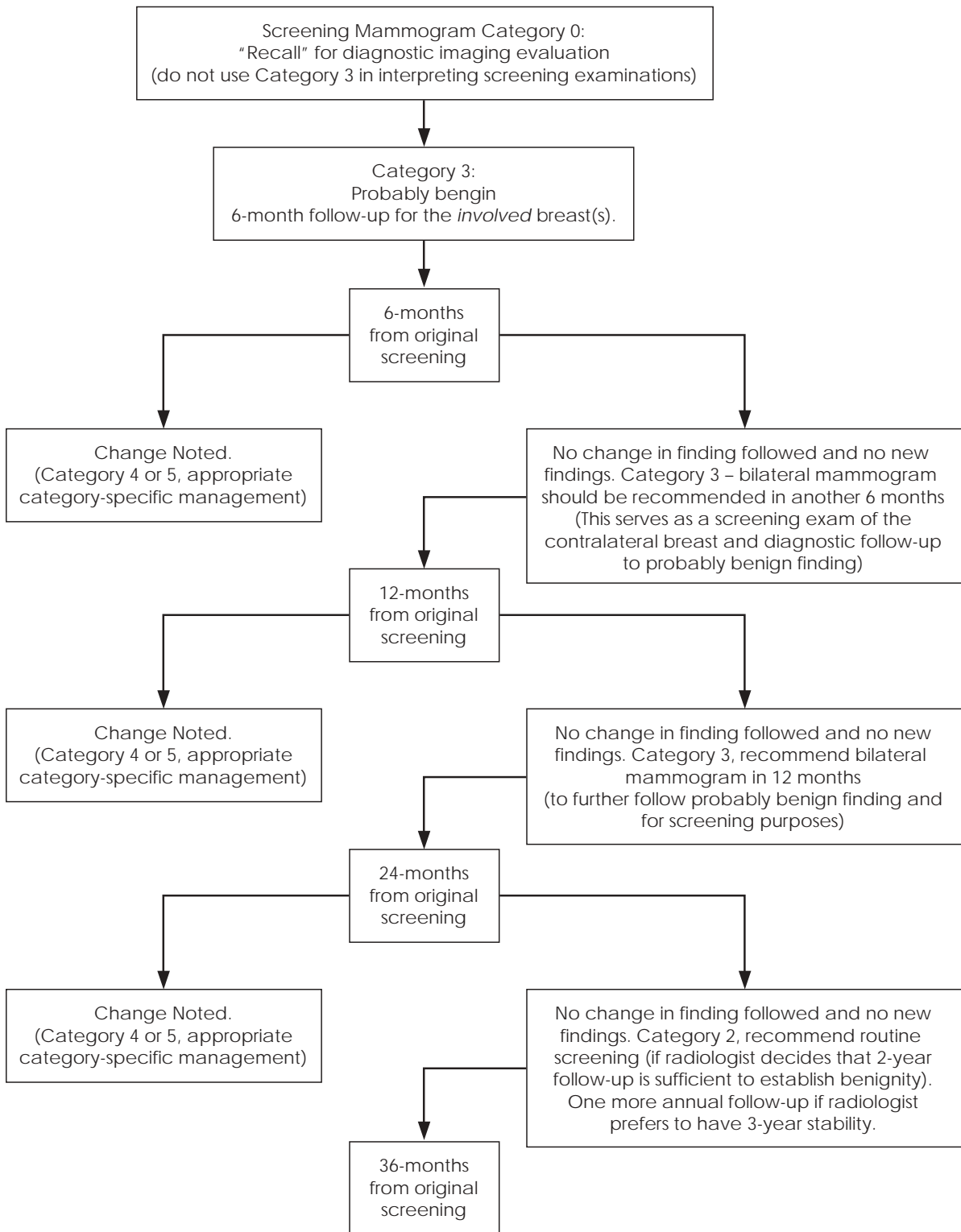
Use of Category 6 is not appropriate following excision of a malignancy (lumpectomy). After surgery, there may be no residual evidence of tumor, with final assessment of Category 3, probably benign, or Category 2, benign. There may, alternatively, be calcifications suspicious for residual tumor, with final assessment of Category 4, suspicious, or Category 5, highly suggestive of malignancy, with recommendation for biopsy or additional surgery.

A major rationale for adding Category 6 is that examinations meriting this assessment should be excluded from auditing. Auditing that includes such examinations would inappropriately indicate inflated cancer detection rates, positive predictive values, and other outcomes parameters.

### Category 0

Category 0 is utilized after a screening examination. When further imaging evaluation (e.g. additional views or ultrasound) or retrieval of prior films is required. Comparison to old films decreases the need for recall. However, comparison is not always required to interpret mammograms (3-4). In the absence of any findings of concern, it was found that prior films will be helpful in only 35/1093 (3.2%) of cases (5). Only examinations requiring prior films in order to make a valid assessment should be coded as Category 0. This would most often include cases with a focal asymmetry that could represent a normal variant or mammograms showing circumscribed mass(es) that may have been present previously. The recommendations should detail the suggested workup (e.g., additional views and/or ultrasound) needed if old films are not received.

**Figure 1. Category 3 Algorithm**



## IV. REFERENCES

1. Sickles EA. Periodic mammographic follow-up of probably benign lesions: results in 3,184 consecutive cases. *Radiology* 1991;170:463-468.
2. Sickles EA. Management of probably benign breast lesions. *Radiol Clin North Am* 1995;33:1123-1130.
3. Frankel SD, Sickles EA, Curpen BN, Sollitto RA, Ominsky SH, Galvin HB. Initial versus subsequent screening mammography: comparison of findings and their prognostic significance. *Am J Roentgenol* 1995;164:1107-1109.
4. Thurfjell MG, Vitak B, Azavedo E, Svane G, Thurfjell E. Effect on sensitivity and specificity of mammography screening with or without comparison of old mammograms. *Acta Radiol*. 2000 Jan;41(1):52-56.
5. Bassett LW, Shayestehfar B, Hirbawi I. Obtaining previous mammograms for comparison: usefulness and costs. *AJR Am J Roentgenol*. 1994 Nov;163(5):1083-1086.