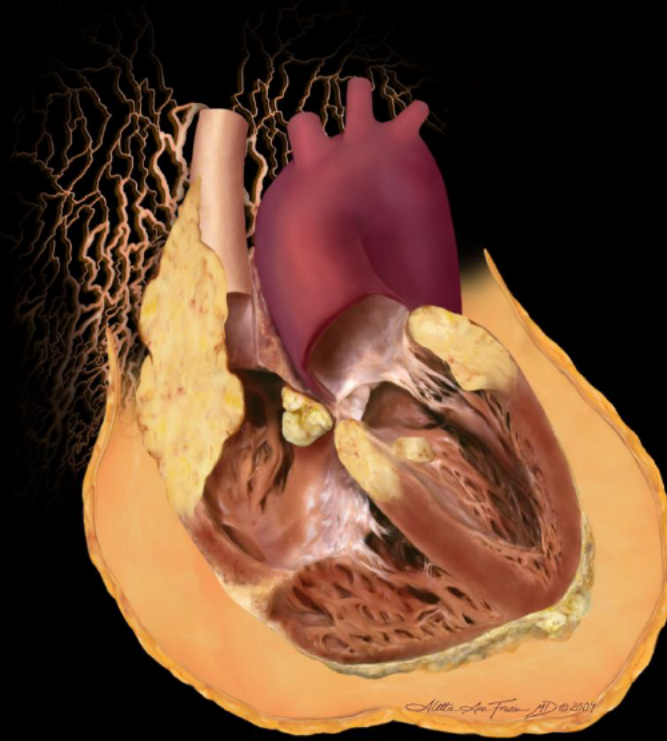
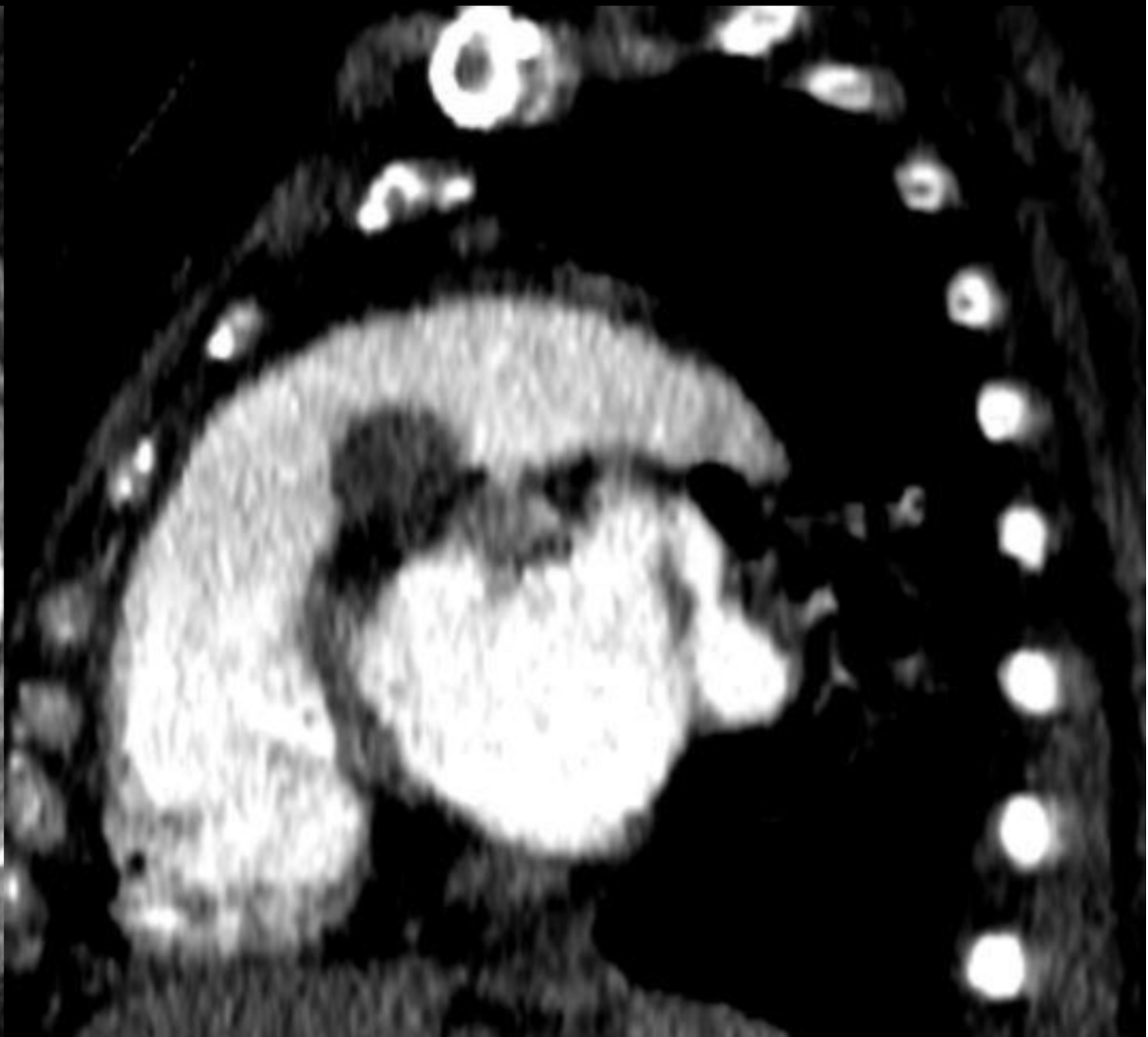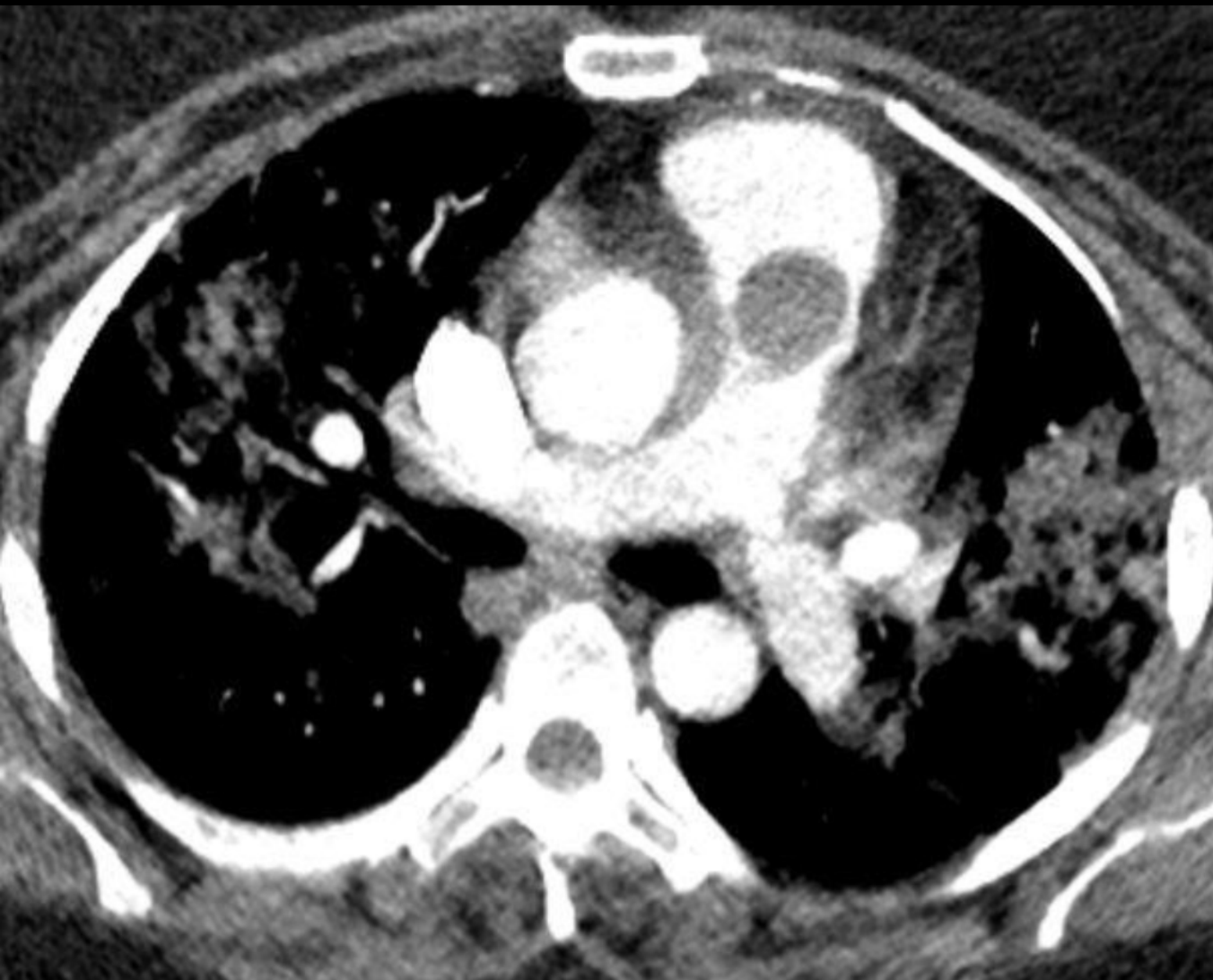


Cardiovascular Best Case



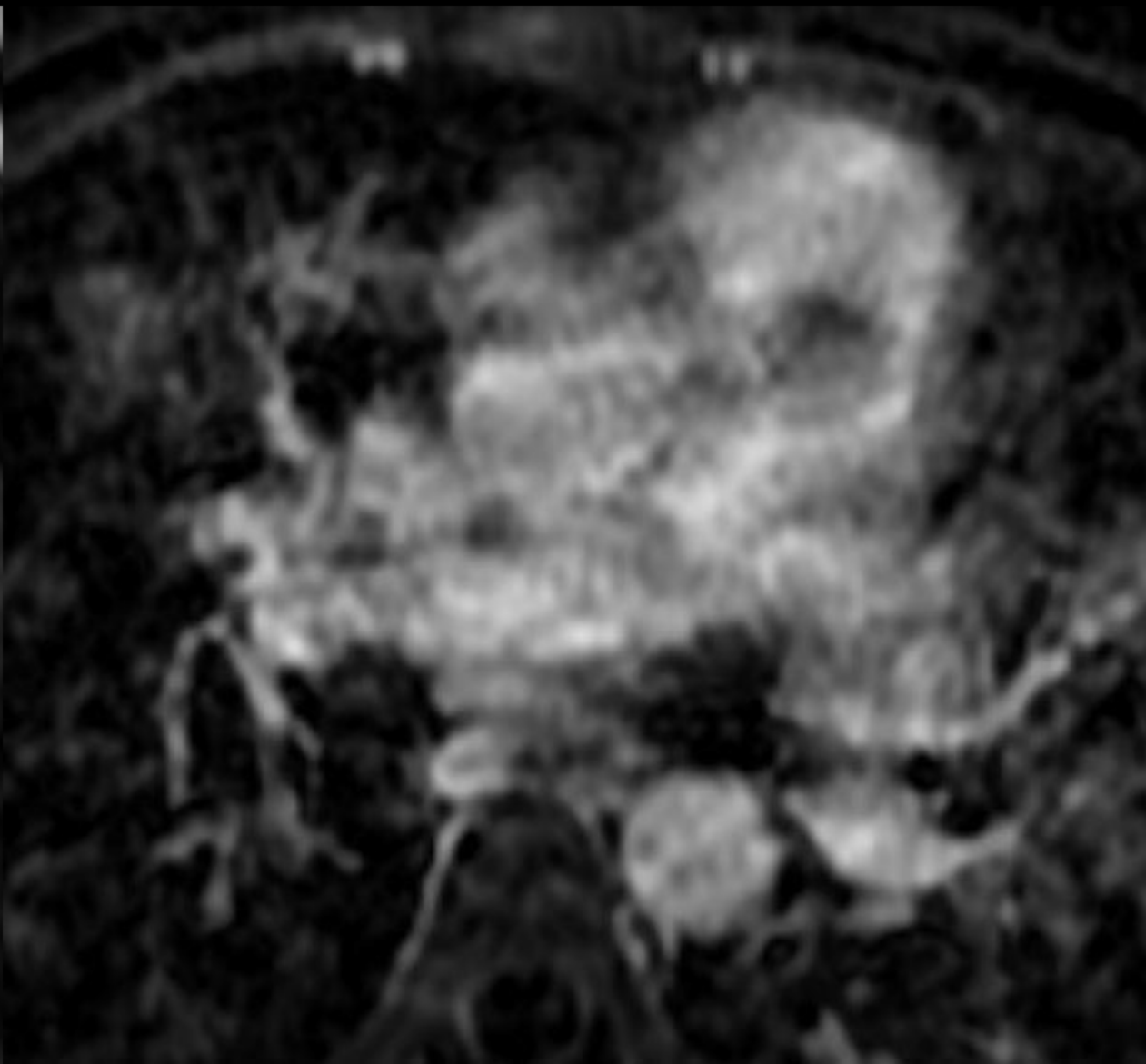
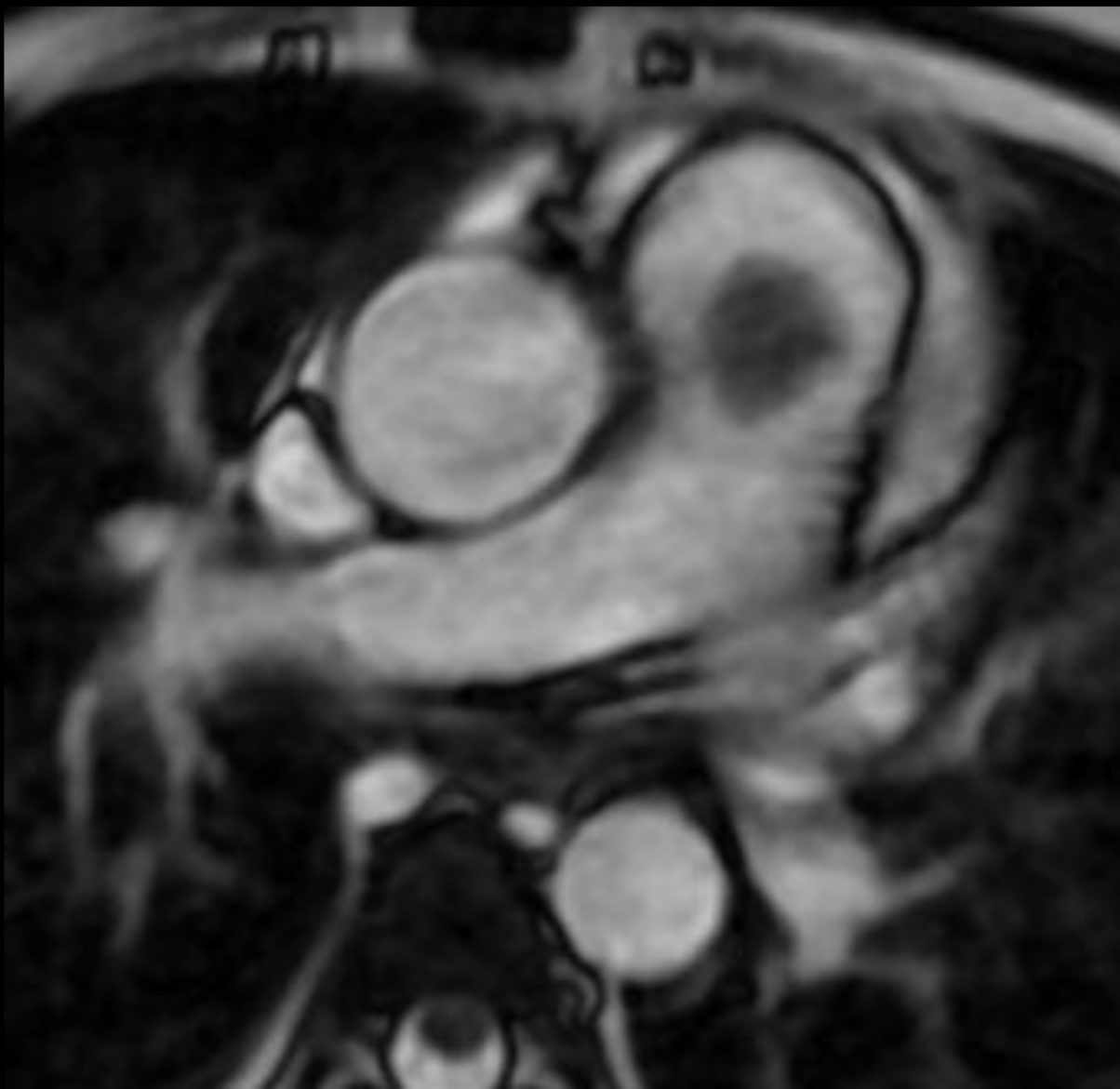Clinical information

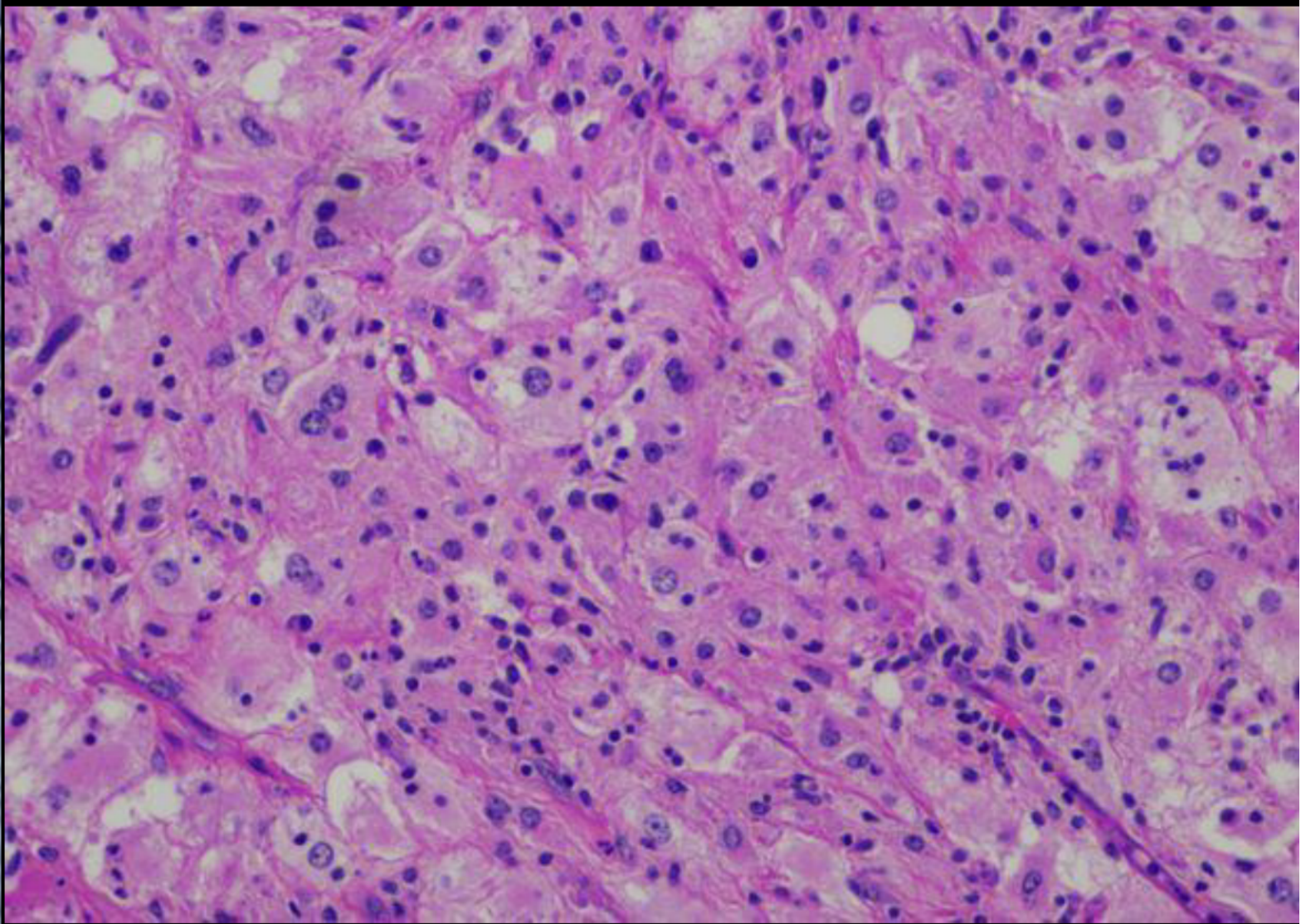
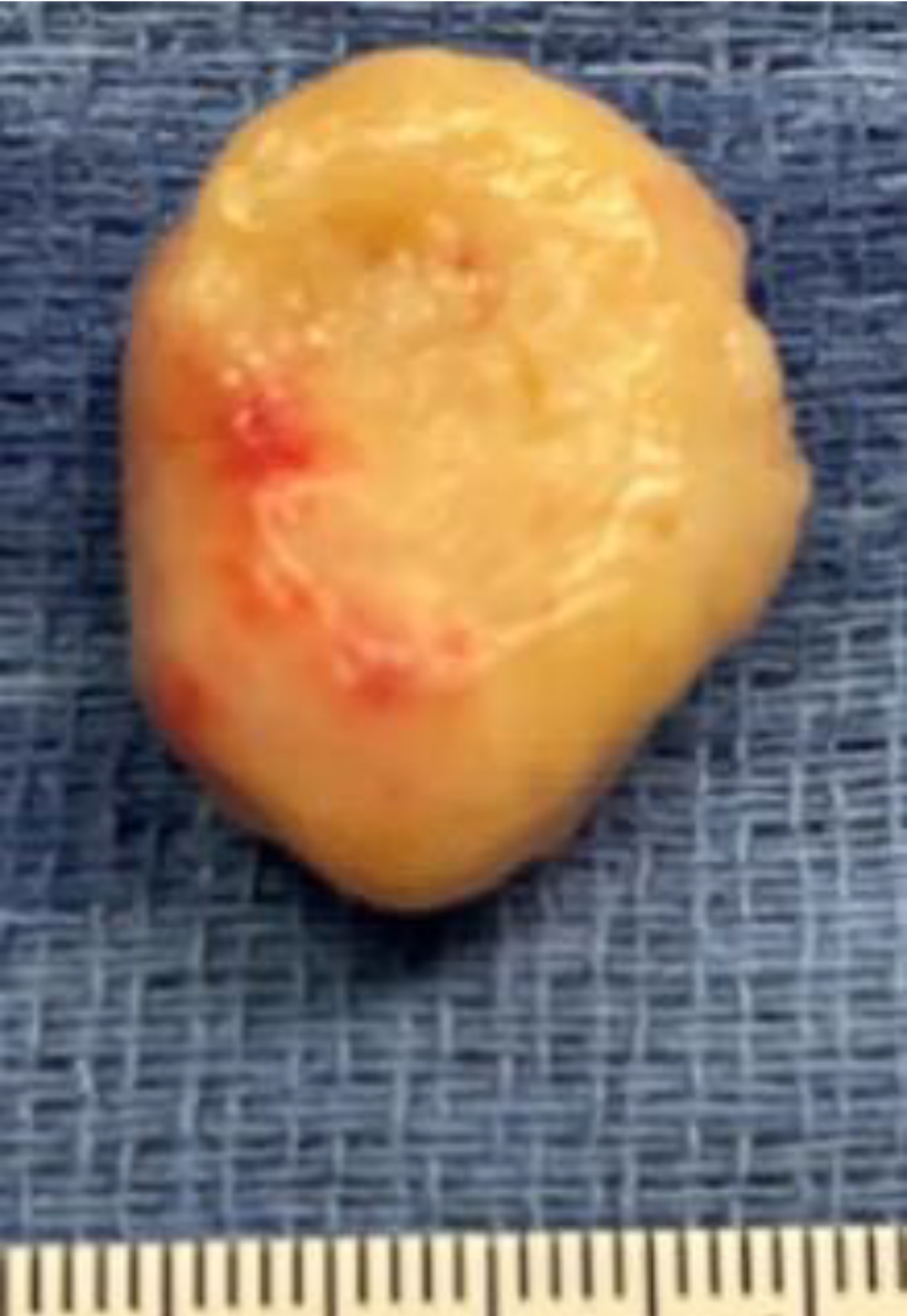31 year old woman with chest tightness.

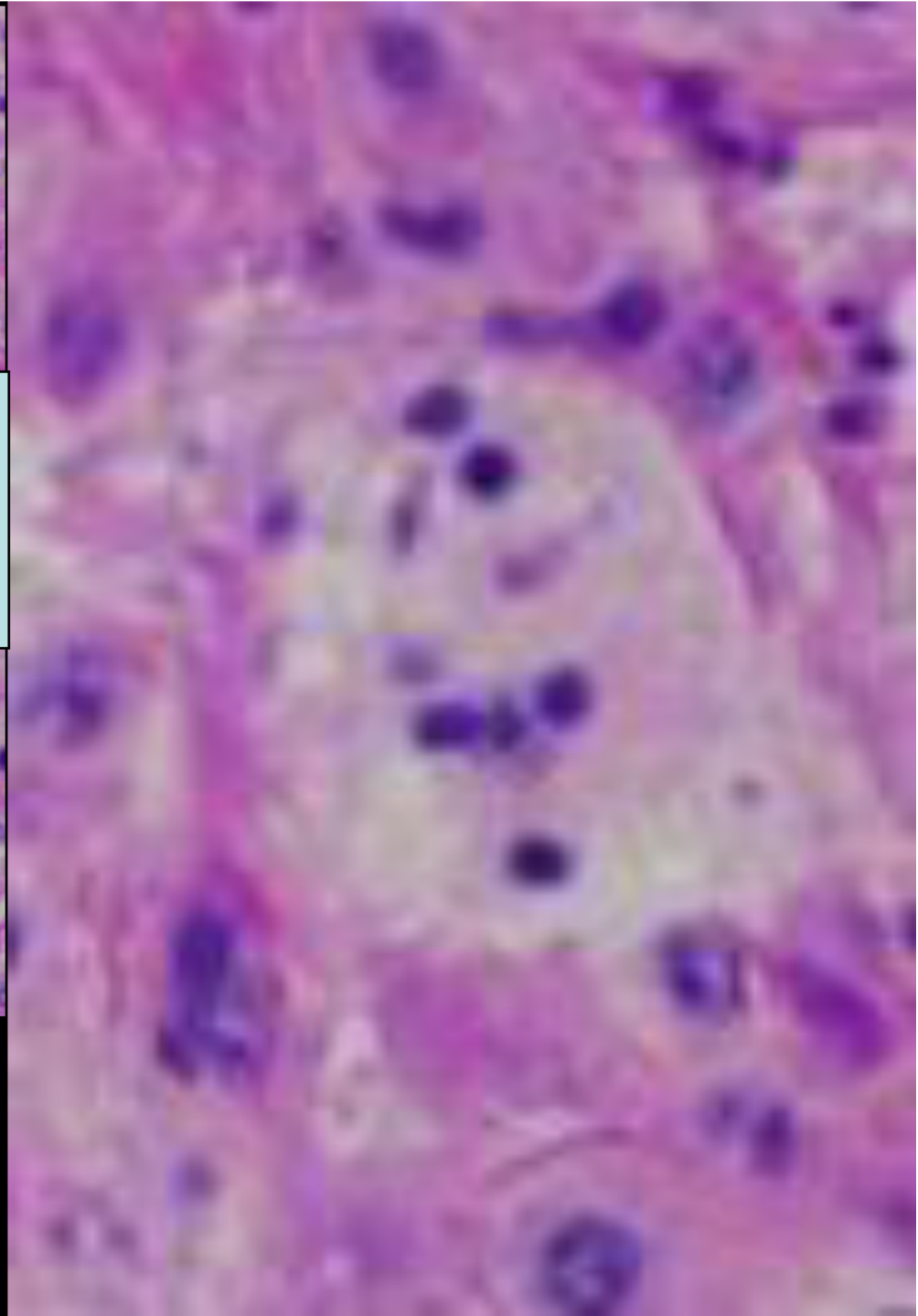
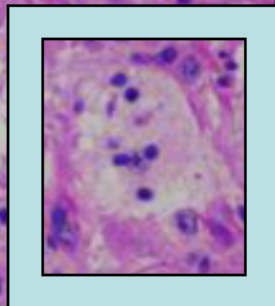
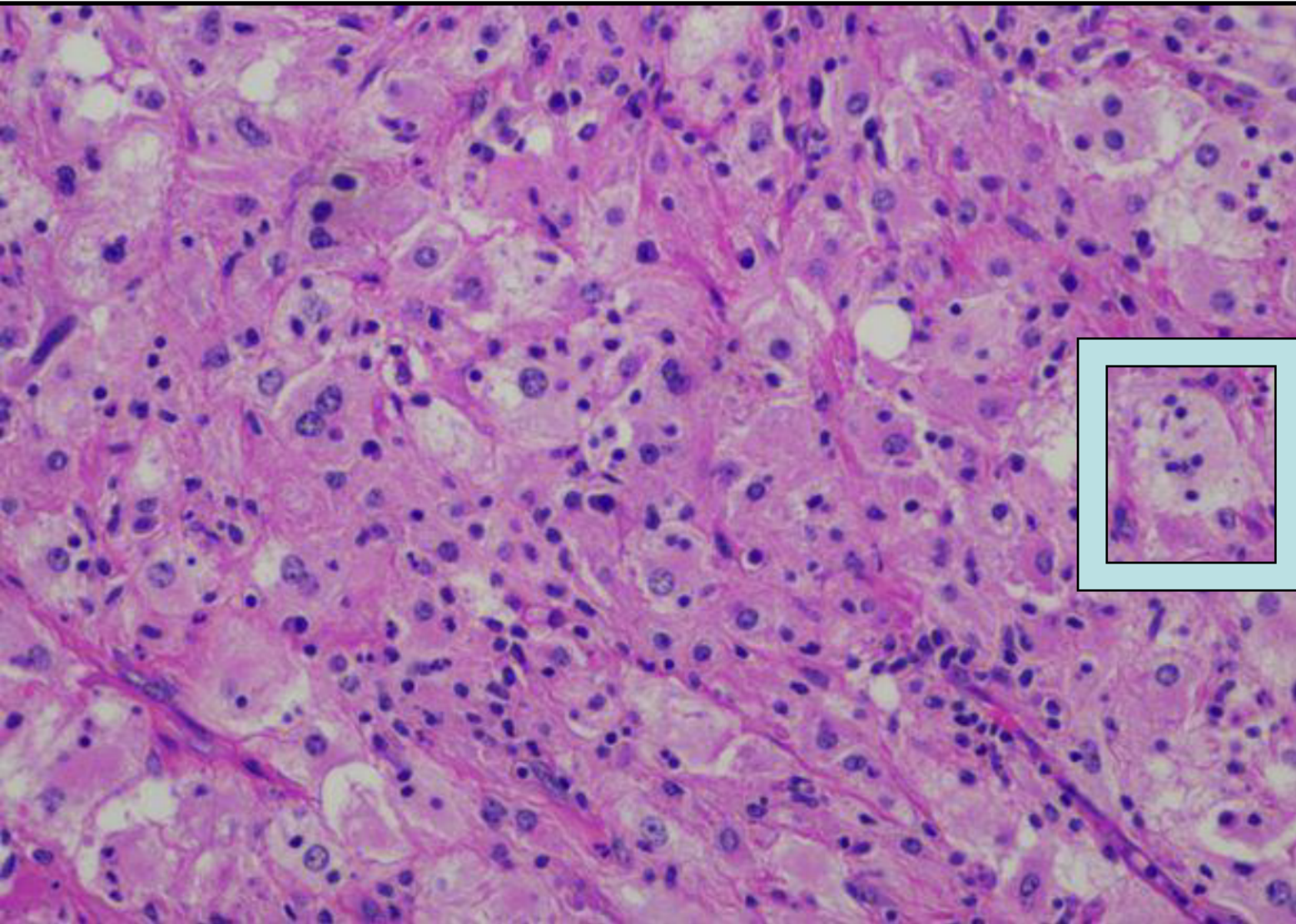


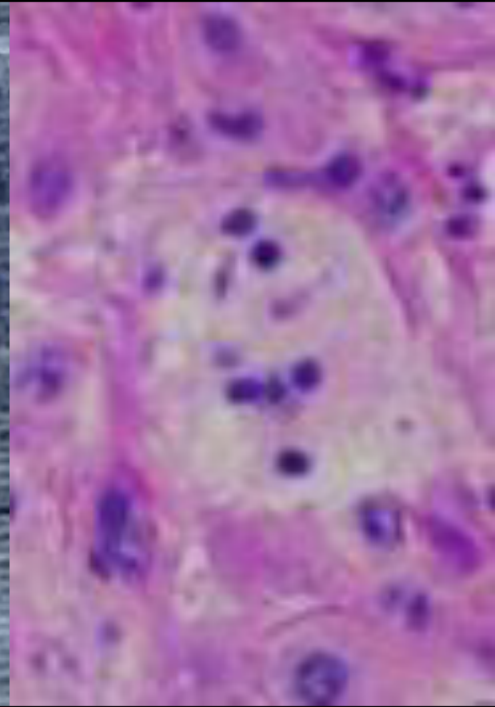
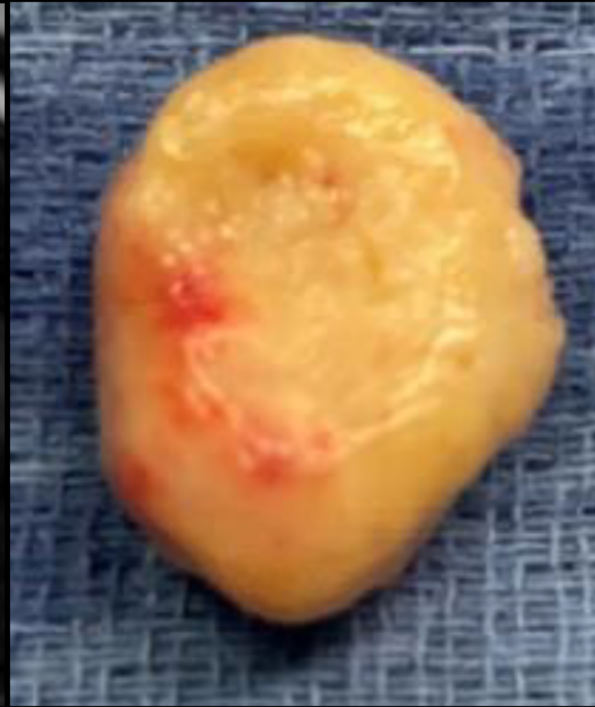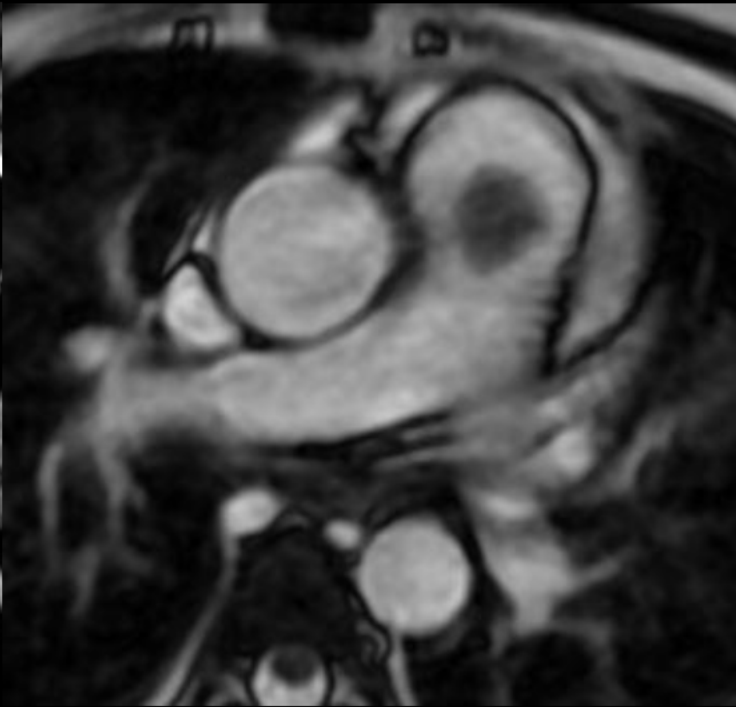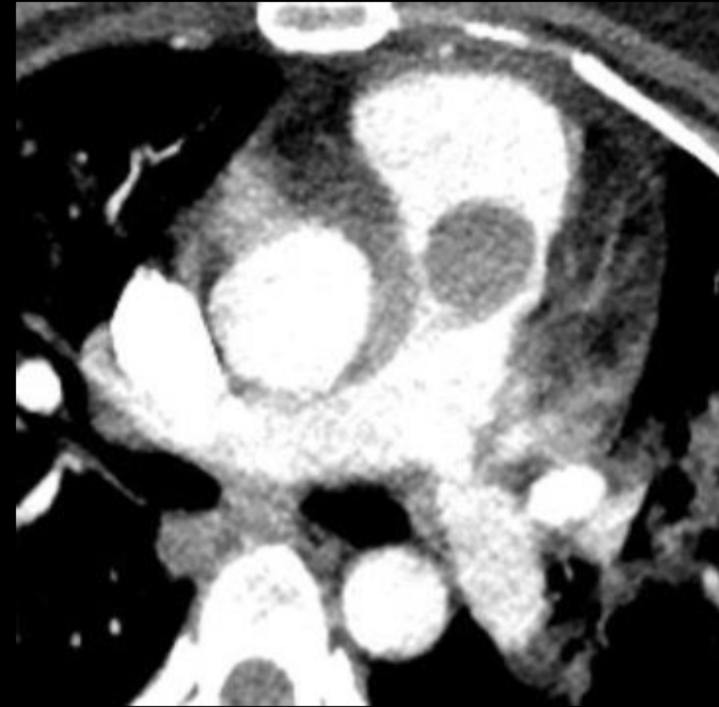
AIRP

ACR INSTITUTE FOR
RADIOLOGIC PATHOLOGY









Rosai-Dorfman Disease