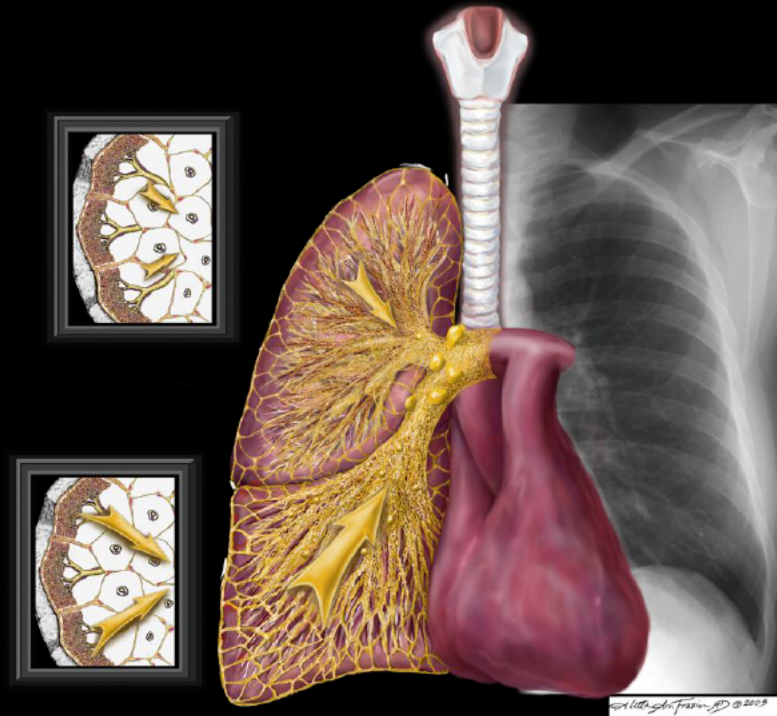


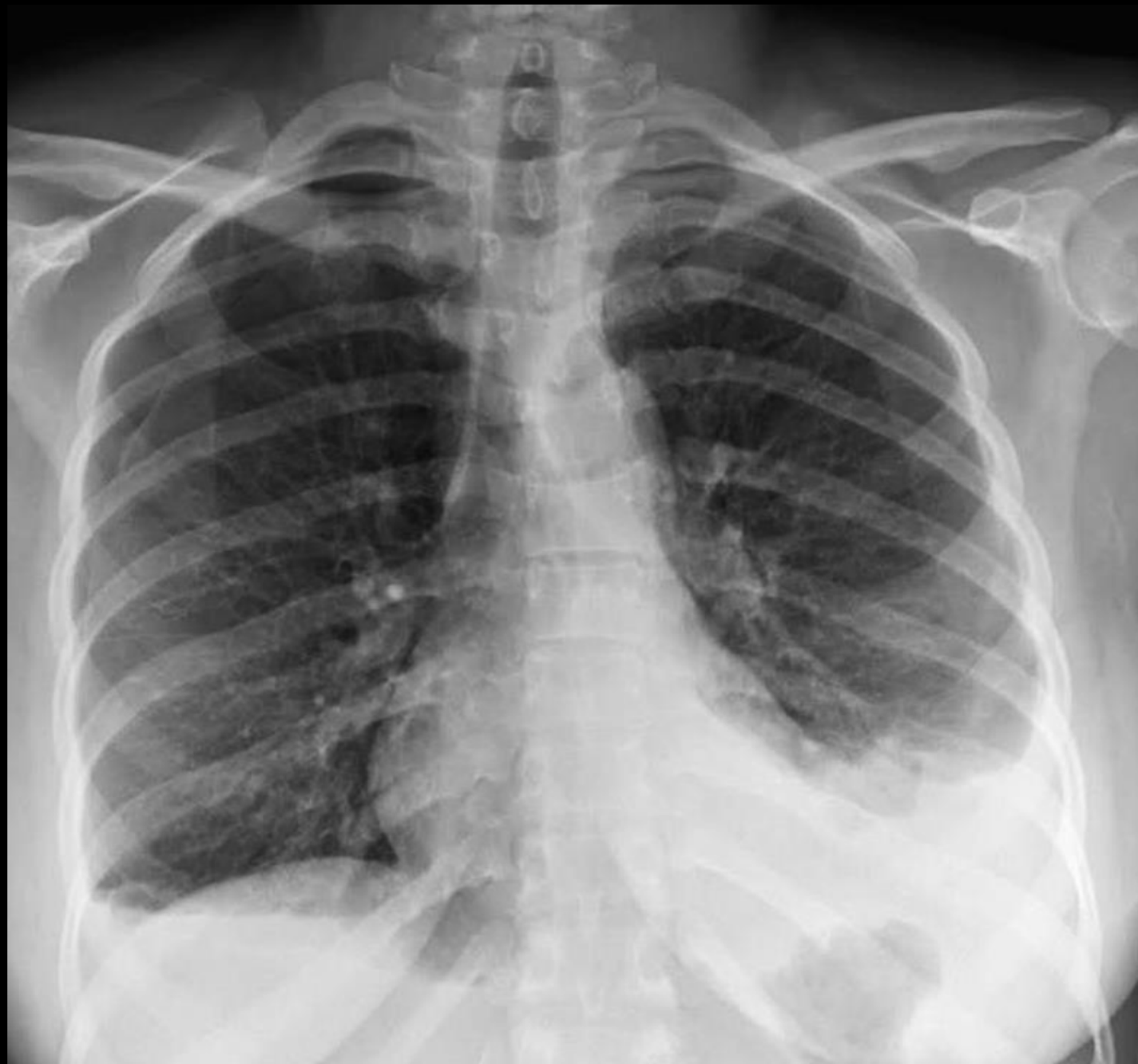# Pulmonary and Mediastinal Best Case

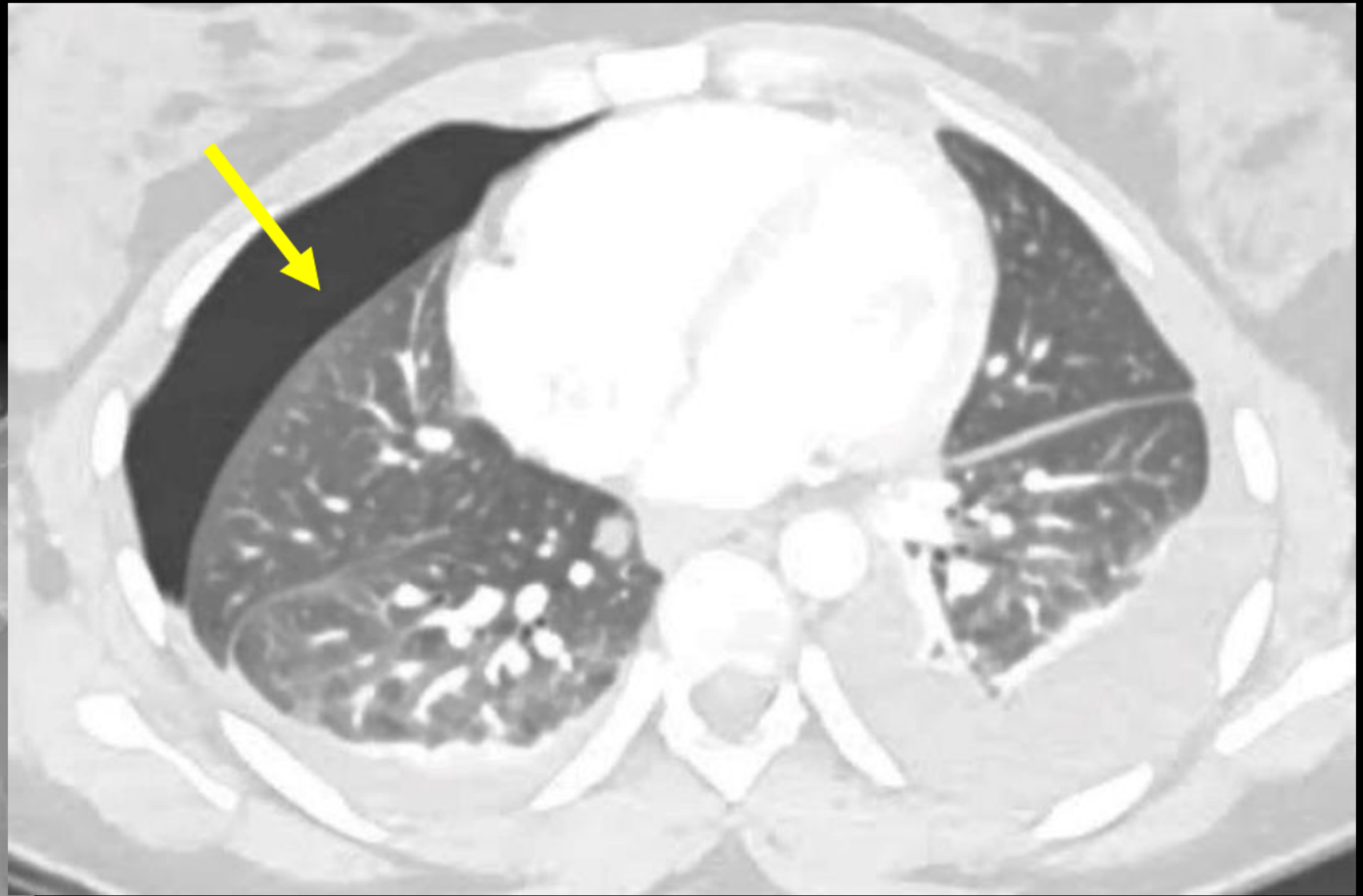
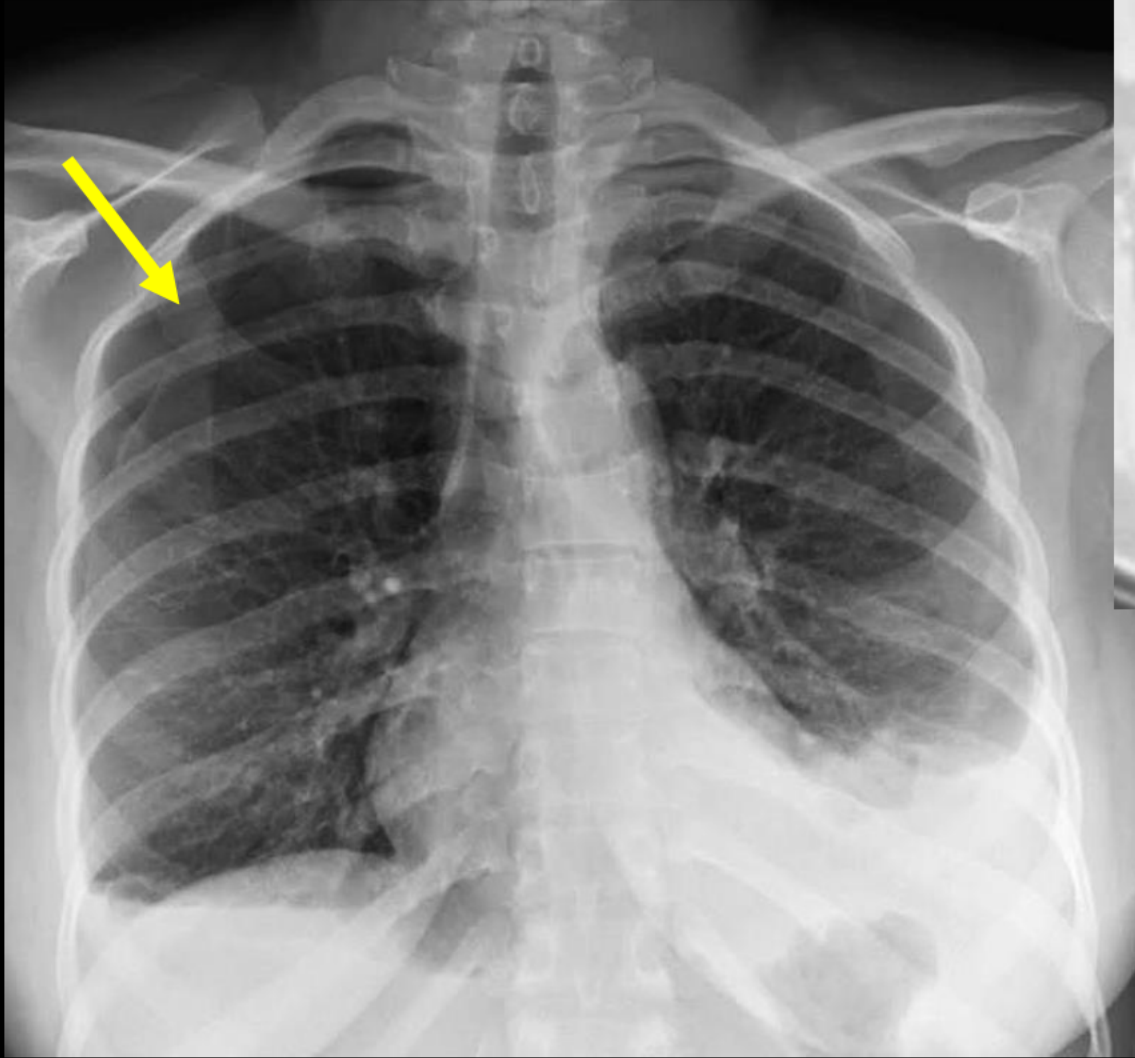


# Clinical information

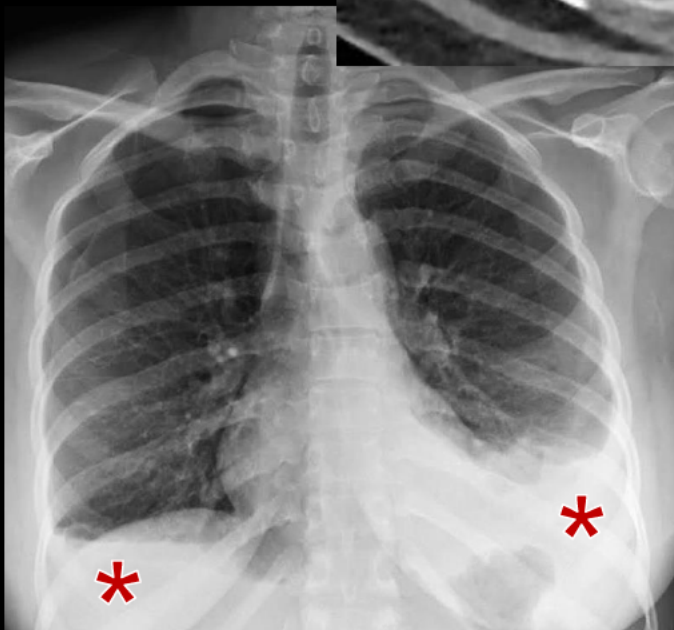
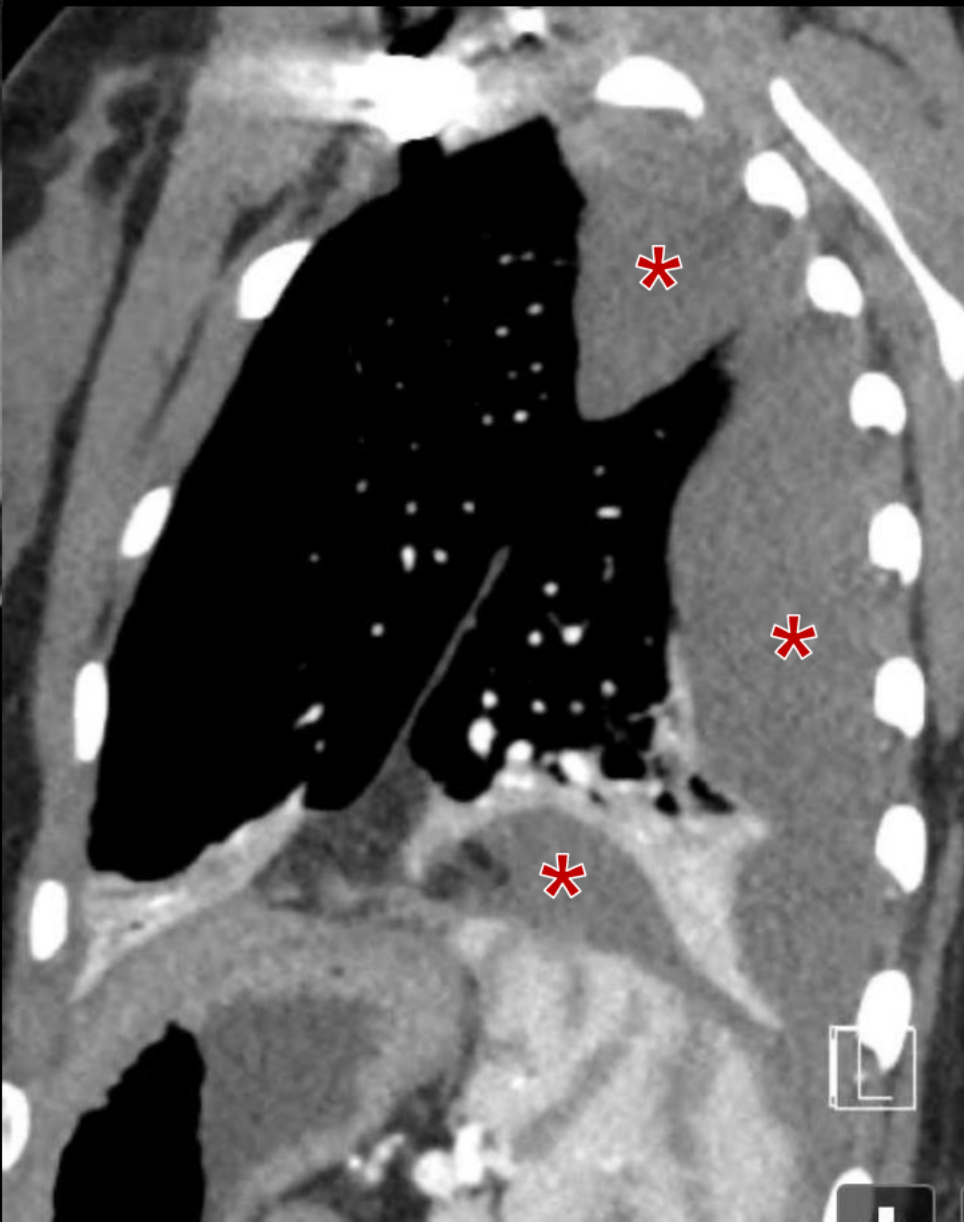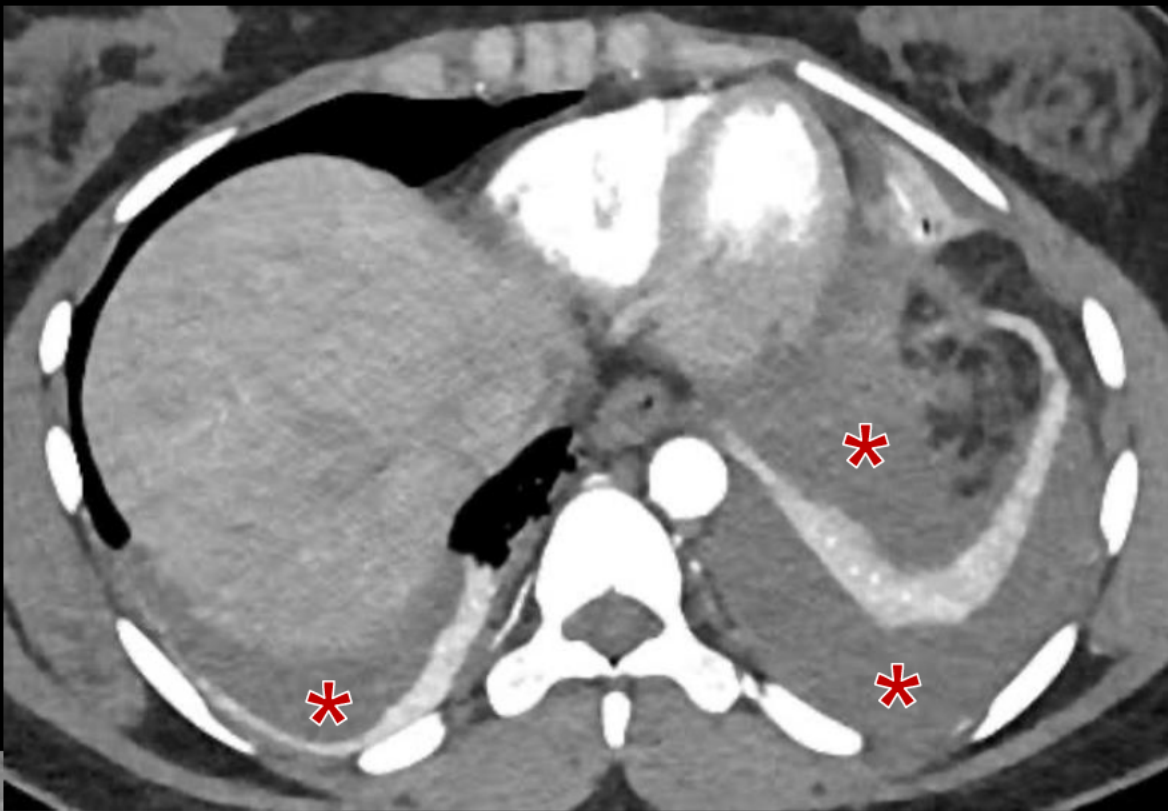**33-year-old female presents with two-day history of chest pain and shortness of breath, accompanied by pleuritic pain.**

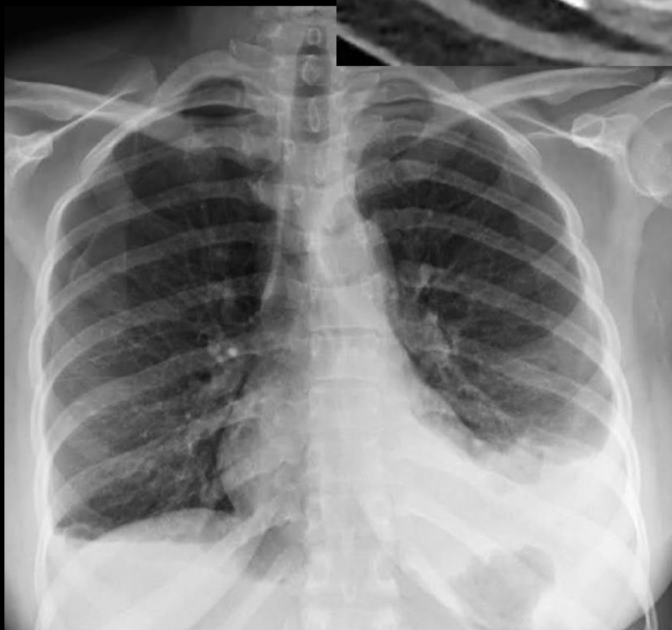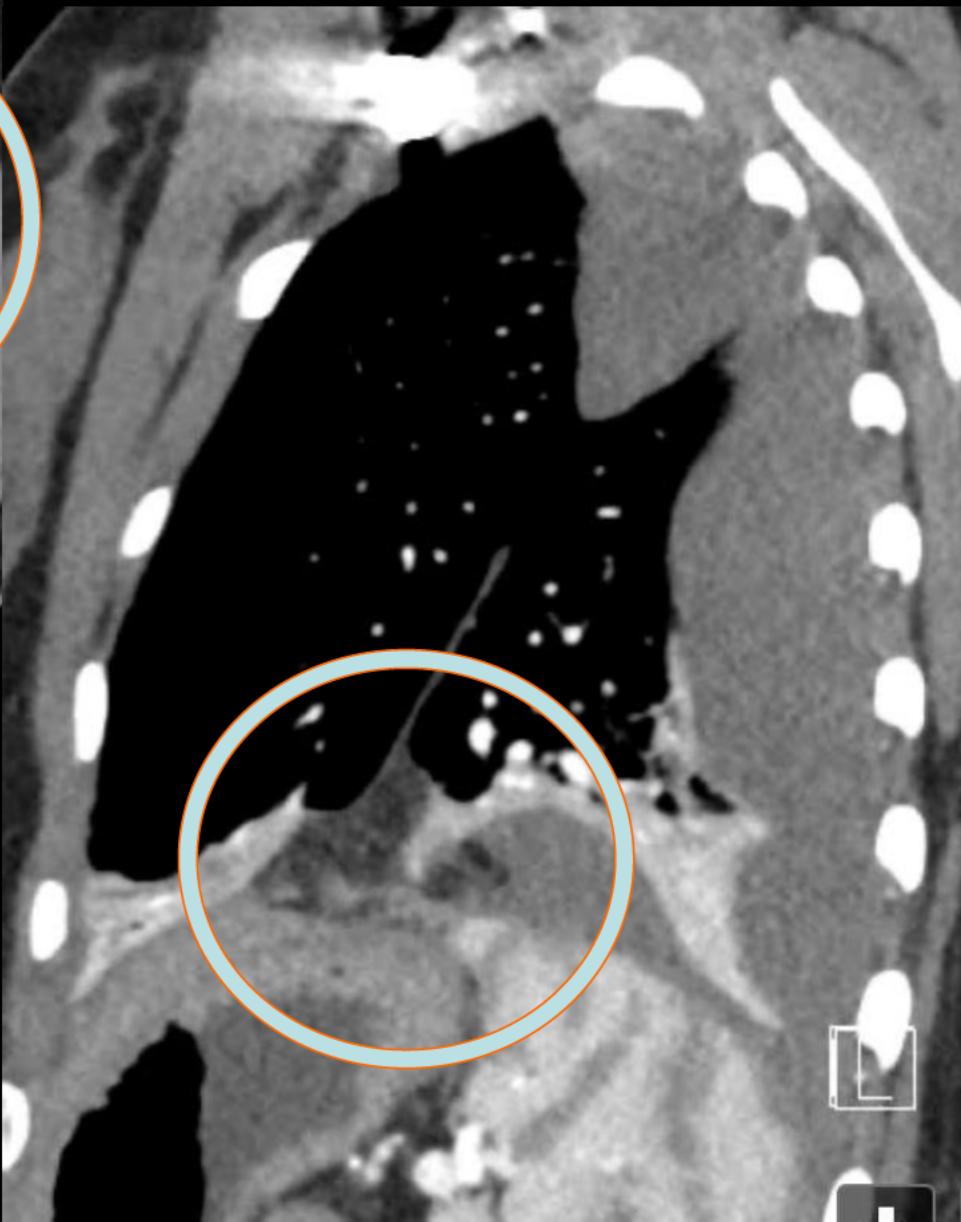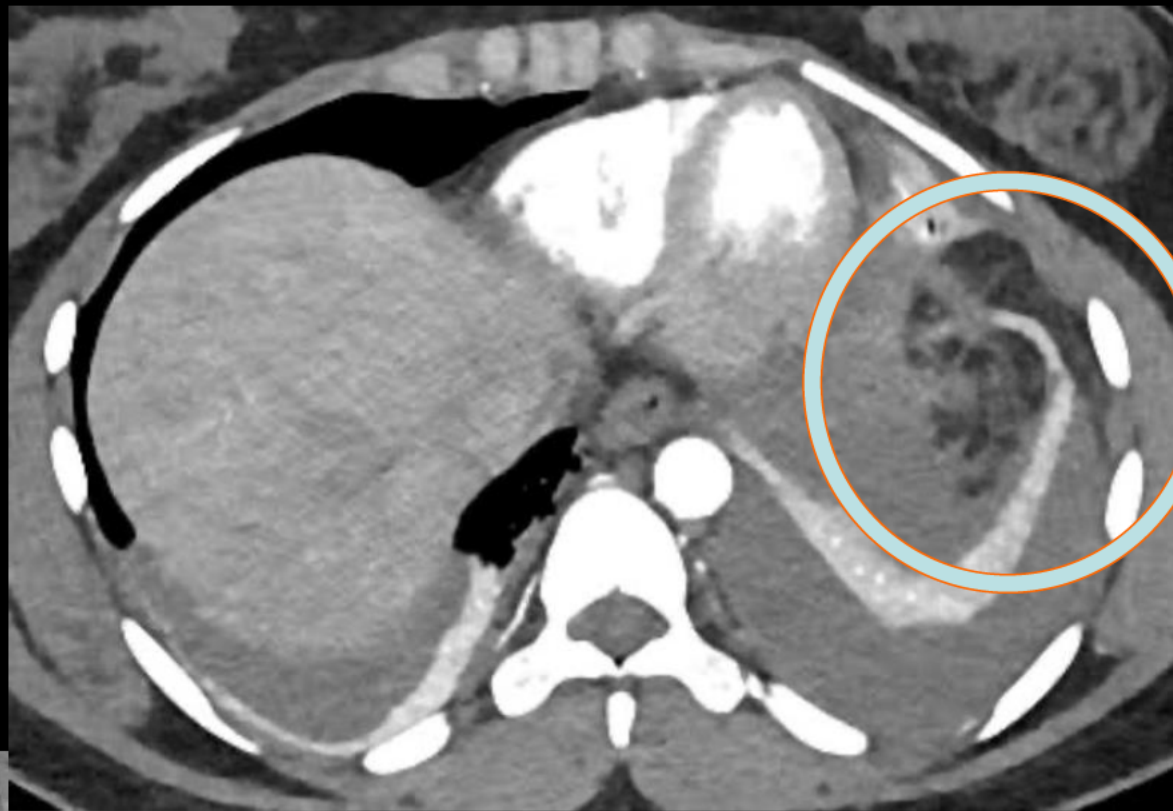




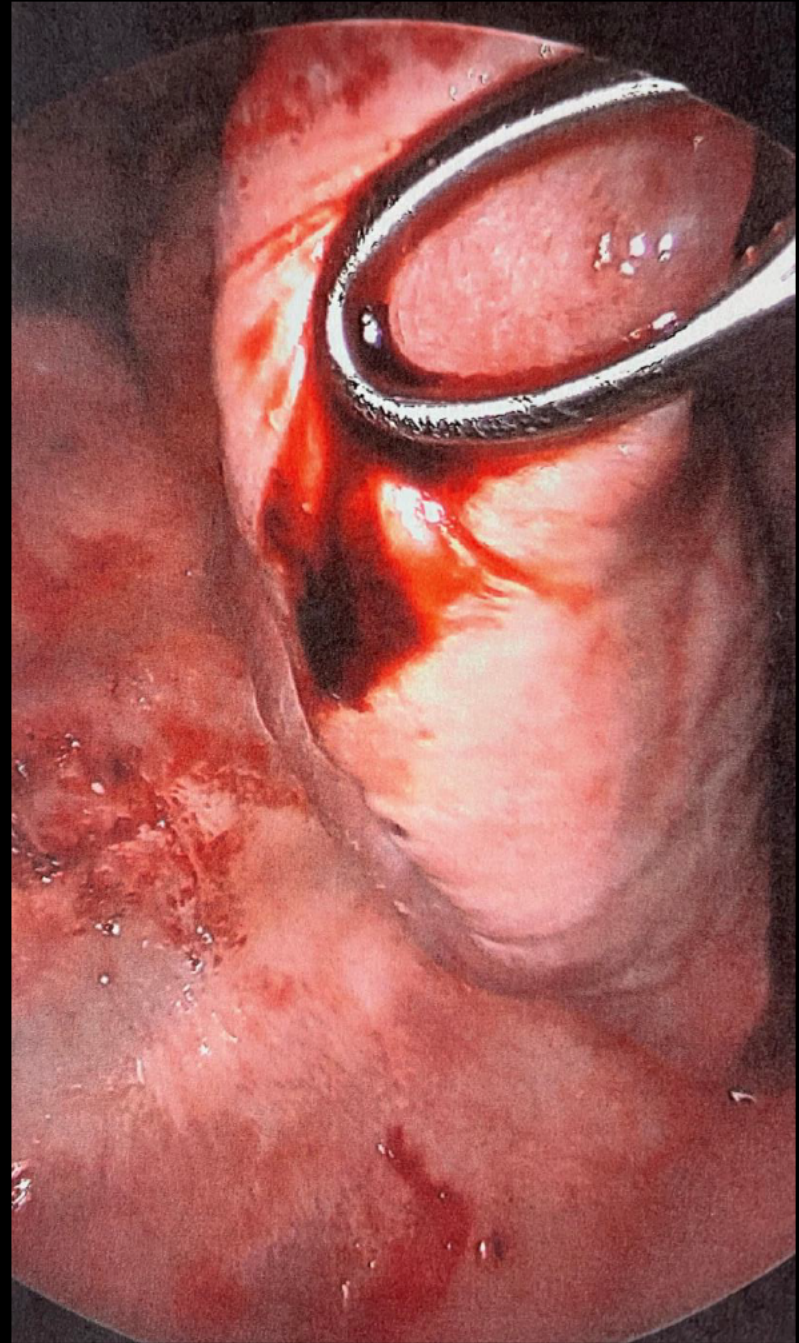


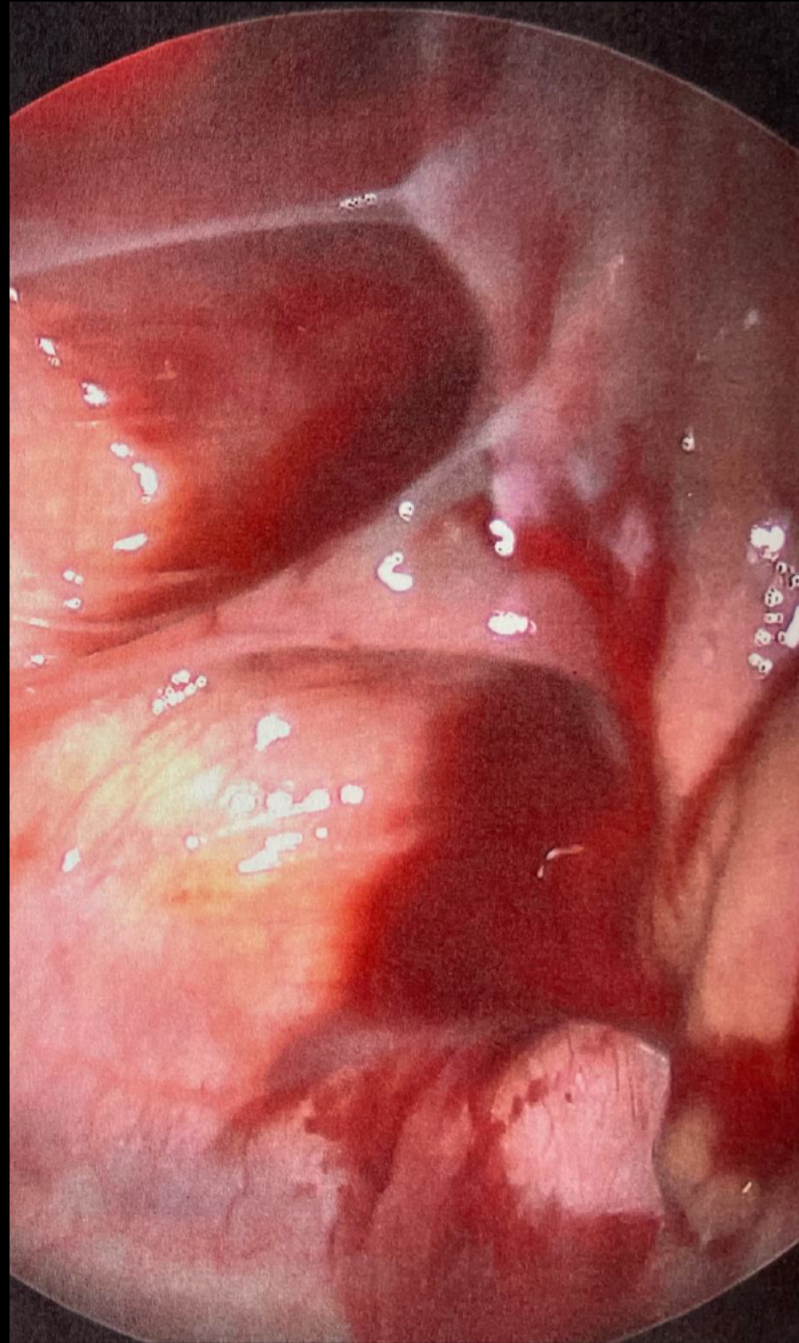
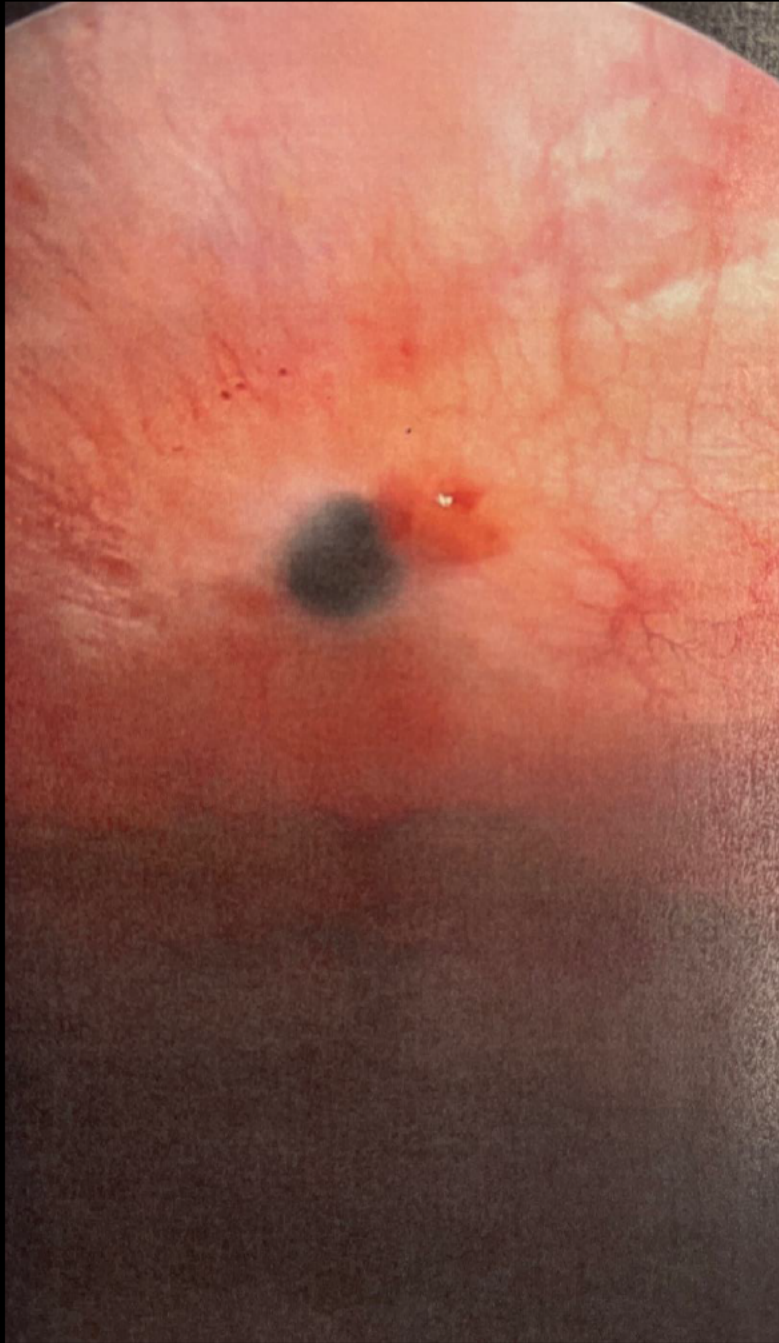




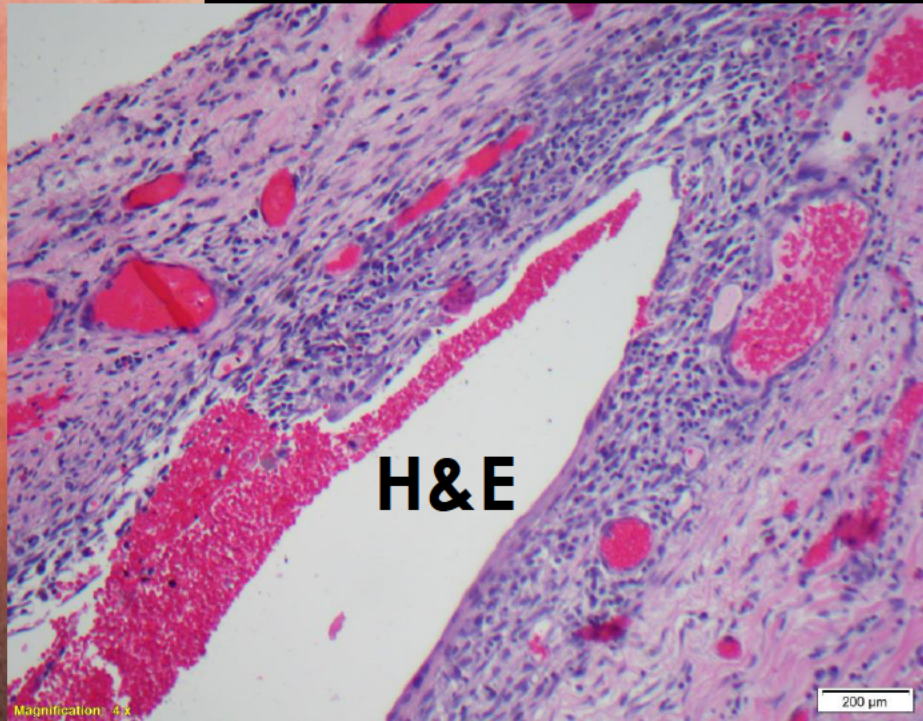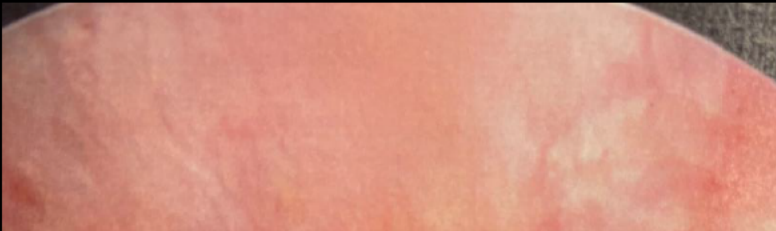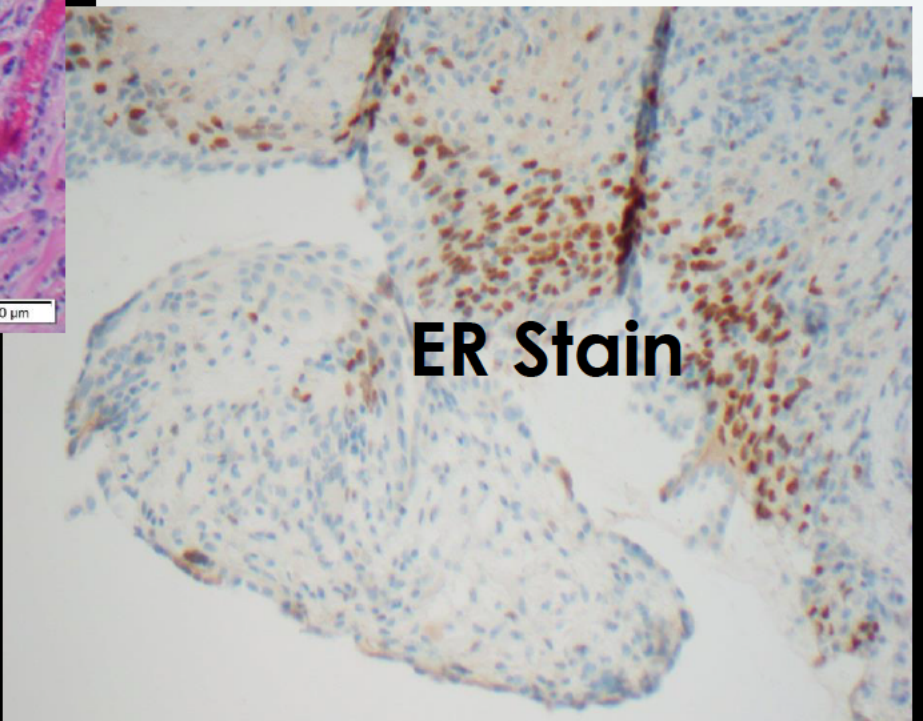
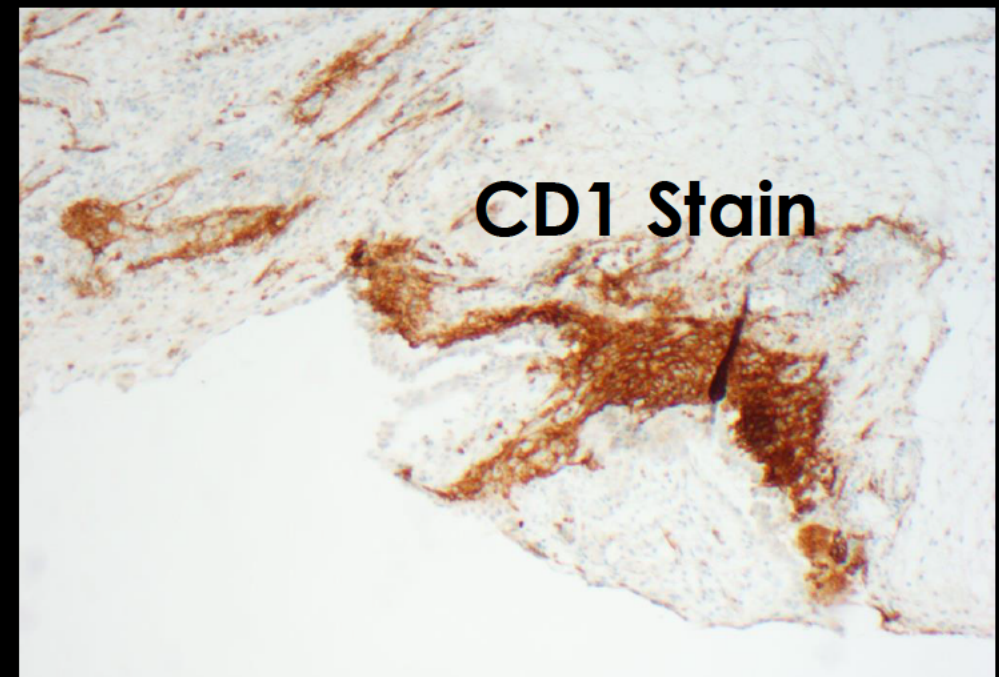






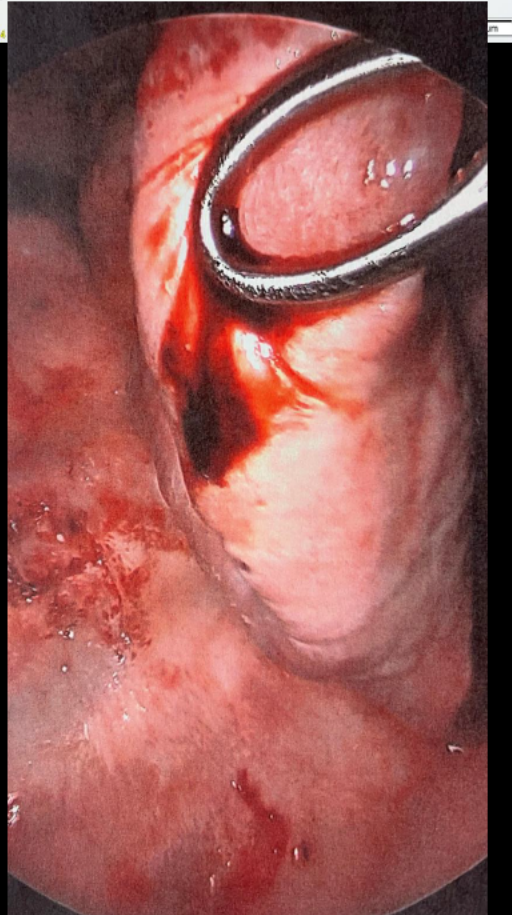
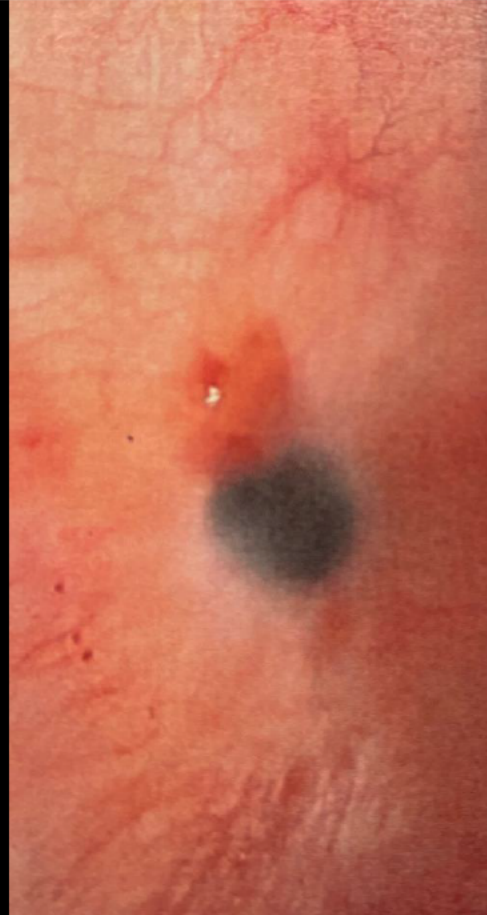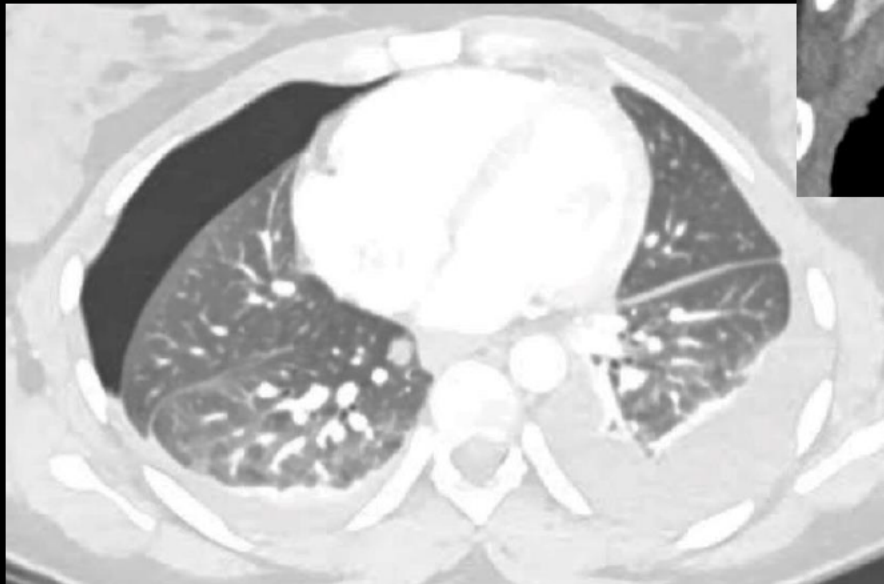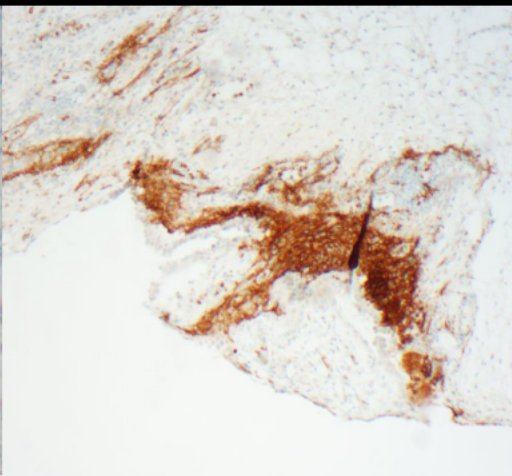
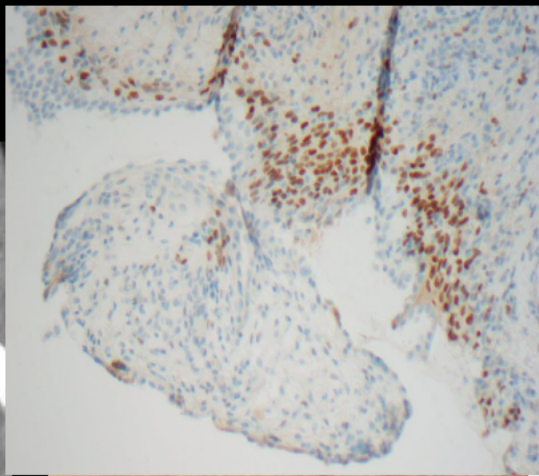


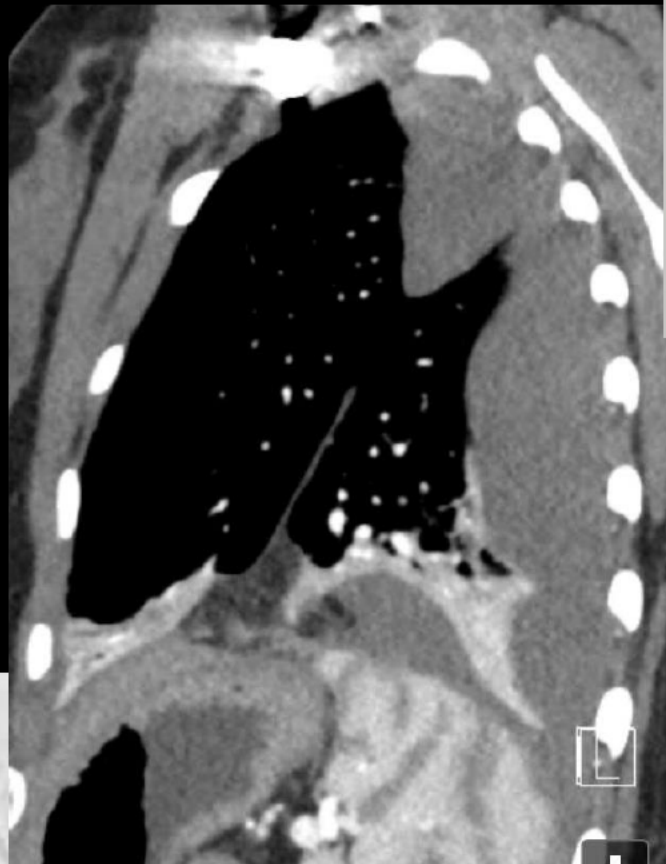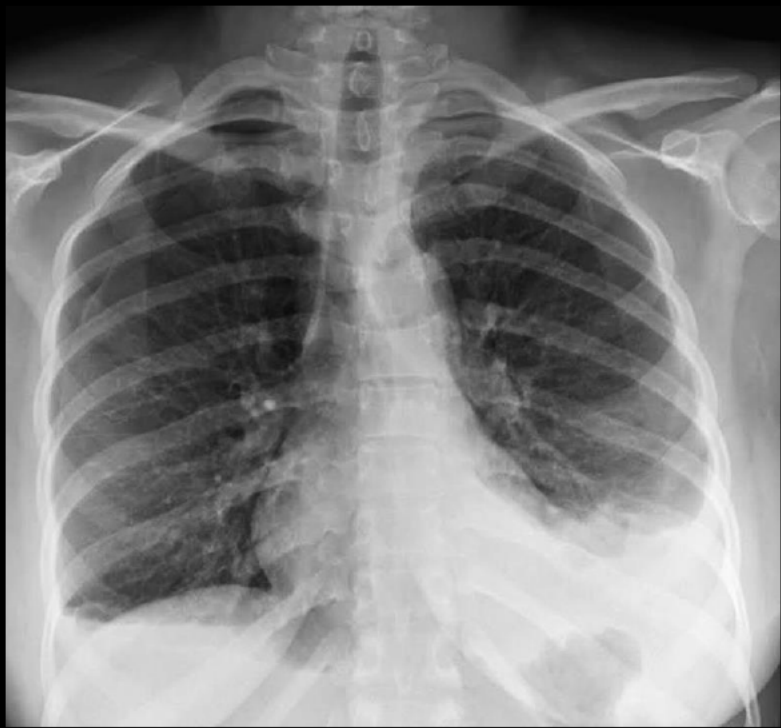Magnification: 4x



200 μm





# Catamenial Pneumothorax related to Pleural Endometriosis